



This is a digital copy of a book that was preserved for generations on library shelves before it was carefully scanned by Google as part of a project to make the world's books discoverable online.

It has survived long enough for the copyright to expire and the book to enter the public domain. A public domain book is one that was never subject to copyright or whose legal copyright term has expired. Whether a book is in the public domain may vary country to country. Public domain books are our gateways to the past, representing a wealth of history, culture and knowledge that's often difficult to discover.

Marks, notations and other marginalia present in the original volume will appear in this file - a reminder of this book's long journey from the publisher to a library and finally to you.

Usage guidelines

Google is proud to partner with libraries to digitize public domain materials and make them widely accessible. Public domain books belong to the public and we are merely their custodians. Nevertheless, this work is expensive, so in order to keep providing this resource, we have taken steps to prevent abuse by commercial parties, including placing technical restrictions on automated querying.


We also ask that you:

- + *Make non-commercial use of the files* We designed Google Book Search for use by individuals, and we request that you use these files for personal, non-commercial purposes.
- + *Refrain from automated querying* Do not send automated queries of any sort to Google's system: If you are conducting research on machine translation, optical character recognition or other areas where access to a large amount of text is helpful, please contact us. We encourage the use of public domain materials for these purposes and may be able to help.
- + *Maintain attribution* The Google "watermark" you see on each file is essential for informing people about this project and helping them find additional materials through Google Book Search. Please do not remove it.
- + *Keep it legal* Whatever your use, remember that you are responsible for ensuring that what you are doing is legal. Do not assume that just because we believe a book is in the public domain for users in the United States, that the work is also in the public domain for users in other countries. Whether a book is still in copyright varies from country to country, and we can't offer guidance on whether any specific use of any specific book is allowed. Please do not assume that a book's appearance in Google Book Search means it can be used in any manner anywhere in the world. Copyright infringement liability can be quite severe.

About Google Book Search

Google's mission is to organize the world's information and to make it universally accessible and useful. Google Book Search helps readers discover the world's books while helping authors and publishers reach new audiences. You can search through the full text of this book on the web at <http://books.google.com/>

245 017J 608J



QUIZ-COMPENDS

DISEASES OF THE EYE

GOULD & PYLE

TEXT-BOOK OF ANATOMY

A COMPLETE SYSTEMATIC TREATISE
BY VARIOUS AUTHORS

Edited by

W. H. HAYES, M.D. and W. R. GOSSETT, F.R.C.S.

LANE

MEDICAL



LIBRARY

LEVI COOPER LANE FUND

A Text-Book for Practitioners and Students

By **JAMES TYSON, M.D.**

*Professor of Medicine in the University of Pennsylvania and Physician to
the Hospital of the University, etc.*

Fourth Edition, Revised and Enlarged. With Colored Plates
and 240 Other Illustrations. Octavo; xxvii + 1305 pages.

Cloth, \$5.50; Leather or Half-Morocco, \$6.50 net

P. BLAKIST

Publishers and Booksellers
PHILADELPHIA

CLINICAL HEMATOLOGY

A PRACTICAL GUIDE TO THE EXAMINATION OF THE BLOOD
BY CLINICAL METHODS, WITH REFERENCE TO
THE DIAGNOSIS OF DISEASE

By **JOHN C. DA COSTA, Jr., M.D.**

*Demonstrator of Clinical Medicine, Jefferson Medical College; Chief of Medical
Clinic and Assistant Visiting Physician, Jefferson Medical College
Hospital; Hematologist, German Hospital, Philadelphia*

Second Edition, Revised. Enlarged by 117 pages. With 9 Full-page
Plates in Colors, representing the subjects, as closely as possible, as they
appear to the eye; 3 Charts, and 64 other Illustrations. Octavo; 591 pages.
Cloth, \$5.00 net

A Text-Book of HUMAN PHYSIOLOGY

INCLUDING HISTOLOGY AND MICROSCOPICAL ANATOMY,
WITH SPECIAL REFERENCE TO THE REQUIRE-
MENTS OF PRACTICAL MEDICINE

By **DR. L. LANDOIS**

*Professor of Physiology and Director of the Physiological Institute in the University
of Greifswald*

Tenth Edition, Revised, Enlarged. Translated and Edited by

A. P. BRUBAKER, M.D. and AUGUSTUS A. ESHNER, M.D.

*Professor of Physiology at Jefferson Professor of Clinical Medicine, Philadelphia
Medical College, Philadelphia, etc. Polyclinic, etc.*

Tenth Edition, Revised and Enlarged. With 394 Illustrations. Octavo;
1027 pages. Cloth, \$7.00; Leather, \$8.00 net

DISEASES OF THE SKIN

THEIR DESCRIPTION, PATHOLOGY, DIAGNOSIS AND TREAT-
MENT, WITH SPECIAL REFERENCE TO THE SKIN
ERUPTIONS OF CHILDREN, AND AN ANALYSIS
OF 15,000 CASES OF SKIN DISEASE

By **H. RADCLIFFE CROCKER, M.D., F.R.C.P.**

Physician for Diseases of the Skin, University College Hospital, etc.

Third Edition, Thoroughly Revised. 112 Illustrations. Octavo; 1400 pages.
Cloth, \$5.00; Sheep, \$6.00 net

P. BLAKISTON'S SON & CO., Publishers and Booksellers

1012 WALNUT STREET, PHILADELPHIA



 **BASED ON RECENT MEDICAL LITERATURE.**

Gould's Medical Dictionaries.

The Standard
Medical
Reference Books.

198,000 HAVE
BEEN SOLD.

BY **GEORGE M. GOULD, A.M., M.D.**,
Editor of *American Medicine*.

THE ILLUSTRATED DICTIONARY OF MEDICINE, BIOLOGY, AND ALLIED SCIENCES. INCLUDING THE PRONUNCIATION, ACCENTUATION, DERIVATION, AND DEFINITION OF THE TERMS USED IN MEDICINE AND THOSE SCIENCES COLLATERAL TO IT: BIOLOGY (ZOOLOGY AND BOTANY), CHEMISTRY, DENTISTRY, PHARMACOLOGY, MICROSCOPY, ETC. With many Useful Tables and numerous Fine Illustrations. Large Square Octavo. 1633 pages. Fifth Edition now ready. Full Sheep, or Half Dark-Green Leather, *net*, \$10.00; With Thumb Index, *net*, \$11.00; Half Russia, Thumb Index, *net*, \$12.00

A. DICTIONARY OF NEW MEDICAL TERMS. Being a Supplement to "Gould's Illustrated Dictionary," consisting of 571 double-column pages, containing upwards of 38,000 words, uniform in size and type with the "Illustrated" and containing many thousand new terms and new definitions. Large Square Octavo. Full Sheep or Half Dark Green Leather, \$5.00; with Thumb Index, \$6.00
Half Russia, Thumb Index, \$7.00

THE STUDENT'S MEDICAL DICTIONARY. INCLUDING ALL THE WORDS AND PHRASES GENERALLY USED IN MEDICINE, WITH THEIR PROPER PRONUNCIATION AND DEFINITIONS, BASED ON RECENT MEDICAL LITERATURE. With Tables of the Bacilli, Micrococci, Leukomains, Ptomaines, etc., of the Arteries, Muscles, Nerves, Ganglia, and Plexuses; Mineral Springs of the U. S., etc. Eleventh Edition, Illustrated. Revised, Enlarged by over 150 pages. Small Square Octavo. Half Dark Leather, *net*, \$2.50; with Thumb Index, *net*, \$3.00

THE POCKET PRONOUNCING MEDICAL LEXICON. 30,000 words pronounced and defined. Containing all the Words, their Definition and Pronunciation that the Student generally comes in contact with; also elaborate Tables of the Arteries, Muscles, Nerves, Bacilli, etc., etc.; a Dose List in both English and Metric Systems, etc., arranged in a most convenient form for reference and memorizing. Fourth Edition, 837 pages. 64mo.

Full Limp Leather, Gilt Edges, *net*, \$1.00; Thumb Index, *net*, \$1.25

P. BLAKISTON'S SON & CO., Publishers and Booksellers
1012 WALNUT STREET, PHILADELPHIA



From The Southern Clinic.

"We know of no series of books issued by any house that so fully meets our approval as these ?Quiz-Compendis?. They are well arranged, full, and concise, and are really the best line of text-books that could be found for either student or practitioner."

BLAKISTON'S ?QUIZ-COMPENDS?

The Best Series of Manuals for the Use of Students.

Price of each, Cloth, \$1.00 net. Interleaved, for taking Notes, \$1.25 net.

☞ These Compendis are based on the most popular text-books and the lectures of prominent professors, and are kept constantly revised, so that they may thoroughly represent the present state of the subjects upon which they treat.

☞ The authors have had large experience as Quiz-Masters and attachés of colleges, and are well acquainted with the wants of students.

☞ They are arranged in the most approved form, thorough and concise, containing over 900 fine illustrations, inserted wherever they could be used to advantage.

☞ Can be used by students of any college. They contain over 900 illustrations.

☞ They contain information nowhere else collected in such a condensed, practical shape.

Illustrated Circular Free.

POTTER'S ANATOMY. Seventh Revised and Enlarged Edition. Including Visceral Anatomy. Can be used with either Morris' or Gray's Anatomy. 138 Illustrations and 16 Plates of Nerves and Arteries, with Explanatory Tables, etc.

HUGHES. PRACTICE OF MEDICINE. Part I. Sixth Edition, Revised, Enlarged, and Improved.

HUGHES. PRACTICE OF MEDICINE. Part II. Sixth Edition, Revised, Enlarged, and Improved. These two books furnish a complete set of notes on the Practice of Medicine, including Nervous and Mental Diseases.

BRUBAKER. PHYSIOLOGY. Eleventh Edition, with new Illustrations and a Table of Physiological Constants. Enlarged and Revised.

LANDIS. OBSTETRICS. Seventh Edition. Revised and Edited by Wm. H. Wells, M.D., Instructor Jefferson Medical College, Philadelphia. 47 Illustrations.

POTTER. MATERIA MEDICA, THERAPEUTICS, AND PRESCRIPTION WRITING. Sixth Revised Edition.

WELLS. GYNECOLOGY. Third Edition. With many Illustrations.

GOULD and PYLE. DISEASES OF THE EYE AND REFRACTION. Including Treatment and Operations and a Section on Local Therapeutics. With Formulæ and 109 Illustrations, several of which are in Colors. Second Edition.

HORWITZ'S SURGERY, Minor Surgery, and Bandaging. Fifth Edition, Enlarged and Improved. With 98 Formulæ and 167 Illustrations.

LEFFMANN. CHEMISTRY, Inorganic and Organic. Fourth Edition. Including Urinalysis, Animal Chemistry, Chemistry of Milk, Blood, Tissues, the Secretions, etc.

STEWART. PHARMACY. Fifth Edition. Based upon Prof. Remington's Text-Book of Pharmacy.

BALLOU. VETERINARY ANATOMY AND PHYSIOLOGY. With 29 graphic Illustrations.

WARREN. DENTAL PATHOLOGY AND DENTAL MEDICINE. Fourth Edition, Illustrated. Containing all the most noteworthy points of interest to the Dental Student, and a Section on Emergencies.

HATFIELD. DISEASES OF CHILDREN. Colored Plate. Third Edition, Revised and Enlarged.

ST. CLAIR. MEDICAL LATIN. Second Edition. *In Press.*

SCHAMBERG. DISEASES OF THE SKIN. Third Edition, Revised and Enlarged. 106 Illustrations.

CUSHING. HISTOLOGY. With many Illustrations. *In Press.*

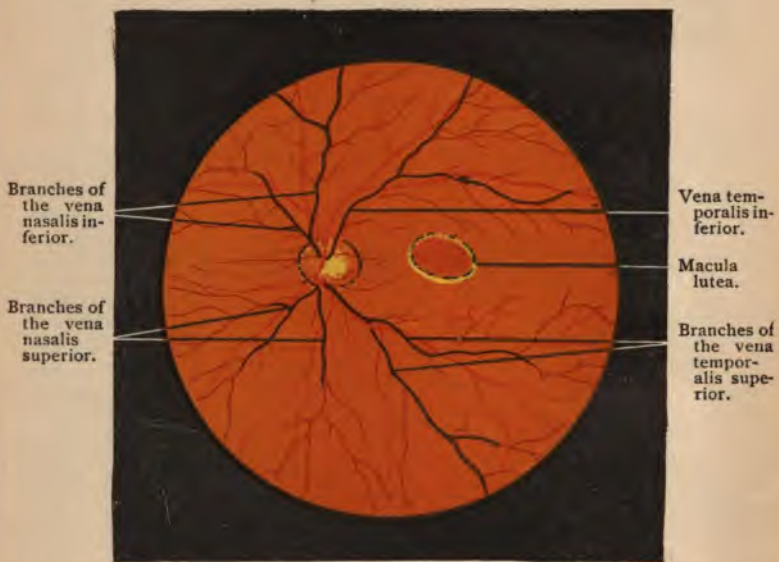THAYER. SPECIAL PATHOLOGY. With 34 Illustrations.

KYLE. EAR, NOSE, AND THROAT. 85 Illustrations.



DISEASES OF THE EYE

GOULD AND PYLE



Branches of
the vena
nasalis in-
ferior.

Branches of
the vena
nasalis
superior.

Vena tem-
poralis in-
ferior.

Macula
lutea.

Branches of
the vena
tempor-
alis supe-
rior.

THE NORMAL FUNDUS IN THE INVERTED IMAGE.—(After Jaeger.)

The choroidal ring can be distinguished along the whole circumference, the scleral ring only on the right side.

?BLAKISTON'S QUIZ-COMPENDS?

A COMPEND
OF THE
DISEASES OF THE EYE
AND
REFRACTION

INCLUDING TREATMENT AND SURGERY

BY

GEORGE M. GOULD, A. M., M. D.

EDITOR "AMERICAN MEDICINE;"

FORMERLY OPHTHALMOLOGIST TO THE PHILADELPHIA HOSPITAL, ETC.

AND

WALTER L. PYLE, A. M., M. D.,

ASSISTANT SURGEON TO WILLS EYE HOSPITAL, PHILADELPHIA; ASSOCIATE MEMBER OF THE
AMERICAN OPHTHALMOLOGICAL SOCIETY, ETC.

Third Edition, Revised and Corrected

ONE HUNDRED AND NINE ILLUSTRATIONS, SEVERAL OF WHICH
ARE IN COLORS

PHILADELPHIA
P. BLAKISTON'S SON & CO.
1012 WALNUT STREET
1904

COPYRIGHT, 1904, BY P. BLAKISTON'S SON & Co.

W

W

WM. F. FELL COMPANY
ELECTROTYPERS AND PRINTERS
PHILADELPHIA

49
69
1904

PREFACE TO THE SECOND EDITION.

Encouraged by the sale of a large edition of this compend within two years, the authors have corrected, revised, and enlarged the text as much as compatible with the necessarily limited space, until now the volume far exceeds the ordinary size and scope of a compend. Through the liberality of the publishers the whole book has been reset in larger type, and several new illustrations, including five colored plates, have been added. The section on Local Ocular Therapeutics has been increased to include all the recent mydriatics, miotics, local anesthetics, ocular antiseptics, etc. Additional emphasis has been given to points of practical value.

GEORGE M. GOULD,
WALTER L. PYLE.

PREFACE TO THE FIRST EDITION.

The object of this compend is to describe simply and concisely the most important subjects in Ophthalmology, giving the novice all the necessary preparation for an intelligent comprehension of the more exhaustive literature of this branch of Medicine. For the benefit of the general physician, to whom some elementary knowledge of Ophthalmology is imperative, especial attention has been given to the principles and practice of refraction; to muscular anomalies; to the diagnosis and differentiation of the common ocular diseases; and to local ocular therapeutics.

A table of abbreviations, a glossary, and a complete index are appended. Dr. James Thorington has kindly written the section on Retinoscopy.

GEORGE M. GOULD,
WALTER L. PYLE.

TABLE OF CONTENTS.

PART I.

	PAGE
EXAMINATION AND REFRACTION OF THE EYE,	13
GENERAL DESCRIPTION OF THE EYE,	13
ELEMENTARY OPTICS,	18
OPTICAL CONSIDERATION OF THE EYE,	27
EXAMINATION OF THE EYE,	33
Inspection,	35
Tension,	38
Ophthalmoscopy,	39
Retinoscopy,	49
Test-cards,	58
Test-lenses,	62
Prescribing and Testing Glasses,	65
Spectacles and Eye-glasses,	70
Mydriatics and Cycloplegics,	72
AMETROPIA,	74
Hyperopia,	74
Myopia,	78
Astigmatism,	84
Presbyopia,	93
Anisometropia,	95
Asthenopia,	98
AMBLYOPIA AND AMAUROSIS,	100
Amblyopia ex anopsia,	100
Hemeralopia,	100
Nyctalopia,	101
Toxic Amblyopia,	101
Traumatic Amblyopia,	101
Hysteric Simulation and Malingering,	102
Color Blindness,	103
The Field of Vision,	106
Hemianopsia,	109
OCULAR MUSCLES,	111
Anatomy,	111
Functional Anomalies,	112
Strabismus,	126
Paralysis,	128
Nystagmus,	133
Operations,	136



PART II.

	PAGE
DISEASES OF THE EYE,	139
DISEASES OF THE EYELID,	139
Anatomy,	139
Diseases of the Skin of the Lids,	139
Diseases of the Edge of the Lids,	142
Blepharitis,	142
Hordeolum,	143
Chalazion,	143
Malposition of the Lids and Lid-edges,	144
Congenital Anomalies,	152
New Growths,	153
DISEASES OF THE LACRIMAL APPARATUS,	153
Anatomy and Physiology,	153
Diseases of the Lacrimal Gland,	155
Diseases of the Lacrimal Passages,	155
DISEASES OF THE CONJUNCTIVA,	160
Anatomy,	160
Simple Conjunctivitis,	164
Purulent Conjunctivitis,	167
Follicular Conjunctivitis,	173
Trachoma,	174
Phlyctenular Conjunctivitis,	177
Pinguecula,	178
Pterygium,	178
Injuries of the Conjunctiva,	179
New Growths,	181
DISEASES OF THE CORNEA,	181
Anatomy,	181
Pannus,	183
Interstitial Keratitis,	184
Phlyctenular Keratitis,	185
Suppurative Keratitis,	187
Corneal Opacities,	190
Staphyloma,	192
Conic Cornea,	192
Tumors,	193
Injuries,	193
Operations,	195
DISEASES OF THE SCLERA,	196
Anatomy,	196
Scleritis or Episcleritis,	196
Staphyloma,	197
Wounds,	198
DISEASES OF THE IRIS AND CILIARY BODY,	199
Anatomy,	199
Inflammations of the Iris,	201
Plastic Iritis,	201

TABLE OF CONTENTS.

xi

	PAGE
Serous Iritis,	203
Suppurative Iritis,	204
Malignant Tumors,	205
Injuries,	206
Congenital Anomalies,	206
Pupillary Anomalies,	207
Mydriasis,	207
Miosis,	207
Argyll Robertson Pupil,	208
Hippus,	208
Operations,	208
Iridectomy,	208
Iridotomy,	210
Iridocystectomy,	211
Iridodesis,	211
Cyclitis,	211
Paralysis of the Ciliary Muscle,	212
Spasm of the Ciliary Muscle,	212
DISEASES OF THE CHOROID,	212
Anatomy,	212
Choroiditis,	213
Exudative,	213
Suppurative,	215
Myopic,	215
Sarcoma,	216
Rupture,	217
Detachment,	217
Coloboma,	218
DISEASES OF THE RETINA,	218
Anatomy,	218
Hyperemia,	219
Retinal Hemorrhage,	220
Retinitis,	221
Albuminuric,	221
Diabetic,	223
Leukemic,	223
Retinitis Pigmentosa,	223
Thrombosis and Embolism of the Retinal Vessels,	225
Detachment of the Retina,	225
Glioma,	227
Injuries,	228
Opaque Nerve-fibers,	228
DISEASES OF THE OPTIC NERVE,	229
Anatomy,	229
Optic Neuritis,	230
Optic Atrophy,	234
DISEASES OF THE LENS,	235
Anatomy,	235
Cataract,	236
Causes,	235

	PAGE
Cataract :	
Varieties and Nomenclature,	237
Symptoms and Diagnosis,	237
Objective Examination,	237
Treatment,	241
Operations for Cataract,	242
Discission,	243
Extraction,	244
Secondary Cataract,	247
Injuries to the Lens,	248
Congenital Anomalies,	249
DISEASES OF THE VITREOUS,	249
Anatomy and Physiology,	249
Hyalitis,	249
Muscæ Volitantes,	250
Persistent Hyaloid Artery,	250
GLAUCOMA,	251
Causes,	251
Pathologic Changes,	251
Symptoms,	252
Diagnosis,	253
Varieties,	254
Prognosis,	255
Treatment,	255
DISEASES OF THE ORBIT,	256
Anatomy,	257
Periostitis,	257
Orbital Cellulitis,	258
Injuries,	258
Tumors,	259
Exophthalmic Goiter,	259
Enophthalmos,	259
INJURIES TO THE EYEBALL,	260
Wounds,	260
Foreign Bodies,	261
Parasites,	262
Sympathetic Ophthalmia,	262
Operations on the Entire Eyeball,	264
Evisceration,	264
Total Combined Keratectomy,	265
Enucleation,	265
Artificial Eye,	266
Exenteration of the Orbital Contents,	267
LOCAL OCULAR THERAPEUTICS,	268
ABBREVIATIONS,	280
GLOSSARY,	281
INDEX,	289

A COMPEND
OF THE
DISEASES OF THE EYE
AND
REFRACTION.

PART I.
EXAMINATION AND REFRACTION OF THE
EYE.

GENERAL DESCRIPTION OF THE EYE.

The eye is the organ of vision. Impressions of light are received in the peripheral organ, the eyeball; are transmitted by the optic nerve and optic tract to the base of the brain, and thence to the cortex, and become known to us as images, through the visual centers in the occipital lobe.

The eyeball is contained in a bony cavity called the orbit, which is conic in shape, with its apex posterior. The eyeball resembles in shape a sphere, which has on its anterior surface the segment of a smaller sphere. The average diameters of the human eyeball are: 24 mm. anteroposteriorly, 23 mm. transversely, and 23 mm. vertically. The eyeball is held in place by its muscles and membranes, and is supported in the orbit in a cushion of fat. It is surrounded by a thin membranous sac, called the *capsule of Tenon* or *tunica vaginalis oculi*. The axes of the two eyeballs are parallel with each other,

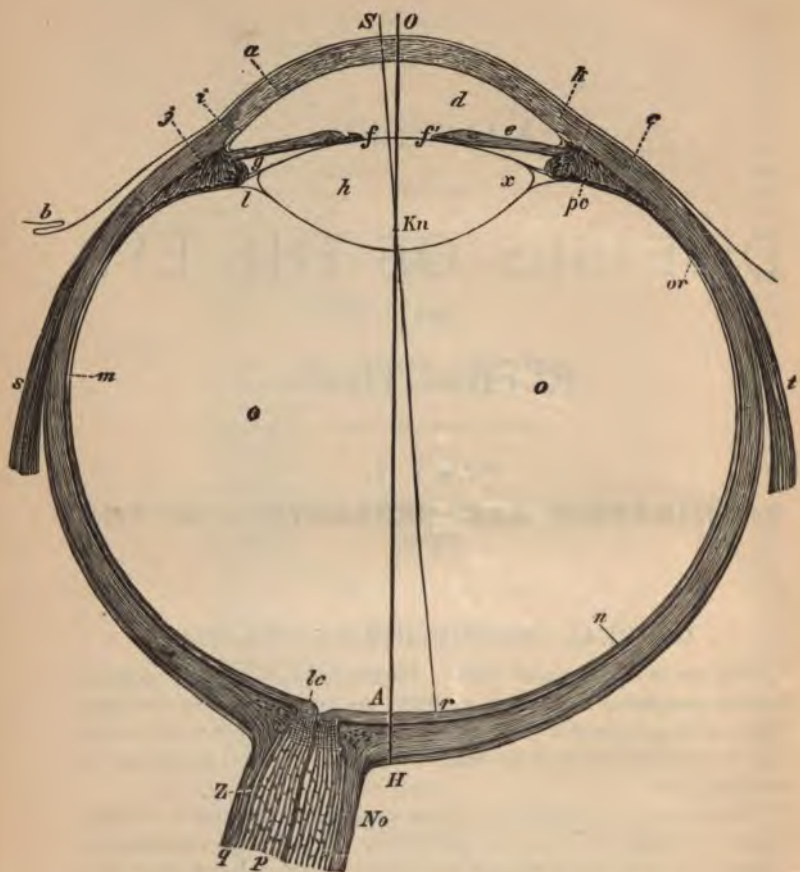


FIG. 1.—HORIZONTAL SECTION OF THE RIGHT EYE.—(Landois.)

a. Cornea. b. Conjunctiva. c. Sclerotic. d. Anterior chamber containing the aqueous humor. e. Iris. ff'. Pupil. g. Posterior chamber. l. Petit's canal. j. Ciliary muscle. k. Corneoscleral limit. i. Canal of Schlemm. m. Choroid. n. Retina. o. Vitreous humor. No. Optic nerve. q. Nerve-sheaths. p. Nerve-fibers. lc. Lamina cribrosa. h. Crystalline lens. or. Ora serrata. pc. Ciliary processes. The line, OA, indicates the optic axis; Sv, the axis of vision; r, the position of the fovea centralis.

while the axes of the orbit are divergent. The optic nerve enters the posterior portion of the eyeball through an opening called the *forus opticus*, slightly to the nasal side.

The eyeball consists of three *tunics* or outer coats, and three *refractive media* called *humors*.

The *tunics* are (1) the *sclera* and *cornea*; (2) the *choroid*, *iris*, *ciliary muscle*, and *ciliary processes*; (3) the *retina*. The *sclera* or *sclerotic coat* is a tough, fibrous covering, forming the chief protection of the eyeball. The *choroid* is the vascular coat, and is chiefly concerned in the nutrition of the eye; it and the *retina* are pigmented, and absorb all the superfluous rays that might, by reflection, confuse the retinal image. By its contractile and expansile powers, the *iris* regulates the quantity of light admitted into the pupil; ordinarily it is sufficiently pigmented to prevent the passage of light through its substance. The *retina* is the inner and most delicate layer, and contains the nervous elements. It is the percipient tunic of the eye.

The *Humors*.—The several *humors* are the *aqueous*, the *crystalline (lens)*, and the *vitreous*. The *cornea* and the *humors* are transparent. All that portion of the interior of the eyeball lying behind the lens and ciliary processes is called the *vitreous chamber*, and contains the *vitreous humor*, a transparent, jelly-like substance. The crystalline lens lies in front of the vitreous chamber. The remaining anterior portion of the cavity of the eye is called the *aqueous chamber*. The aqueous chamber is subdivided into two portions, the *anterior chamber* and the *posterior chamber*, which are in free communication through the pupil, and both contain the *aqueous humor*, a slightly saline, transparent fluid. The *anterior chamber* is an angular space, covered in front by the posterior surface of the cornea, at its angle by the *ligamentum pectinatum iridis*, and behind by the anterior surface of the iris. The *posterior chamber* is a small cavity, bounded in front by the posterior surface of the iris, and behind by the ciliary processes, the suspensory ligament of the lens, and the anterior capsule of the lens.

The nervous supply of the eyeball and its appendages is through sensory branches from the first and second divisions of the fifth pair of nerves, and motor branches from the third, fourth, sixth, and seventh pairs of cranial nerves, and sympathetic filaments from the carotid and cervical plexuses.

The vascular supply of the eye is through ophthalmic branches of

the internal carotid, and indirectly by anastomoses between its terminal branches and similar branches of the external carotid. The

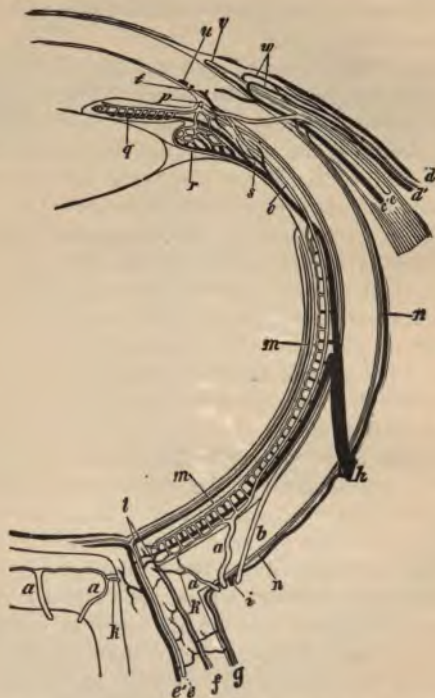


FIG. 2.—DIAGRAM OF THE BLOOD-VESSELS OF THE EYE. (Horizontal view; veins black, arteries light, with a double contour.)

a a. Short posterior ciliary. *b*. Long posterior ciliary. *c'c*. Anterior ciliary artery and vein. *d d'*. Artery and vein of the conjunctiva. *e'e*. Central artery and vein of the retina. *f*. Blood-vessels of the inner, and, *g*, of the outer, optic sheath. *h*. Vorticoses vein. *i*. Posterior short ciliary vein confined to the sclerotic. *l*. Anastomosis of the choroid vessels with those of the optic nerve. *l*. Anastomosis of the choroid vessels with those of the optic nerve. *m*. Choriocapillaris. *n*. Episcleral branches. *o*. Recurrent choroid artery. *p*. Great circular artery of the iris (transverse section). *q*. Blood-vessels of the iris. *r*. Ciliary process. *s*. Branch of a vorticoses vein from the ciliary muscle. *u*. Circular vein. *v*. Marginal loops of vessels on the cornea. *w*. Anterior artery and vein of the conjunctiva.

vessels of the globe proper are the long, the short, and the anterior ciliary arteries, and the central artery of the retina. Figure 2 is a

schematic representation of the vascular supply of the eye. The venous blood is returned from the eye through the superior and inferior ophthalmic veins, which empty into the cavernous sinus and also freely anastomose with the facial veins.

The lymph-system of the eye consists of numerous small lymph-canals, which empty into three chief lymph-spaces: the *perichoroid space*, the cavity between the choroid and the sclerotic; the *cavity of the capsule of Tenon*, between the eyeball and capsule; and the *vaginal space*, between the optic nerve and sheath. It is probable that the lymphatic spaces in the cornea communicate with the great lymph-space of the anterior chamber by means of *Schlemm's canal* and the *spaces of Fontana*. It is supposed that a stream of lymph flows from the ciliary body, diffusing through the vitreous, and from the *canal of Petit* to the posterior chamber; thence downward and forward through the anterior chamber, from whence it escapes at the angle, through the *membrane of Descemet* and the pectinate ligament, to the canal of Schlemm. Tributary streams of lymph flow into both the anterior and posterior chambers from the surrounding surfaces. It is possible that all the lymph-spaces communicate with the anterior chamber, except those of the retina, which discharge through the *porus opticus* into the vaginal space.

The muscles of the eyeball are six: the superior, inferior, internal and external recti, and the superior and inferior oblique.

The appendages of the eyeball are the eyebrows, the eyelids, the capsule of Tenon, the conjunctiva, the lacrymal apparatus, the muscles, the aponeuroses, and the vessels and nerves.

The anatomy and physiology of the individual components of the eyeball and appendages will be set forth under the separate headings.

Dissection of the Eye.—It is somewhat difficult to obtain human eyes, and for practical dissection fresh bullocks' eyes in which the corneæ are still clear may be used, while for practising operations pigs' eyes are to be preferred. If the eyes can not be used during the day on which they are obtained, they may be preserved in 1 : 1000 solution of formaldehyd. For dissection the eye should be held firmly in the left hand, and the sclera incised at the equator of the globe by repeated cuts until the black choroid is seen, and systematic examination of the different parts of the interior of the eye should be carefully made, following the plans laid down by the best anatomies. Cross-sections of frozen eyes are very valuable to study the

relative position of the different parts, which is disturbed in ordinary dissection.

For practising operations several masks are on the market, and that consisting of a phantom face with an orbital clip for holding the eye in a proper position is to be preferred. Operations on the ocular muscles should be studied on the human cadaver, or on the rabbit, cat, or dog.

ELEMENTARY OPTICS.

Rays of light diverge from a luminous point in a straight line in every direction and in every plane. At six meters the divergence of the rays is so slight that for practical purposes we may consider rays from a point at such a distance as parallel.

Light travels through space at a speed of about 186,680 miles a second, but in the air or other transparent medium of a known density the rate of speed diminishes, generally with the density of the media traversed.

The Action of Opaque Substances on Rays of Light.—When a ray of light meets an opaque body it is either absorbed or reflected.*

Reflection.—The condition first requiring our attention is reflection from highly polished plane, concave, or convex surfaces, or, generally speaking, mirrors. Rays of light from a luminous point striking the mirror are called *incident rays*; rays leaving the mirror are called *reflected rays*.

Reflection by a plane surface gives an erect image, and the angle of reflection is equal to the angle of incidence. The reflected and incident rays are both in a plane perpendicular to the reflecting surface. The image is formed at a distance behind the reflecting surface equal to the distance of the luminous point in front of it, and is called a *virtual image*, in contradistinction to a *real image* which is formed directly by the reflected rays, and not by their prolongation. If a plane mirror be rotated on any axis in its own plane, the virtual image moves in an opposite direction to the mirror.

* Since Prof. Röntgen's discovery we know that certain cathodal rays have the power of penetrating substances apparently opaque to ordinary rays of light, and it is possible that penetration takes place often in a degree unappreciable to the human eye. The term "opacity" is therefore used relatively.

Reflection by a concave surface may be considered as reflection from a number of plane surfaces inclined toward one another. Parallel rays falling on a concave surface are reflected as convergent rays which meet at a point on the axis of the surface inside the center of concavity, called the *principal focus* (Fig. 3, F). The distance

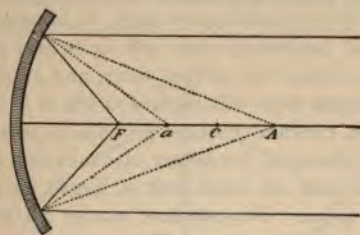


FIG. 3.

of the principal focus from the mirror is called the *focal length* of the mirror.

The formation of the image varies with the distance of the light from the mirror. If the light be placed at the principal focus, F , the reflected rays leave the mirror parallel with each other and the axis

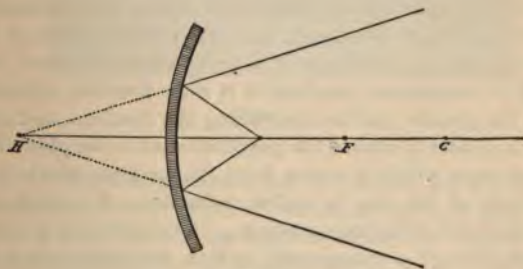


FIG. 4.

of the mirror. If the light be placed at the center of concavity, C , the reflected rays return along the same line. If at a point beyond the center, A , the reflected rays focus between the center and the principal focus, a ; and, vice versa, if the luminous point be situated between the principal focus and the center of concavity, the reflected

rays focus at a point beyond the center; and the nearer the point is to the center, the greater the distance at which the reflected rays focus. The points A and a are mutually convertible; *i. e.*, either may be taken as the point of emanation of the rays, or, conversely, as the point of collection, and hence are called *conjugate foci*. If the light be placed nearer the mirror than the principal focus, the reflected rays will diverge and never meet; if, however, the divergent rays are continued backward, they will unite at a point, H , behind the mirror (Fig. 4), called the *virtual focus*, and an observer situated in the path of reflected rays will receive them as if they came from this point. Hence, concave mirrors produce a small inverted real image of an object beyond the center of concavity, no image of an object at the focus, and an erect and a larger virtual image of an object inside the focus. If a concave mirror be rotated, the real inverted aerial image of the object will move in the same direction as the rotation of the mirror.

Reflection by a convex surface produces a negative image at a point back of the surface called the *principal focus*, as parallel rays falling on a convex surface diverge and never meet. Whatever the position of the object before a convex mirror, the image is always virtual, erect, and smaller than the object.

The Action of Transparent Substances on Light.—A ray of light traversing a homogeneous substance like ether passes through undisturbed and in straight lines, and, as already stated, when it is intercepted by an opaque substance it is reflected or absorbed; but if it meets with a transparent medium it is only partially reflected and absorbed, the greater portion traversing the medium, and during its passage it is deflected toward the perpendicular to the plane dividing the medium from which it comes from the medium which it enters. This bending of the ray is called *refraction*; the medium traversed is called the *refracting medium*. In considering the transmission of light through a transparent surface, the infinitesimal amount reflected and absorbed is disregarded, and only that refracted is considered.

Refraction by a Plane Surface.—Rays of light perpendicular to the surface separating the two media are not refracted, but continue in a straight line. In figure 5 the ray CO , perpendicular to the surface AB , is not refracted, but continues its course in the straight line OC .

As a ray passes from a rare into a denser medium it is refracted toward the perpendicular. In figure 5, if the incident ray EO passes from air into water, then, instead of proceeding in a direct line to F , it is bent toward the perpendicular CC' , and takes the direction OW . Were the refractive media glass,—a denser substance,—the refraction would be still greater and the ray would take the direction OG . Were the medium still denser,—as, for instance, diamond,—the ray would take the course indicated by OD . Upon emergence from the

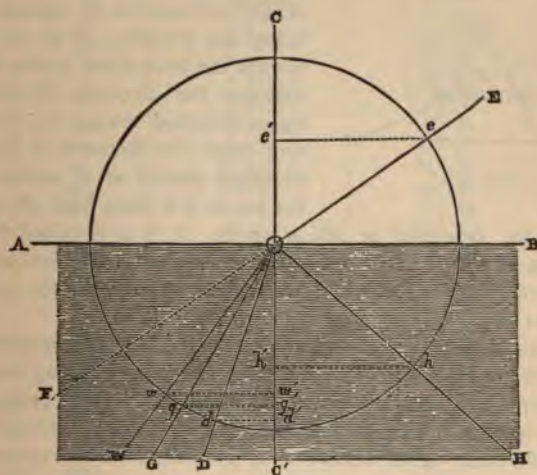


FIG. 5.

denser to the rare medium again the ray pursues its original course in a line parallel, but not identical, with its initial direction.

The sine ($e e'$) of EOC , the angle of incidence, bears a constant ratio to the sines ($w w'$, $g g'$, $d d'$) of the angles of refraction, WOC' , GOC' , DOC' ; and this ratio is called the index of refraction. Taking air as a standard, its index of refraction is called 1.00, and the refractive indices of the other substances are based on this standard. According to Krause, the refractive index of water is 1.3342; of the cornea, 1.3507; of the aqueous, 1.3420; of the vitreous, 1.3485; of the crystalline lens, 1.4541. The index of refraction of ordinary

spectacle glass is 1.53. The diamond has the highest refractive power of any transparent substance, its index of refraction being from 2.4 to 2.5+. The refractive power of a substance is not always in proportion to its density.

Refraction by Prisms.—If the two sides of a refracting medium are not parallel, as in a prism, the refracted rays do not emerge in a direction parallel to the incident course, but are bent toward the base of the prism, both at the incident and emergent surfaces. In figure 6,

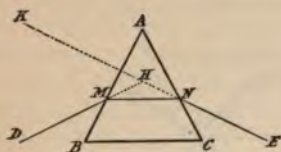


FIG. 6.

the ray DM falling on the prism ABC at the point M , instead of pursuing the direction of MH , is bent toward the base of the prism BC and assumes the direction MN . It is again deflected toward the base at N and takes the direction NE , and an observer placed at E would receive the ray as if it came from K . BAC

is called the *principal* or *apical angle*. KHD is called the *angle of deviation*, and is about one-half the size of the principal angle.

The strength of a prism is expressed in three ways: the *refracting angle*, the *prism-diopter*, and the *centrad*.

The prism-diopter was suggested with the idea of conforming the numeration of prisms to the dioptric system of numbering lenses. A prism-diopter is that prism which has the power to deflect rays of light passing through it and to a distance of one meter beyond, exactly one centimeter. This deflection is measured on the tangent. In this system the higher prisms are not simple multiples of the lower ones,—as, for instance, 20 prisms of two prism-diopters each equal a prism of 42 prism-diopters, and not 40 as would be the natural inference.

The centrad is based on the same principle, but the amount of deflection is measured on the arc at a meter distance instead of on the tangent. This method has been recommended by the American Ophthalmological Society. In the ordinary low number prisms the difference in the numeration is so slight as to cause no inconvenience.

Refraction by a Spheric Surface.—Parallel rays passing through a spheric surface separating media of different densities are refracted so that they meet at a point on the principal axis, called the *principal*

TABLE SHOWING THE EQUIVALENCE OF CENTRADS IN PRISM-DIOPTERS
AND IN DEGREES OF THE REFRACTING ANGLE (INDEX OF
REFRACTION 1.54).

CENTRADS.	PRISM-DIOPTERS.	REFRACTING ANGLE.
1.	1.	1° 00
2.	2.0001	2° 12
3.	3.0013	3° 18
4.	4.0028	4° 23
5.	5.0045	5° 28
6.	6.0063	6° 32
7.	7.0115	7° 35
8.	8.0172	8° 38
9.	9.0244	9° 39
10.	10.033	10° 39
11.	11.044	11° 37
12.	12.057	12° 34
13.	13.074	13° 29
14.	14.092	14° 23
15.	15.114	15° 16
16.	16.138	16° 08
17.	17.164	16° 98
18.	18.196	17° 85
19.	19.230	18° 68
20.	20.270	19° 45
25.	25.55	23° 43
30.	30.934	26° 81
35.	36.50	29° 72
40.	42.28	32° 18
45.	48.30	34° 20
50.	54.514	35° 94
60.	68.43	38° 31
70.	84.22	39° 73
80.	102.96	40° 29
90.	126.01	40° 49

focus. Divergent rays proceeding from a point at a distance from the lens greater than its principal focus meet at a point on the principal axis beyond the principal focus. Divergent rays proceeding from a point nearer its surface than its principal focus will still diverge, and hence never meet; but if continued backward they would meet at the *negative conjugate focus* of the initial point of divergence.

Refraction by Lenses.—A lens is a transparent refracting medium, usually of glass or crystal, which is bounded by two curved surfaces or a curved surface and a plane surface.

Lenses may be considered as a juxtaposition of prisms with different refracting angles (Fig. 7). Convex lenses are equivalent to prisms with their bases placed together, *A*; and concave lenses, to prisms with their apexes placed together, *B*. Therefore, rays of light always being deflected toward the base of a prism will be rendered *convergent* by *convex lenses*, in which the prismatic bases are central; and will be rendered *divergent* by *concave lenses*, in which the prismatic bases are peripheral.

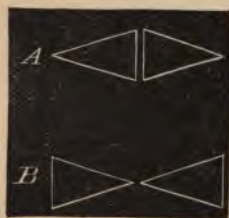


FIG. 7.

Spheric lenses are used in ophthalmology in six different forms (Fig. 8):

1. *Planoconvex*, the segment of one sphere, having a plane surface on one side and a convex surface on the reverse side.
2. *Biconvex*, segments of two spheres having two convex surfaces.
3. *Concavoconvex*, or converging meniscus.
4. *Biconcave*, having two concave surfaces.

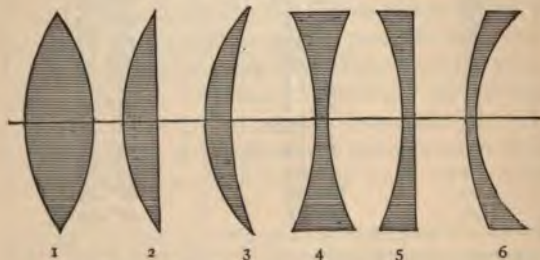


FIG. 8.—DIFFERENT FORMS OF SPHERIC LENSES.

1. Biconvex lens. 2. Planoconvex lens. 3. Concavoconvex, or converging meniscus.
4. Biconcave. 5. Planoconcave. 6. Convexoconcave, or diverging meniscus.

5. *Planoconcave*, having on one side a plane surface and on the reverse side a concave surface.

6. *Convexoconcave*, or diverging meniscus.

Numbers 3 and 6, having opposite sides at different surfaces, are called *periscopic* or *meniscus lenses*, and are used to avoid spheric aberration and to gain a greater field of clear vision.

The *principal axis* of a lens is a line passing through the optic center, at right angles to the surfaces of the lens. Rays passing through this axis are not refracted. Rays passing through the optic center of a lens, but not passing through the principal axis, are slightly deviated, although in practical optics they may be considered as straight lines. The *focal length* of a lens is the distance from the lens to the point at which parallel rays, refracted by the lens, focus.

A cylindrical lens is a lens with a plane surface in one axis, and a convex or a concave surface in the axis at right angles to it. This form of lens is really a segment of a cylinder. Examination of any cylinder—as, for instance, a bottle—will show there is curvature only in one direction, from side to side, and not in the axis. As the axis of a cylinder has a plane surface, the rays are only refracted at right angles to the axis, and the strength of the cylinder depends on the curvature possessed by the surface at right angles to the axis. The axes of the cylinders in a test case are usually shown by grinding and making partially opaque portions of each side of the lens in the direction of the axis.

It must be remembered that a cylinder refracts rays of light only in the meridian at right angles to its axis, while a spheric lens refracts rays of light in every meridian.

Classification and Numbering of Lenses.—Lenses are numbered according to their focal distance, and the strength of the lens varies inversely as its focal distance. Formerly lenses were numbered according to the inch system, the unit of which was a lens whose focal distance equaled one inch,—a very strong lens. This system necessitated the use of large numbers or fractions; and, moreover, the denomination inch had different significations in different countries, the French inch, for example, varying from the English inch. The metric or dioptric system of numbering lenses is now in use, and the unit is a lens having a focal distance of one meter, and is called a lens of *one diopter* strength—a comparatively weak lens; a two-diopter lens is one having half the focal length of the one-diopter lens, or $\frac{1}{2}$ of a meter. Decimals, of course, are used instead of fractions; a lens of a focal length of four meters is called an 0.25-diopter lens.

Convex lenses form real images, and are called *positive or plus lenses*, and are designated by the sign +.

Concave lenses produce only virtual images, and are called *negative or minus lenses*, and are designated by the sign —.

To convert a prescription written in the old system of numbering lenses into the modern metric system of diopters, we may roughly consider the meter as equivalent to 40 inches. A 10-inch lens would be equivalent to a lens having a focal length of $\frac{1}{4}$ of a meter, or four diopters. The following table from Landolt gives the equivalents in both the old and new systems.

OLD SYSTEM.				NEW SYSTEM.			
I.	II.	III.	IV.	V.	VI.	VII.	VIII.
No. of the Lens, Old System.	Focal Distance in English inches.	Focal Distance in Millimeters.	Equivalent in Diopters.	No. of the Lens, New System.	Focal Distance in Millimeters.	Focal Distance in English inches.	No. corresponding of the Old System.
72	67.9	1724	0.58	0.25	4000	157.48	166.94
60	56.6	1437	0.695	0.5	2000	78.74	83.46
48	45.3	1150	0.87	0.75	1333	52.5	55.63
42	39.6	1005	0.99	1	1000	39.37	41.73
36	34	863	1.16	1.25	800	31.5	33.39
30	28.3	718	1.39	1.5	666	26.22	27.79
24	22.6	574	1.74	1.75	571	22.48	23.83
20	18.8	477	2.09	2	500	19.69	20.87
18	17	431	2.31	2.25	444	17.48	18.53
16	15	381	2.6	2.5	400	15.75	16.69
15	14.1	358	2.79	3	333	13.17	13.9
14	13.2	335	2.98	3.5	286	11.26	11.94
13	12.2	312	3.20	4	250	9.84	10.43
12	11.2	287	3.48	4.5	222	8.74	9.26
11	10.3	261	3.82	5	200	7.87	8.35
10	9.4	239	4.18	5.5	182	7.16	7.6
9	8.5	216	4.63	6	166	6.54	6.93
8	7.5	190	5.25	7	143	5.63	5.97
7	6.6	167	5.96	8	125	4.92	5.22
6½	6.13	155	6.42	9	111	4.37	4.63
6	5.6	142	7.0	10	100	3.94	4.17
5½	5.2	132	7.57	11	91	3.58	3.8
5	4.7	119	8.4	12	83	3.27	3.46
4½	4.2	106	9.4	13	77	3.03	3.21
4	3.8	96	10.4	14	71	2.8	2.96
3½	3.3	84	11.9	15	67	2.64	2.8
3¼	3.1	79	12.7	16	62	2.44	2.59
3	2.8	71	14.0	17	59	2.32	2.46
2¾	2.6	66	15.1	18	55	2.17	2.29
2½	2.36	60	17.7	20	50	1.97	2.09
2¼	2.1	53	18.7				
2	1.88	48	20.94				

Varieties of Lenses used to Correct Refractive Errors :

1. The *simple sphere* may be either convex or concave, and is used to correct the uncomplicated forms of refractive errors.

2. The *simple cylinder* is limited in refractive power to the direction of its curvature, and is used in cases of simple astigmatism, in which there is an error of refraction in only one meridian of the eye.

3. The *spherocylinder* is a combination of a sphere with a cylinder, and is used in cases of compound or mixed astigmatism in which there is a different refractive error in the two principal meridians of the eye.

4. The *cross-cylinder* is a form of lens made up of two cylinders with their axes at right angles to each other. It is seldom prescribed, but is occasionally used in making tests.

OPTICAL CONSIDERATION OF THE EYE.

Optically considered, the eyeball is a refracting instrument designed to produce small and inverted objects upon the retina at the macular region. The impression received on the layer of rods and cones is conveyed to the visual centers in the brain, and the sense of sight results. Although the retinal images of external objects are inverted, the objects are seen in their proper positions, because all external sensations are referred outward along the lines of impact. The eyeball only receives the rays of light ; the act of vision is performed in the higher centers.

The **refracting surfaces** of the eyeball are the cornea, the anterior and posterior surfaces of the lens. The **refracting media** are the aqueous, the substance of the lens, and the vitreous.

The **Cardinal Points**.—Although it is possible geometrically to follow rays of light through the ocular media, this procedure is very difficult, and separate calculation is necessitated for each distance for the determination of the size of the image. By assuming certain ideal or cardinal points, to which such a complicated system of refracting media may be reduced, and learning their relative position and properties, we may determine, either by calculation or geometric construction, the path of the refracted ray and the position and size of the retinal image.

Gauss has demonstrated that every dioptric system may be replaced

by a single system composed of six cardinal points and six planes perpendicular to the common axis at these points.

The cardinal points of the eyeball are the *two principal points*, the *two nodal points*, and the *two principal foci*. These points are all situated on the optic axis. (Fig. 9.) The planes are the *two principal planes*, the *two focal planes*, and the *two nodal planes*.

The principal points may be defined as two points situated on the optic axis, or the line connecting the centers of curvature of the various refracting surfaces of a compound dioptric system, and so related that the final emergent ray bears the same relation to the *second* (or *posterior*) *principal point* that the initial or incident ray would

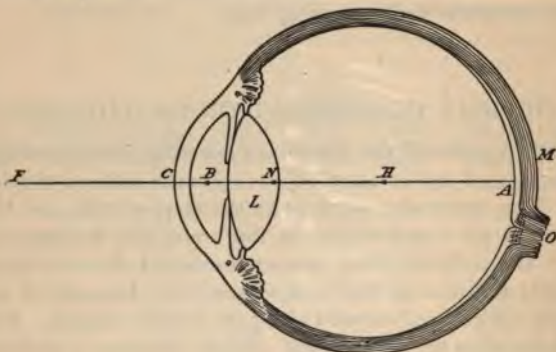


FIG. 9.

bear to the *first* (or *anterior*) *principal point*, after having undergone refraction through a single refracting surface of determinate curvature. In the eyeball, these two points are so closely situated that they may be considered as one point, *B*, about two mm. behind the cornea.

The nodal points may be defined as two points on the optic axis of a dioptric system, and so related that every incident ray which is directed toward the *first nodal point* is represented after refraction by a ray emanating from the *second nodal point*, and having a direction parallel to that of the incident ray. The nodal points of the eyeball are so close together that they may be considered as one point, which nearly corresponds to the optic center. They are situated near the posterior pole of the lens, about seven mm. behind the cornea (*N*).

The center of rotation of the eyeball is located at H in the vitreous, 9.8 mm. in front of the retina.

The first principal focus is a point on the axis at which rays parallel in the vitreous meet, F . It is situated about 13.7 mm. in front of the cornea.

The second principal focus is that point on the axis at which parallel rays meet after being refracted by the dioptric system of the eye; that is, on the rods and cones of the macular region, A . It is usually about 22.8 mm. behind the cornea, in the emmetropic eye.

The following are quoted as the mean dimensions of careful ophthalmometric measurements of many eyes :

	<i>Millimeters.</i>
Radius of curvature of cornea,	7.829
Radius of curvature of anterior surface of lens, the ciliary muscle being relaxed,	10.
Radius of curvature of posterior surface of lens,	6.
Distance from summit of cornea to anterior pole of lens,	3.6
Thickness of crystalline lens,	3.6

Taking the above dimensions, with Helmholtz's later index for the crystalline lens (1.4371), calculation gives for the schematic eye the following distances :

	<i>Millimeters.</i>
Summit of cornea to first principal point,	1.7532
Summit of cornea to second principal point,	2.1101
Summit of cornea to first nodal point,	6.9685
Summit of cornea to second nodal point,	7.3254
Distance between the principal planes equal the distance between the nodal points,	0.3569
First nodal point in front of posterior pole of lens,	0.2315
Second nodal point behind posterior pole of lens,	0.1254
Anterior focal distance (measured from the first principal plane),	15.4983
Posterior focal distance (measured from second principal plane),	20.7136
Anterior focus in front of summit of cornea,	13.7451
Posterior focus behind summit of cornea,	22.8327
Posterior nodal point to posterior focus,	15.4983

The size of the retinal image may be calculated from the size of the object and its distance from the nodal point. Multiply the size of

the object by the distance of the nodal point from the retina (approximately 15 mm.); divide the product by the distance of the object from the nodal point, and the quotient will be the size of the retinal image. All measurements must be reduced to millimeters, so that the result will be in millimeters. Suppose the eye nearly emmetropic, and the size of the object five mm., and its distance from the nodal point—*i. e.*, its distance from the cornea, *plus* seven mm., the approximate distance of the nodal point from the cornea—1000 mm. Then, $5 \times 15 = 75$; $75 \div 1000 = .075$ mm., the size of the retinal image.

The first requisite of perfect vision is that all rays proceeding from a distant object and entering the eye at rest must pass through the refractive media and be united exactly on the retina. An eye in which the refracting surfaces (namely, the anterior surface of the cornea and the anterior and posterior surfaces of the lens) and the intraocular media (namely, the aqueous, crystalline, and vitreous humors) fulfil this condition is normal, and is called *emmetropic*, and in such an eye distinct, reduced, inverted images are formed on the retina. Any fault in the *dioptric system* of the eye causes a blurring of the image by the formation of circles of dispersion or diffusion.

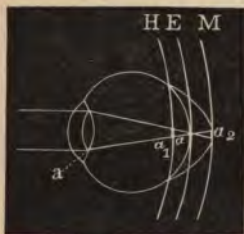

FIG. 10.

An eye which has not the power accurately to unite all rays passing from an object on the retina is called an *ametropic* eye, and the condition is called *ametropia*. The three principal forms of *ametropia* are hyperopia, myopia, and astigmatism.

Hyperopia is a condition in which the eyeball is too short or the refracting media too weak, and the rays of light focus behind the retina. In the schematic diagram (Fig. 10), E represents the posterior receptive surface of the emmetropic eye, and the rays of light are focused at *a*, a point exactly on the retina. In H, the hyperopic eye, the rays are focused behind the retina, and a blurred image is formed in front of the focus at *a*₁.

Myopia is a condition in which the eyeball is too long or the refracting media too powerful, and the retina is behind the focus

(M, Fig. 10). In such condition a blurred image is formed at a_2 , behind the focus.

Astigmatism is a condition in which the retina may be either in front of or behind the focus, or both, but by different amounts for two or more meridians of the eye.

ACCOMMODATION.

As has already been said, rays coming from a distant object—that is, beyond six meters—may be considered, for practical purposes, as parallel, and the normal eye at rest gives them such convergence that they are brought to an exact focus on the layer of rods and cones of the retina. Rays from any given point of a nearer object approach the eye with a divergence so considerable that they can not be focused on the retina by the simple refractive properties of the dioptric system of a normal eye. However, to obviate this difficulty the eye has the faculty of increasing its refractive power in order to give increased convergence to the rays coming from a near object, and this change in the eye is called accommodation.

The Mechanism of Accommodation.—Optically considered, the extra divergence might be neutralized in two ways: by displacement of the retina backward, or by a shortening of the focal distance of the dioptric apparatus of the eye. Investigations have proved that accommodation is effected through the dioptric apparatus, the increased refractive power being due to a change of the curvature of the refractive surfaces of the lens. It is commonly believed that this is effected in the following manner: The ciliary muscle contracts, thus relaxing the suspensory ligament of the lens, allowing the inherent elasticity of the lens to act and push forward the anterior surface, which, by becoming more convex, increases its refractive power. The posterior surface of the lens scarcely alters in shape. This view is not accepted by Tscherning, who maintains that the ciliary muscle in contracting increases the tension of the suspensory ligament, and thus induces bulging of the lens anteriorly outward, and hardly at all toward the periphery. However, all theorists believe that ciliary contraction is the important factor in accommodation, although they differ as to how it acts. Associated with the act of accommodation is a simultaneous contraction of the pupil. The elastic power of the lens is due to a peculiar watch-spring arrangement of its fibers.

Figure 11 represents the condition of the eye at rest and during accommodation.

The Far and Near Points.—When the ciliary muscle is entirely relaxed and the eye is completely at rest, distant objects are received at an accurate focus on the retina, and the eye is said to be adapted for its *far point*, or *punctum remotum*. When, however, the ciliary muscle has contracted to its fullest extent, the lens becomes convex to its greatest degree, and the nearest point from which rays may diverge and yet focus on the retina is called the *near point*, or *punctum proximum*. This is found by directing the patient to look at some fine print of a definite measurement, and bringing it slowly closer and closer to the eye until it becomes blurred and illegible, and noting the distance from the eye of the point where the print is still

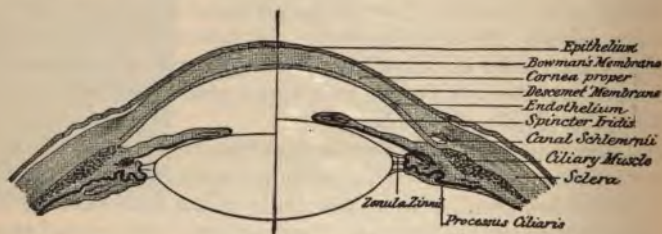


FIG. 11.

The left half represents the eye at rest; the right, during accommodation.

distinct. The print may be brought up close to the eye, and carried slowly away until it is first legible; the distance of this point from the eye gives an equally accurate result.

The distance between the far and near points is called the *range* or *amplitude of accommodation*. This range is dependent on the elasticity of the lens and lessens with advancing age, until about seventy or seventy-five years, when it becomes nil and the eye is incapable of adjusting itself for objects nearer than infinity. The range of accommodation is usually expressed in diopeters, and is represented by that convex lens which, placed closely in front of the eye, would take the place of the increased convexity of the lens in giving rays from a near point a direction as if they came from infinity. The table on page 94 gives the range of accommodative power which an emmetropic eye at different ages is found to possess.

In hyperopia the range of accommodation is diminished to an extent expressed by the number of a lens which will enable the eye to see distant objects without accommodation.

The Association between Accommodation and Convergence.—Convergence is the power of directing the visual axes of two eyes to a near point, and is effected chiefly by the action of the internal recti. The nearer an object, the more convergence is necessary, and usually for every increase of the convergence there is a certain increase in accommodation, the internal recti and ciliary muscles acting in unison. Although accommodation and convergence are usually harmonious in action, they may take place separately and independently. If we paralyze the accommodation with a mydriatic, convergence is not interfered with, and also in advancing life, when greater contraction of the ciliary muscles is necessary to produce the requisite change in the convexity of the lens, the amount of convergence remains the same. It must be remembered that the relations between accommodation and convergence are necessarily very different in ametropia, and this important point will be discussed later.

The diminution of the power of accommodation by age to such an extent as to interfere with the use of the eyes for ordinary near work is called *presbyopia*.

EXAMINATION OF THE EYE.

The student is advised to follow some systematic method in the examination of a patient consulting him for ocular trouble. No one plan can be arbitrarily dictated; different data will be required by different persons, and the authors suggest the following comprehensive plan, which may be modified at pleasure:

- I. Record the Name, Address, Sex, Age, and by whom referred.
- II. The History, including the date of the present trouble, previous attacks of ocular disease, family predisposition, and any useful collateral data.
- III. The Subjective Symptoms:
 - i. Inquire as to pain, including the location, kind, duration, etc.

The Subjective Symptoms (continued):

2. Smarting, itching, or other uncomfortable sensations about the eyes.
3. Increased lacrimation, its character and possible cause.
4. Possible reflex troubles: Headache, indigestion, neurasthenia, etc. Inquire as to the character of the headache; whether frontal, temporal, occipital, "sick," neuralgic, etc.; whether worse in the morning or evening.
5. Alterations in vision:
Record the visual acuity for distance and near. Inquire whether the diminished vision is constant, and whether the onset was gradual or sudden, and how long since it began. Color-sense and light-sense and the field of vision may be tested. Scotoma scintillans, muscæ volitantes, or dark spots before the eyes, etc., may be noted.

IV. Objective Symptoms:

1. Inspect the lids, cilia, lacrimal apparatus, conjunctiva, cornea, iris and pupil, and anterior chamber.
2. Measure the intraocular tension.
3. Test for muscular anomaly by the cover-test.

V. Ophthalmoscopic Examination:

1. Examine the media for transparency.
2. Examine the disc for shape, size, color, cupping, blood-vessels, etc., and refraction.
3. The peripheral eye-ground.
4. The macular region.

VI. Objective Examination of Refraction:

1. By the ophthalmoscope.
2. The retinoscope.
3. The ophthalmometer.

VII. Subjective Examination of Refraction:

1. By the test-lenses.

VIII. Test for Muscular Insufficiency and Squint.

SIMPLE INSPECTION.

Notice whether the eyelids are swollen, hypertrophied, or faulty in form, shape, position, or movements. Normally, the lids follow the movements of the eyeball. In exophthalmic goiter this harmony does not exist. This symptom was first noticed by von Graefe, and has been named after him. It has since been shown by Gowers and others that this sign is present in some central cerebral lesions.

The cilia should be inspected, and their form, size, and position carefully noted, as many unpleasant conditions may arise from misplaced cilia.

The position of the lacrimal puncta should be noted, and whether or not they are patulous. In the normal state the lacrimal sac is empty, while if it is distended with mucus or pus, pressure with the finger will usually cause escape of the contents, either from the nose or from the puncta. Further examination is effected by lacrimal probes.

The conjunctiva is normally so translucent as to allow the bluish-white sclera to show through; it contains only a few minute blood-vessels. In age there may be a deposition of fat in the subconjunctival tissue, giving a yellowish tinge to the membrane, and its translucency is additionally affected by an increase in the size and number of blood-vessels. In inflammatory conditions of the conjunctiva it should be thoroughly examined for the presence of a foreign body or an inverted cilium. The surface of the bulbar conjunctiva is first inspected, and then the lower sulcus, which is easily brought into view by simple tension downward with one finger. Eversion of the upper lid is readily effected without the use of a probe or other instrument by telling the patient to look down, seizing the edge of the lid and cilia with the thumb and forefinger of the right hand, and drawing the lid first forward and downward away from the globe, and then upward over the point of the thumb or forefinger of the left hand, which is held stationary on the lid and acts as a fulcrum.

Conjunctival injection is recognized by its brick-red color; by the great irregularity, tortuosity, and intimate anastomosis of the blood-vessels; by the mobility of the vessels on the sclerotic; by the fact that pressure applied through the lid to the globe produces a distinctly anemic spot; by the injection being more intense on the lids and in the culdesac, and diminishing toward the cornea; by the accompanying mucous or mucopurulent secretion.

Ciliary injection is distinguished by its pink appearance ; by the vessels running in a straight parallel course, radiating from the cornea ; by the immobility of the vessels when the conjunctiva is moved ; by the fact that gentle pressure on the margin of the lower lids produces an anemic spot, which gradually becomes pink when the pressure is removed ; by the congestion being most intense nearest the cornea, and fading away toward the equator of the globe.

The cornea is perfectly transparent and glistening in health, and returns diminished erect images of all objects held before it. The



FIG. 12.—OBLIQUE ILLUMINATION.

shape of the image is diagnostic of the curvature of the cornea. The iris and the pupil are readily seen through the cornea. A foreign body, abrasion, opacity, ulcer, scar, or vascular formation is usually readily detected by simple inspection in a bright light, or with the ophthalmoscope and a high convex lens ; but it is always best to use what is called focal or oblique illumination. (Fig. 12.) This method is effected by placing the patient in the line of the source of illumination, to the right side if the left eye is to be examined, and focusing the rays of light obliquely on the cornea with a convex lens held in the hand of the surgeon nearest the light. The illuminated point is

viewed either directly or through a magnifying lens held at the focal distance from the patient's eye. Diffuse keratitis, corneal abscess, leukoma, and other similar corneal affections, as well as lenticular opacities, should be examined by oblique examination.

The exact extent of the corneal abrasion of an ulcer may be ascertained by the application of a drop of a solution of fluorescein in the lower culdesac and rubbed over the eyeball. A few drops of boric acid solution are then instilled to wash away the superfluous stain, and the denuded area is stained a bright yellowish-green color. If the epithelium is changed and roughened but not denuded, as in keratitis and glaucoma, then the defective spot does not stain.

The aqueous humor is so transparent in health as to be invisible, but may be rendered turbid by inflammatory and hemorrhagic deposits, or may contain pus which gravitates to the bottom of the anterior chamber, forming a condition known as hypopyon.

The iris is ordinarily bright and presents a polished surface. The pigmentation and fibrillation are distinctly visible, and the pupil is perfectly round, and surrounded by a ring of dark pigment. The size of the pupil in its usual state varies with each individual. A general average is four mm. The pupils should be nearly equal in size and should at all times respond to light. The patient should be placed before a window or light, the surgeon standing before him, and one eye permanently obstructed either with a hand or bandage; then one hand should be placed over the exposed eye and quickly withdrawn. Under the shadow the pupil dilates, and when the hand is removed it quickly contracts. This is a direct reflex by means of the optic nerve. To study the consensual reflex, the patient is placed in a room near a point of light and the rays focused gradually on the cornea of the proximal eye, the eye farthest removed from the light still being in the shade. In health a simultaneous and sympathetic contraction of the shaded pupil is also seen. The pupil normally contracts in the act of convergence, and the patient should be directed to look at some distant object and then at an object near the tip of the nose, and the variations in the size of the pupil noticed. There are certain conditions, such as locomotor ataxia, in which the eye contracts as usual in accommodation, but has lost its contractility to light. This condition is commonly known as the Argyll Robertson pupil and is a significant diagnostic sign. If the eyes do not react at all to light and accommodation, there is probably disease of both optic

nerves. Permanent dilatation (mydriasis) and contraction (miosis) will be spoken of under *Diseases of the Iris*. Further inspection of the iris should determine whether it is steady or tremulous, and whether it is in its normal vertical position, or is convex and displaced forward toward the cornea, or concave, depressed toward the vitreous, thus forming a shallow or deep anterior chamber. Instead of being circular the pupil may be oval, with its greatest diameter horizontal, as is often seen in glaucoma. Adhesions of the iris to the anterior capsule of the lens or to the posterior surface of the cornea, called *synechiæ*, also distort the pupil. Focal illumination and examination with a high convex lens with the ophthalmoscope render iritic adhesions more conspicuous.

MEASUREMENT OF THE TENSION OF THE EYEBALL.

The surgeon stands in front of the patient, who is directed to look downward. All but the index fingers of the surgeon's hands rest over the eyebrow of the patient, and the tips of the index fingers through the closed lid, alternately and slightly, indent the eyeball. The educated sense of pressure (*tactus eruditus*) measures the elasticity and resistance. It is well to immediately compare one eye with the other, as there is often quite a noticeable difference between the two. As a standard, the student has the tension of his own eye as a guide, from which any abnormal tension can be estimated. In glaucoma the eyeball is often hard, and the normal sense of elasticity is wanting. In certain extensive destructions of the choroid and liquefaction of the vitreous the eyeball is soft and mushy. The eyes of the young are generally softer than those of the old. The degree of tension is expressed by the capital letter T., preceded by a plus sign (+) if there is increase; or preceded by a minus sign (—) if there is decrease. The amount of deviation from normal is expressed by numerals; thus, + T. 1 expresses distinct hardening; + T. 2, decided hardening; and + T. 3, extreme hardening, resisting all efforts to produce dimpling.

The *ophthalmotonometer* is an instrument devised to measure tension mechanically, thus avoiding the discrepancy in the results of several physicians testing the same eye; but these instruments have often been constructed on principles theoretically wrong, and are practically useless.

THE OPTHALMOSCOPE.

Theory.—It is self-evident that rays reflected from the fundus of the eye emerge from the eye in the same direction as that in which they enter it, the refractive media of the eye having the same action on light whether passing in or out. However, as ordinarily seen, the pupil is black. There is no light reflected from the patient's eye into ours, because our own eyes are not a source of light. Now, if the observer's eye is artificially made the source of light, and if he looks in the same direction as that in which the luminous rays enter the observed eye, as, for instance, through the sight-hole of a mirror, illumination renders the interior of the eye visible. This is the fundamental principle of the ophthalmoscope, and it was first explained and made practical by Helmholtz, in 1851.

Upright Image. Direct Method.—The dioptric system of the eye acts as a convex lens of a focal distance of about 20 mm.

If the retina lies within the focal distance f (Fig. 13, H), the eye is hyperopic, and rays leaving the fundus are divergent at the cornea, and the image of the fundus $a' b'$ is *virtual, upright, and magnified*. To see this image the observer must accommodate for its location, or use a convex lens.

If the posterior focal point f lies exactly on the retina (Fig. 13, E), the eye is emmetropic, all rays emerge from the cornea parallel, and no image is formed. If the observer is also emmetropic, the rays passing parallel from the observed eye into his own eye form an image on his retina.

If the retina lies behind the posterior focal point f (Fig. 13, M), all rays emerge from the cornea converging to the far point of the eye under examination. The observer can only receive on his own retina the image of the other's eyeground, when the (virtual) far point coincides with a' , the actual far point of the myopic eye under examination.

To be able, therefore, to examine the upright image of any eye the observer must be able to adjust his own refractive condition to that of the eye under examination. In the ophthalmoscope this is done by means of lenses. If the eye under examination is myopic, an emmetropic observer needs a concave lens in order to make him proportionally hyperopic; a myopic observer needs for the same

purpose a concave lens increased in strength by the amount of his own myopia; a hyperopic observer must increase his own hyperopia by such a concave lens, or decrease it by such a convex lens as will make his (negative) far point coincide with the far point of the eye under examination. In speaking of the theory of the ophthalmoscope, we consider that the observer does not use his accommodation.

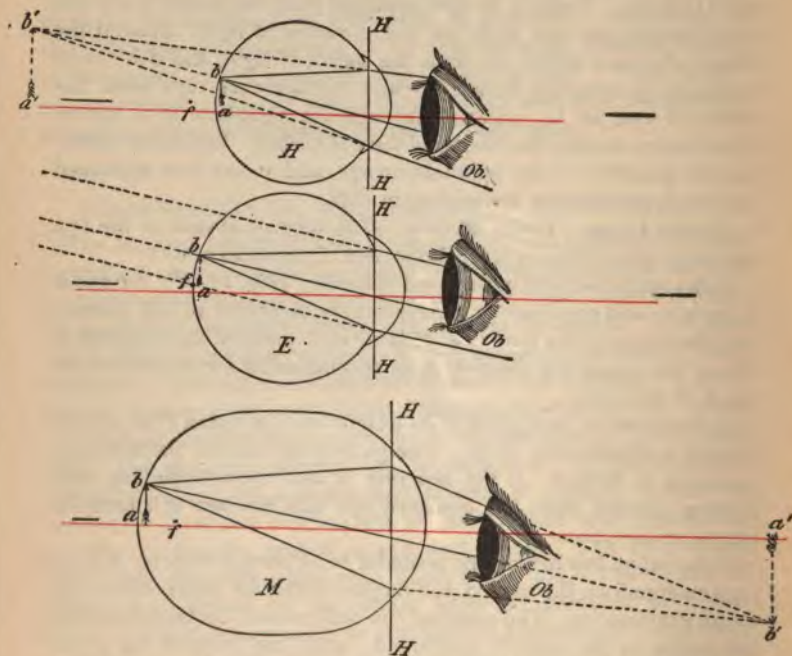


FIG. 13.—EXAMINATION OF THE UPRIGHT IMAGE IN HYPEROPIA, EMMETROPIA, AND MYOPIA.—(After Fick.)

f is the posterior focal point; the red line is the axis.

In ordinary practice such is not the case except in men past middle age who have long practised suspension of accommodation. As a rule the observer employs some accommodative effort which aids him in examining hyperopic eyes, but which compels him to resort to optical aid to see distinctly the funduses of emmetropic and myopic

eyes, and which causes a false estimation of the exact refraction of the eye under examination.

The magnification of the image in the direct method is greatest in the myopic eye and least in the hyperopic eye.

Inverted Image. Indirect Method.—In this method the eye is made artificially myopic by a convex lens; however, in high myopia

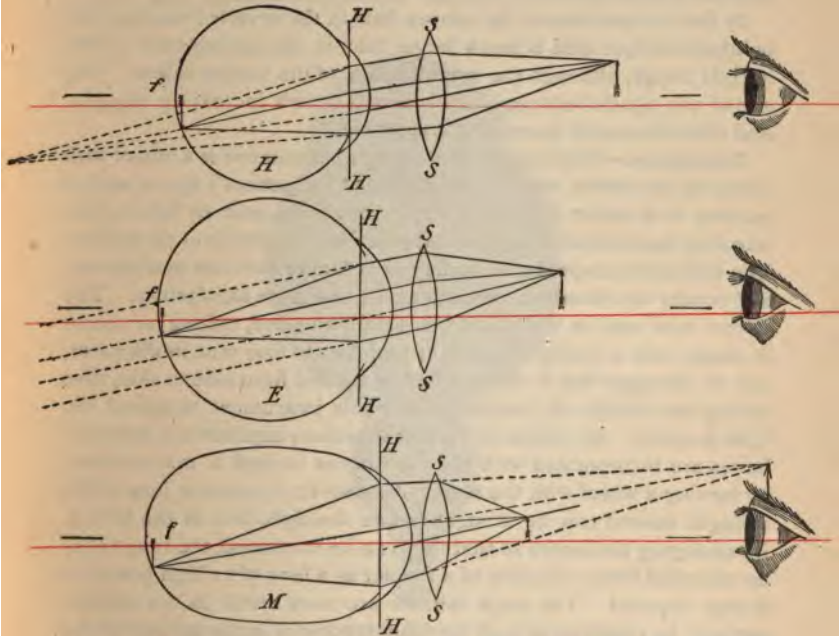


FIG. 14.—EXAMINATION OF THE INVERTED IMAGE IN HYPEROPIA, EMMETROPIA, AND MYOPIA.—(After Fick.)

f is the posterior focal point; the red line is the axis.

if the observer is beyond the image $a' b'$ (Fig. 13, M), and if he uses his accommodation for the location of the image, he will be able to see it without the aid of a lens. In low degrees of myopia the image is so small as to be of little practical use. Figure 14 illustrates the formation of the inverted image in all three refractive conditions of

the eye. The rays from the hyperopic eye H , divergent when they strike the convex lens $S S$, are united the greatest distance from the eye, and hence form the largest image. The rays from the myopic eye M , already convergent when they strike the convex lens $S S$, unite at the shortest focus, and therefore the smallest image is the result. The rays from the emmetropic eye E are parallel when they strike the convex lens $S S$, and the result is an image midway in size between the two others.

By the interposition of the convex lens in the inverted method, the ophthalmoscopic field is much larger than in the examination of the upright image, although the magnification of the fundus is less. The size of the ophthalmoscopic field increases with increasing myopia, and diminishes with increasing hyperopia.

Description.—The simplest form of ophthalmoscope is a mirror with a hole in the center, which is held close to the patient's eye in such a manner as to reflect light from a luminous point near by into it, illuminating the interior of the eye and revealing the details of the fundus. The ophthalmoscopes in use to-day are of more intricate mechanism, and render the examination much easier and more satisfactory. The mirror most used in this country is small, concave, oblong or round in shape, with a central aperture of from two to four mm. in diameter, and so arranged that it can be tilted or rotated from side to side, thus saving the trouble of inclining the whole instrument to reflect the light properly. By means of various ingenious appliances a series of lenses are incorporated with the instrument in such a manner that, by turning a wheel with the finger, the convex or concave lens of the strength desired can be brought before the sight-hole in the mirror. By arranging the lenses so that they can be combined, the range may be extended from a fraction of a diopter to a lens of as high power as is ever required. The large mirrors are more useful in the indirect method, in retinoscopy, and for illuminating a large surface of the eye. In the direct method a very small mirror is as good or better than a large one. A small sight-hole gives a more distinct image, and does not necessitate so much accommodation or optical aid in examining slightly ametropic eyes. The large sight-hole is better for the accurate estimation of refraction. As the direct method is more generally employed, and refraction is not ordinarily estimated by ophthalmoscopy, and retinoscopy is usually performed with a special plane retinoscopic mirror, for all practical purposes it is better to use a *small* mirror with a small sight-hole.

There are many forms of ophthalmoscopes, for all of which some advantage has been claimed. The model of Loring is cheap and answers all practical purposes, but it is awkward to use and necessitates removal from the eye and a combination of lenses to secure the higher powers. To avoid these and other disadvantages the instrument described below (Fig. 15) was designed and has proved most satisfactory to the author. It consists of two superimposed lens-discs, 34 mm. and 37 mm. in diameter respectively, each containing 14



FIG. 15.—PYLE'S OPHTHALMOSCOPE. (Actual Size.)

apertures for lenses. Each disc has independent movement. The inner disc—that is, the one nearest to the observer's eye—contains the high-power lenses, both convex and concave. Its circumference is milled and it is rotated directly by the finger, as in the Loring instrument. The outer disc—that is, the one nearest to the mirror—contains the low-power lenses, both convex and concave. A toothed edge is cut on its circumference, and it is rotated by a lower driving wheel,

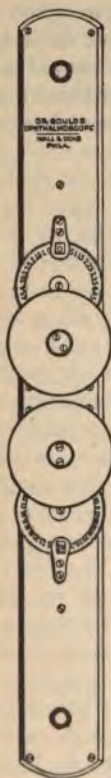17 mm. in diameter. The two discs are inclosed in a metal case with a detachable handle. The lenses are six mm. in diameter. They are stopped by a spring which clicks as each lens is wheeled into place.

The purposes in view were to obtain :

1. Neatness, compactness, and durability.
2. Avoidance of direct rotation of the disc containing the low-power lenses by the finger close to the patient's nose and cheek, as in the Loring instrument.
3. Continuous movement and successive increase of both convex and concave lenses up to 24 D. without removal from the first position before the eye.
4. Avoidance of combinations of lenses.
5. Continuous registration and single registering aperture in the case.
6. A small, round, rotary mirror, small aperture, with absolute exclusion of direct or reflected light in the space between the observer's eye and the sight-hole of the mirror.
7. Simplicity and cheapness.

The dimensions of the instrument are $1\frac{1}{2}$ in. wide by $2\frac{1}{4}$ in. long. There is no serviceable instrument of smaller size made. It can be easily carried in the vest-pocket. The exact size and shape are shown in the accompanying illustration (Fig. 15). There are no points of special wear and tear or of fine adjustment to get out of order. The case and all the framework are made of metal.

FIG. 16.—GOULD'S
OPHTHALMOSCOPE.
($8\frac{1}{4}$ in. \times 1 in.)



If a more elaborate and expensive instrument is desired, that designed by Morton is very satisfactory. Still more complete and elaborate is the instrument shown in figure 16. As in the Morton ophthalmoscope, the Rekoss disc is dispensed with and the lenses are arranged in revolving, endless chains, after the idea of Couper. There are two series—those most used at one end, and the higher numbers, both plus and minus, at the other. The arrangement may be changed so that a surgeon with high ametropia, except in rare

instances, will still seldom be compelled to transfer the mirror so as to use the high-power lenses. The transfer, however, requires but an instant. There are sixty lenses, all the lower powers proceeding from zero by 0.5 D. intervals; the highest minus lenses being 40 D., the highest plus, 30 D. The instrument requires no handle itself when used, being grasped by the hand. The mirror is turned at any angle, so that examination of an eye is easy, whatever the position of the patient or the light. The size of the sight-hole, by an ingenious device, can at pleasure be made large or small.

In addition to the ordinary instruments, binocular and astigmatic ophthalmoscopes are among the many devised.

USE OF THE OPHTHALMOSCOPE.

Direct Method (Fig. 17).—The patient is placed in front of the source of illumination, and to the side of the eye to be examined, the light



FIG. 17.—DIRECT METHOD.

behind him so that it shines on his temple, just touching the tips of the outer lashes. He is then told to look straight ahead to an object on a level with his eyes across the room. To examine the patient's right eye the surgeon sits or stands, and holds his ophthalmoscope in his right hand before his own right eye. To examine the patient's left eye he places himself to the left of the patient and holds the ophthalmoscope in his left hand before his own left eye. The ophthal-

moscope is brought close to the eye under examination, the mirror of the ophthalmoscope having been inclined and the instrument held in such position that the light from the source of illumination will be reflected directly into the patient's pupil; then, if the media are clear, a red glare called the *fundus reflex* is seen through the hole in the mirror. If the examiner wears glasses, he need not remove them; in fact, if he is astigmatic, he had better accustom himself to working with his correcting lenses on.

Examination of the Media.—The reaction and form of the pupil are first noticed. If a foreign body or opacity is present in the pupillary area, it appears as a dark spot on a red background. A slight corneal opacity appears only as a mere shadow. It must be remembered that spots on the cornea and lens always maintain their same relative position and are immovable, while opacities in the vitreous are usually freely movable and can be diagnosed by their change of position as the patient turns the eye quickly in various directions and then looks straight forward. To locate corneal or lenticular opacities, in addition to focal illumination, we take advantage of the phenomenon of *parallax*, which is governed by the rule that *opacities lying in front of the pupil move in the same direction as the patient's eye, while opacities behind the pupil move in the opposite direction to the patient's eye*, and the extent of this apparent movement enables us to approximately determine the distance of the opacity either in front or behind the pupillary plane. After having observed any anomaly of the pupil or media at a distance of from 12 to 16 inches, a strong convex lens (10 D. to 16 D., according to its location) is then wheeled before the sight-hole of the ophthalmoscope, which allows the observer to approach closer to the patient's eye, and greatly magnifies the conditions present.

Examination of the Fundus.—If the media are clear, the surgeon approaches close to the patient's eye and at once the details of the eye-ground become visible. (See Frontispiece.) The refractive media of the eye magnify the details of the fundus about fourteen times, and by this fortunate circumstance the minute details of the eye-ground are plainly visible. Probably the first distinct object will be a retinal vessel which can be easily traced to the most prominent part of the fundus, the optic disc. At this point a bright whitish or pinkish reflex is seen, standing out in sharp distinction to the surrounding red fundus. By adjusting the proper lens before the sight-hole in

the mirror the outlines of the disc may be brought sharply into view. The average size of the normal disc as seen by the direct method is nearly that of a twenty-five-cent. piece or a shilling, while to the naked eye it measures only 1.5 mm. Emerging from the disc is seen the central retinal artery and vein, dividing into inferior and superior branches. The veins may readily be distinguished from the arteries by their darker color and their size, about one-fourth larger. Pulsation of the veins is observed under normal circumstances, while pulsation of the arteries indicates a pathologic condition—either rise of intraocular tension or decrease of blood-pressure. Reflexes consisting of bright lines in the middle of the blood-vessels are seen. Frequently a depression may be seen in the disc called the *physiologic cupping*, caused by the branching of the internal fibers of the optic nerve at a lower level than the more external ones. This is white with a surrounding zone of pink. *Pathologic cupping* includes the whole of the disc, and is characteristic of glaucoma. The form, the size, the color, and other appearances of the disc must be further studied. At the external border of the disc is often seen a black, circular *pigment-ring*, bounding the opening in the choroid through which the optic nerve enters. To the inner side of this is the *white scleral ring*, which is not always distinctly circular. A white conus, or even a crescent, may be seen at the edge of the disc if there is choroidal atrophy. In high myopia this condition is noticeable. If there is distinct sign of cupping, the extent may be approximately estimated by the refractive conditions of two points lying at different elevations. The difference in diopters in the lenses required to distinctly focus the two points multiplied by .35 mm. will give us the difference in depth. It is usual to select one point at the bottom of the cup and the other near the surface.

The *parallax test* is based on the fact that in the indirect method, while the whole fundus seems to move along with the lateral movements of the convex lens, the floor of the excavation apparently moves in the same direction, but at a slower rate. This parallax is more marked the deeper the excavation.

The *general aspect of the eye-ground* is then studied, and any abnormalities in the retina, choroid, or sclera should be noted. If there is absence or deficiency of pigment between the retina and choroid, the larger choroidal vessels are seen through it, and the eye-ground is streaked with well-defined interspaces. At any portion of

the fundus in which both the retina and choroid are lacking, the white, glistening sclera is seen shining through. To examine the macular region the patient is told to look into the light coming from the mirror, or, better, beyond it in the same direction, which movement of the eye generally brings the macula into view. This appears as a dark spot isolated in the fundus, with a small, bright spot in the center, called the *fovea centralis*. There are usually no vessels to be seen in this vicinity. The macular region should always be studied carefully, as any lesion or hemorrhage in this location has an important bearing on the vision of the patient.

Refraction by the ophthalmoscope is usually accomplished by the direct method. Refraction of the macular region is desirable, but as

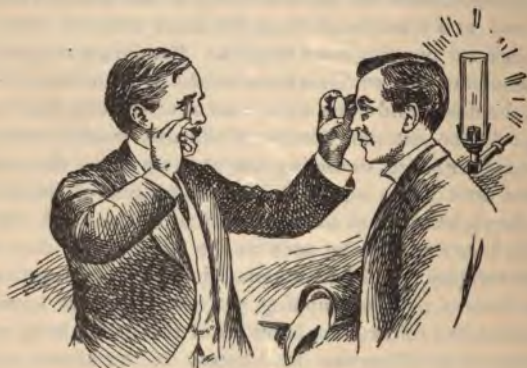

FIG. 18.—INDIRECT METHOD.

the intense dazzling produced by light makes it almost impossible, the disc is usually the objective point selected. The observer first corrects his own ametropia, and as much as possible relaxes his accommodation. It is this inability to regulate the relaxation of accommodation that makes this test unreliable in simple errors of refraction, and in the lower degrees of astigmatism it is comparatively worthless even in the most skilful hands. The retinoscope is a more important and more scientific instrument for the objective method of refraction. Having relaxed the accommodation and corrected his own error, the surgeon moves before the eye the lens which gives him the best outlines of the disc, and subtracts his own correcting lens from the

result. In cases of astigmatism the disc is usually oval, its long diameter corresponding to the axis of astigmatism. Two vessels at right angles to each other in the principal meridians are refracted separately, and the results noted. Glasses should not be prescribed from the ophthalmoscopic refraction alone.

Indirect Method (Fig. 18).—The indirect method is less valuable than the preceding. The image is inverted and less magnified (three or four diameters), but we are able to see a larger part of the fundus at one glance, and we are not compelled to approach so near the patient's face. It also enables the surgeon to intensify his illumination in cases of very small pupil or of cloudy media. In this country the indirect method is being less and less used. The method of procedure is usually the same as in the direct method, except that the surgeon keeps his eye a foot or more away from the patient's face and holds in front of the patient's eye a strong convex lens. However, the surgeon need use but one eye and may stand directly in front of the patient. The lens is usually held at such a distance from the eye that the iris just disappears from view; a plus spheric 4 D. lens may be held before the opening in the mirror to enlarge the image and to replace the observer's strain of accommodation. By directing the light from the mirror through the lens into the eye, an inverted aerial image is formed in front of the lens, and it is this image that the surgeon sees. In high degrees of myopia it is easy to examine the inverted aerial image without a convex lens.

The satisfactory use of the ophthalmoscope, both in examining the fundus and approximately estimating the kind and degree of ametropia, can only be obtained after considerable practice. A normal fundus in both a light-complexioned and dark-complexioned person should be repeatedly studied, as abnormal conditions are not recognized until one is thoroughly familiar with the normal healthy fundus.

RETINOSCOPY.

BY JAMES THORINGTON, M.D.

Definition.—The method of estimating the refraction of an eye by reflecting into it rays of light from a plane or concave mirror, and observing the movement which the retinal illumination makes by rotating the mirror. To avoid confusion, the description of retina-

oscopy that follows will apply to the plane mirror, which is to be preferred to the concave mirror, as it is decidedly more satisfactory for general use and convenience.

The principle of retinoscopy is the finding of the point of reversal, or myopic far point. Should the eye under examination be emmetropic or hyperopic, it must be given an artificial far point.

Synonyms.—Many names have been given to this method of refraction, viz.: Shadow-test, skiascopy, fundus-reflex test, pupilloscopy, etc.; but retinoscopy seems the most appropriate, as it is the retina in its relative position to the dioptric media which we study. At the present time the term skiascopy is suggestive of *x*-ray skiagraphy.

Advantages.—Of all the objective methods of refraction, retinoscopy in the hands of the expert is the most exact, but, like all objective methods, its results should, when possible, be confirmed with the trial-lenses.

Retinoscopy offers the following advantages :

1. The character of the refraction is quickly diagnosed.
2. The refraction is estimated without the verbal assistance of the patient.
3. No expensive apparatus is necessarily required.
4. Little time is taken to estimate the refraction.
5. It is of inestimable value in the young, in the feeble-minded, the illiterate, in cases of amblyopia, nystagmus, and aphakia; and in such cases the retinoscopic correction may be ordered.

Preparation.—To learn retinoscopy the beginner is urgently advised to study the form, direction, and rate of movement of the retinal illumination from one of the many schematic eyes in the market before attempting the human eye. The beginner should also be thoroughly acquainted with the laws of refraction, and especially understand conjugate foci, for it is the recognition of the point of focus of the convergent rays of light from the eye under examination that gives the true solution of the test.

Before proceeding to the examination of an eye, the beginner must understand several important details, namely :

The retinoscope, or mirror, is of varying form and size. The one recommended is the small plane mirror, two cm. in diameter, on a four cm. metal disc, with a two mm. sight-hole at the center of the mirror, made by removing the silvering and *not* by cutting a hole through the glass. (Fig. 19.)

The light should be steady, clear, and white, and secured to a movable bracket. For general use the Argand burner is best. As only a small portion of the flame is used, it is necessary to cover most of it with a screen.

The screen, or cover-chimney, is made of thin asbestos and of sufficient size to fit easily over the glass chimney of the Argand burner. The opening used, generally one cm. in diameter, should be opposite to the brightest part of the flame. An asbestos cover-chimney is used in preference to metal, as it intercepts most of the heat.

The room for retinoscopy must be darkened, and the darker the better; all sources of light except the one in use must be excluded. This must be insisted upon, as darkness offers the best contrast to the test.

Position of the Light and Mirror.—The rays of light coming out of the opening in the light-screen should be five or six inches in front and to the left of the observer, so that the rays may pass in front of the left eye and fall upon the mirror held before the right eye, thus leaving the observer's left eye in comparative darkness; or this may be reversed if the observer is left-handed. The observer should keep both eyes wide open.

In order to see the movements distinctly, the observer should wear his correcting glasses, but need not make any note of his accommodation as in using the ophthalmoscope.

The patient must have his accommodation thoroughly relaxed with a reliable cycloplegic, and be comfortably seated in front of the observer, preferably at one meter distance, with his vision steadily fixed on the observer's forehead just above the mirror; or, even better, the patient may concentrate his vision on the edge of the metal disc of the mirror, but never directly into the mirror; as that would



FIG. 19.—RETINOSCOPE.

soon irritate and compel him to close his eye. In cases of squint it is particularly necessary to cover one eye while its fellow is being refracted.

Distance of Surgeon from Patient.—Each observer may choose his own distance, and must be governed accordingly. There is no fixed rule of distance, and it will be well for the observer to try different distances and then choose for himself. The one meter distance offers two advantages: it is convenient for the observer in reaching forward to place neutralizing lenses in front of the eye, and in the ultimate result it is easy to calculate 1 D. for this distance.

Reflection from the Mirror.—The rays of light coming from the round opening in the screen to the plane mirror are reflected divergently, as if they came from the opening in the screen situated just as far back in the mirror as they originally started from in front. The nearer the light and mirror are brought together, the brighter will be the reflected rays.

How to Use the Mirror.—It should be held firmly in the right hand before the right eye, so that the sight-hole is opposite the observer's pupil. The movements imparted to the mirror should be very limited, though they may be quick or slow; but never, at any time, should the mirror be tilted more than two or three mm., otherwise the light will be lost from the patient's eye.

With the patient, light, mirror, and observer in position as just described, and as near in line as possible, the observer may find the patient's eye by reflecting the light on to his left hand held between the mirror and the patient's eye, and, when this is done, to drop his hand and have the light pass into the patient's eye.

Retinal Illumination.—This is the portion of the retina that receives the rays of light from the mirror after they have passed through the media of the eye. The size and form of this illumination is controlled in great part by the refractive power of the media.

The Shadow.—This is the nonilluminated portion of the retina surrounding the illumination. When the mirror is tilted and the illumination is passed to one side, darkness precedes and follows it; it is this combination of illumination and nonillumination (shadow) that gives the "shadow-test" its name. The contrast between illumination and shadow is most marked when the illumination is brightest.

Where to Look and What to Look For.—Through a four, five, or

six mm. area at the apex of the cornea, which corresponds to the position and size of the pupil when the effects of the cycloplegic pass away, the observer studies the character of the retinal illumination for (1) form, (2) size, (3) direction, and (4) rate of movement.

Point of Reversal.—This is the myopic far point, the artificial focus of the emergent rays, the point at which the emergent rays cease to converge and commence to diverge, the point conjugate to the retina, or the point where the erect image ends and the inverted image begins.

To Find the Point of Reversal.—In observing the retinal illumination, one of the most important things to study is the *direction* in which it moves, or whether it moves at all. For example: having determined at one meter distance, with a + 2.00 D. lens before the patient's eye, that the retinal illumination moves in the same direction in which the mirror is tilted, and then substituting a + 2.25 D., and the illumination appears to move in the opposite direction; the observer will know at once that the difference in the strength of these lenses, + 2.12 D., would bring the emergent rays to a focus on his retina and that no movement of the retinal illumination could be made out, and this point, when found, is the point of reversal or artificial far point.

The Principle of Retinoscopy.—The point of reversal or focus of emergent rays is always negative in hyperopic and emmetropic eyes. In myopic eyes, however, the emergent rays always focus at some point inside of infinity, and the observer may, therefore, if he is so disposed, by moving his light and mirror closer to or farther from the patient's eye, as the case may be, find a point where the retinal illumination ceases to move. If this should be at two meters, the patient would have a myopia of 0.50 D.; if at four meters, a myopia of 0.25 D.; if at one meter, a myopia of 1.00 D., etc.

It is well for the beginner to remember that when using the plane mirror the illumination on the patient's face always moves in the same direction in which the mirror is tilted, but not necessarily so in the pupillary area, where it might move opposite. It is in the pupillary area that the retinal illumination is spoken of as moving with or against (opposite to) the movement of the mirror, and the diagnosis is made accordingly.

The direction, rate, and form of the retinal illumination are the three essentials to be noted in all retinoscopic work, and should therefore receive individual consideration.

At one meter distance with plane mirror we have the following, *i. e.*:

Direction.—The movement of the retinal illumination going with the movement of the mirror signifies emmetropia, hyperopia, and myopia when the myopia is less than 1.00 D.

The retinal illumination moving opposite to the movement of the mirror always signifies myopia of more than 1.00 D.

Rate.—This is under the control and is influenced in great part by the rate of movement of the mirror itself; yet after a little practice the observer will recognize the fact that there is a certain slowness in the apparent rate of movement of the illumination when the refractive error is a high one and requires a strong lens for its neutralization; whereas, when the retinal illumination appears to move fast, the



STRAIGHT EDGE, INDICATING
ASTIGMATISM.

FIG. 20.

CRESCENT EDGE, INDICATING
SPHERIC CORRECTION.

refractive error is but slight and requires a weak lens for its correction.

Form.—While a large round illumination may signify either hyperopia or myopia, yet astigmatism may be in combination. When the retinal illumination is a band of light extending across the pupil it signifies astigmatism. The presence of astigmatism is known by the straight edge of the illumination; or, in its place, a crescent edge would mean a spheric correction. (Fig. 20.) When the illumination appears to move faster in one meridian than the meridian at right angles to it, astigmatism will be in the meridian of slow movement.

DIAGNOSIS BY RETINOSCOPY.

Emmetropia.—The rays of light from an emmetropic eye proceed parallel, and by reflecting the rays of light into such an eye from a distance of one meter the observer sees a small bright retinal illu-

mination, which moves rapidly in the same meridian through which the light is passed. By placing a $+ 1.00$ D. lens in front of such an eye all apparent movement in the pupillary area ceases, showing that the $+ 1.00$ D. has bent the emergent rays and brought them to a focus on the observer's retina. This $+ 1.00$ D. has made this emmetropic eye myopic just one D., so that in taking the patient thus refracted from the dark room to test his vision at six meters, this one D. of artificial myopia must be removed, thus proving the emmetropic condition.

Hyperopia.—In hyperopia the same conditions hold true as in emmetropia. For example, having placed a $+ 3.00$ D. in front of the eye and found that the previously slow movement with the mirror has ceased, and substituting a $+ 3.25$ D. makes it move opposite, it will be known at once that the $+ 3.00$ D. was the correcting glass for one meter; or, in other words, that the original divergent rays proceeding from the eye were bent by the $+ 3.00$ D. and brought to a focus on the observer's retina. Two D. of this $+ 3.00$ D. would have made the eye emmetropic, but the additional $+ 1.00$ D. made the eye myopic just that amount, and taking the patient from the dark room this 1.00 D. of artificial myopia must be taken from the dark-room result, which would leave $+ 2.00$ D. as the amount of the hyperopia.

Myopia.—The rays of light from a myopic eye always proceed convergently, and to the observer seated at one meter distance the retinal illumination appears to move opposite to the direction in which the mirror is moved *if* the myopia exceeds one D., and to move *with* the movement of the mirror if the myopia is *less* than one diopter. An eye that is myopic just one D. has its emergent rays focusing at one meter, and the observer with his eye at this point does not recognize any apparent movement in the pupillary area.

For example, an eye that is myopic 4.00 D. has its emergent rays focusing at ten inches, and the observer at one meter has the apparent movement of the retinal illumination moving opposite to the movement of the mirror. If a $- 3.00$ D. be placed in front of this eye, the emergent rays then focus at one meter, at which point the observer does not appreciate any movement of the retinal illumination. It will thus be seen that the eye which is myopic more than 1.00 D., retains one D. of its myopia when tested at one meter, and this 1.00 D. must be supplied in taking the patient from the dark room to test his distant vision.

If the observer will remember to always use a plus lens when the retinal illumination moves with the movement of the mirror, and a minus lens when it moves opposite, and allow for the one D. of myopia *when working at one meter*, he will have the following rule to guide him, namely: To add a minus 1.00 D. to the dark-room result in every instance; *i. e.*:

Dark room	0.00 D.	+ 0.25 D.	+ 0.50 D.	+ 0.75 D.	+ 1.00 D.
add	- 1.00	- 1.00	- 1.00	- 1.00	- 1.00
Result	- 1.00	- 0.75	- 0.50	- 0.25	- 0.00

Regular Astigmatism.—The presence of this condition when looking in the eye before any neutralizing lens has been placed in position, can be determined when a band of light is seen extending across the pupil, or when it is possible to note a difference in the rate of movement of the retinal illuminations of any two meridians at right angles to each other. If the spheric error is high and the cylinder a low one, then it will not always be possible to recognize the characteristic band of light (astigmatism) until the approximate neutralizing sphere has been added.

The axis subtended by the band of light after the requisite sphere has corrected the meridian of least ametropia, is the axis for the cylinder in the prescription to be given.

The better way to neutralize cases of astigmatism is to use spheric lenses in preference to cylinders, for by so doing the difficulty of placing cylinders on the exact axis is avoided; for example, in the following formula, + S. 2.00 + C. 1.00 axis 90°, it will be found that a + 3.00 sphere in the dark room will correct the 90° meridian and partly correct the 180° meridian. And that a + 4.00 sphere will correct the 180° and overcorrect the 90° meridian, making a difference in the strength of the two spheres employed of 1.00 D., which is the amount of the cylinder required. After thus obtaining the result, the observer may, if so disposed, confirm it by placing the spherocylinder combination.

Axonometer.—To find the exact axis subtended by the band of light while studying the retinal illumination when the meridian of least ametropia has been corrected, the writer has suggested a small instrument called an axonometer. (Fig. 21.) It consists of a black metal disc with a milled edge, 1½ mm. in thickness, of the diameter of the ordinary trial-lens, and mounted in a cell of the trial-set. It has

a central round opening 12 mm. in diameter—the diameter of the average cornea at its base. Two heavy white lines, one on each side, pass from the circumference across the central opening, bisecting the disc. The axonometer is turned in the trial-frame until the two heavy white lines coincide with the band of light, and the degree mark on the trial-frame to which the white line points is the axis for the cylinder.

Irregular Astigmatism.—This condition is either in the cornea or lens, generally in the former, making it difficult in any instance to study the refraction, as the reflex is more or less obscured by areas of darkness, so that to study the condition the observer may have to



FIG. 21.—AXONOMETER IN POSITION.

change his working distance toward or from the eye. The kinetoscopic picture obtained by moving the mirror so as to make the light describe a circle around the pupillary edge of the iris is quite diagnostic of the corneal condition. Whatever result is obtained, the observer must take care to refract in the area of the cornea that will correspond to the small pupil when the effects of the cycloplegic pass away. It is best in these cases to retain the correction found as a guide in a postcycloplegic manifest refraction.

Irregular Lenticular Astigmatism.—This is often more uniform than the corneal variety, and is characterized by faint striæ in the lens pointing in toward the center from the periphery. When very faint

these striæ are fine, and only seen when the point of reversal is approached. If the striæ are prominent, they are often seen by the ophthalmoscope even before the use of the cycloplegic.

Scissors Movement.—Cases in which this movement is seen are not unusual, and are recognized by the presence of two parallel bands of light with a dark interspace; the axes of these bands are generally horizontal or inclined a few degrees therefrom. By tilting the mirror in the vertical meridian these bands are seen to approach each other, like the opening and closing of the scissors blades, and hence the name. In neutralizing a case of this kind the observer must look carefully between the bands for the central illumination, and to a great extent ignore the bands.

Conic Cornea.—In this condition the observer is impressed at once with the bright, round, central illumination that moves opposite to the movement of the mirror, the peripheral movement being with the mirror, unless perchance the margin be myopic also, but of less degree. The best way to refract a case of this kind is to follow the suggestion given for refracting cases of irregular astigmatism.

Spheric Aberration.—There are two forms of this condition, positive and negative. In the positive form the peripheral (at the edge of the iris) refraction is stronger than the central, and in the negative the peripheral is weaker than the central; that is to say, in the positive form, when the neutralizing lens has reduced the retinal illumination in size and increased its rate of movement, and the point of reversal for the center of the pupil is close to one meter, the peripheral illumination grows broader and has a tendency to, and often will, crowd in upon the center, giving the idea of overcorrection, the refraction in the periphery moving opposite. The observer must be on his guard for this condition. The negative form is just the opposite of the positive, and has the central illumination neutralized and the peripheral still moving with the movement of the mirror. This is the condition seen in conic cornea.

TEST-CARDS.

It has been discovered that the smallest retinal image which can be perceived at the macula corresponds to a visual angle of $1'$. The visual angle is the angle included between two lines drawn from two opposite edges of the object through the nodal point. Following this

principle, test-types have been constructed in such a manner that every letter is so made that when at its proper distance it subtends an angle of $5'$.

To find the exact size of letters at different distances which subtend an angle of $5'$, we multiply the distance expressed in millimeters by the tangent of the angle of $5'$ (.001454), and the result will be the correct size of the letters, both vertically and horizontally, expressed in millimeters.

Snellen's letters are constructed in such a manner that each part is separated from the other parts by an interval equal to not less than the arc subtending $1'$ at the nodal point. The ordinary cards in use give a series of letters which should be seen by the emmetropic eye at distances varying from 3 to 45 meters. The distance in feet is usually also noted opposite each line of letters. Physiologically, the ordinary construction of black letters on a white background is wrong. White surfaces reflect all the larger part of the light thrown upon them, positively stimulating a relatively large portion of the retina, leaving, as it were, small portions of non-stimulated parts, corresponding to the black letters to be distinguished. The positively stimulated portions should be the letters, and the enormously larger part should be black and unstimulated, saving much ocular labor and weariness. In testing the eyes under a mydriatic, and in amblyopic, strained, and asthenopic eyes, we have found that test-cards with black background and white letters (Fig. 22) are more satisfactory than the ordinary test-cards.

It is well to have two series of letters, to avoid doubt from the patient learning the letters of a single card.

The mode of procedure in determining the acuity of vision with test-type is as follows: The patient is placed with his back to the light in

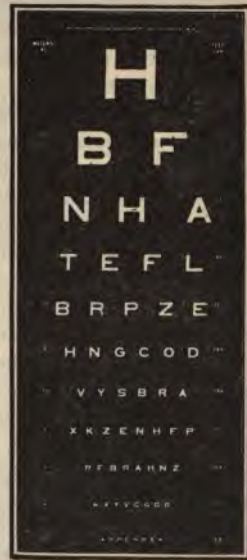

FIG. 22.—WHITE TEST-LETTERS ON BLACK BACKGROUND.

front of the test-cards, which must be hung at a distance of five or six meters and be well illuminated by artificial light from a reflector, about two feet away and to the side. In using the cards with the dark background, *the card must be inclined at such an angle that the patient sees no disagreeable reflection from its surface.* We then cover the eye not under examination, and ask the patient to read the lowest line possible. If seated at six meters' distance he read the line marked six meters, his visual acuity is expressed by the fraction $\frac{6}{6}$; if he read the line marked four meters, he has remarkable acuteness of vision, and we express it by the fraction $\frac{6}{4}$; if he is amblyopic or ametropic he will not be able to read the six-meter letters, and may possibly read only the line marked 15 meters, when his visual acuity is expressed by the fraction $\frac{6}{15}$. Some surgeons prefer to use feet instead of meters in their estimations, and seat their patients at about 20 feet from the card, and express the visual acuity by using 20 for the numerator and the foot-number of the card seen as the denominator. It sometimes happens that the patient is not able to read any letter on the card at six meters' distance; in such a case we have him gradually approach the card, or bring the card toward him, until the top letter is distinguished. This distance is noted and serves as the numerator in the fraction of visual acuity.

With illiterates it is best to use a regular illiterate card, consisting of lines shaped like the plain capital letter **E**. The patient is asked to tell which way the prongs of the **E** point, upward, downward, to the right, or to the left. More difficult are the Burchardt dots for counting. These cards are constructed on the Snellen principle. For foreigners special cards have been constructed. The German and Hebrew letters are often of value in hospital work.

Near Type.—The test-cards usually employed to estimate the accommodation are after the model of Jaeger, and are merely printer's types of various sizes. These cards have the advantage of closely resembling the work ordinarily done by the eye in reading, but have the disadvantage that they are not arranged on any scientific plan. It is possibly better to use cards in which each word is composed of several letters constructed in strict conformity with the Snellen basis of letter-formation. Figure 23 represents a card of this description. On account of the impracticability of ever printing books and papers with white letters on black background, the ordinary appearance of reading matter should be imitated in the near card, and it is in the

the card for distance examination only that we advise the white letters.

In most cards there is a purposive succession of confusion-letters, such as C O D, H M N, E L F, etc., which are of value in recognizing astigmatism. The mode of procedure with the near type is to find the farthest and nearest point at which the smallest recognizable type is legible. In presbyopes it is necessary to use a convex lens of a strength varying with the age of the patient. Each eye should be examined separately.

The light-sense may be approximately estimated by the degree of illumination necessary to make the letters on the test-card legible. In the same manner we can roughly measure the difference in acuity of vision under different degrees of illumination. For exact measurements of the light-sense we use an instrument called a photometer. One of the best instruments of this class is that designed by Dr. Henry, of Leicester, England. The instrument consists of an oblong box, open at the

anterior end, through which the patient looks; to the edge of this opening a hood is affixed, which is drawn over the patient's head during the examination, in order to exclude any external light from the candle. At the posterior end is an aperture, opposite which are nine discs of 15-ounce standard opal glass, so arranged that one by one they can be swung back. Behind that, on a box,



FIG. 23.—TEST-CARD FOR NEAR VISION.

$\frac{1}{2}$ of a meter distant from the box, is a standard candle in a spring holder, keeping the flame at a constant level; behind this is a shade to prevent flickering. The photometer rests on a stand. The patient is kept in the dark for five minutes in order that his retina may become adapted to the dark. The eye not under examination is closed with a light bandage. The patient looks into the instrument, and the opal discs are removed, one by one, until the patient detects any light. If he detects any light from the candle-flame through five of the opaque discs, his minimum light-sense (L. M.) is noted as five, etc. If the eye does not readily perceive the difference in illumination between two discs, the light-sense is also abnormal, the light difference (L. D.) being too high. L. M. is greatest in early and middle life, and gradually diminishes toward old age. Diseases primarily involving the nervous elements of the optic nerve show defective L. D., while diseases primarily involving the choroid and retina cause defective L. M. In chronic simple glaucoma L. M. is much reduced, while it is only slightly affected in simple atrophy of the optic nerve.

Adaptation of the retina is the power of gradual adjustment for the perception of images when there is a change from bright to dull lights. This must not be confused with light-sense, which may be intact while the adaptation may be defective, as in cases of night-blindness.

TEST-LENSES.

The case of test-lenses should contain a set of + spheric lenses and — spheric lenses in pairs from 0.12 D. to 20 D.; a set of + cylinders and — cylinders from 0.12 to at least 6 D., and a set of prisms from 0.5 degrees to at least 20 degrees; several plain colored glasses, opaque glasses, blanks, stenopaic discs, etc., and a trial-frame.

Trial-frames for test-lenses are of several varieties. The most common form (Fig. 24) consists of an arrangement whereby the nose-piece may be rapidly adjusted by means of a screw, so as to make the frame conform to any height or depth of the bridge of the patient's nose. A vertical and horizontal adjustment by a rack-and-pinion movement on the nose-piece enables us to quickly and perfectly adjust the frame to any peculiarity of the patient's face. A millimetric scale with a pointer moved by a double rack-and-pinion device gives the distance between the pupils at a glance. The lens-holder

consists of two hollow grooves, with a slot in each eye-piece to permit rotation of cylindric lenses with handles. On the outside of each eye-piece are hooks for adjusting an additional lens or a blinder. The markings on the eye-pieces begin at zero at the temporal side, and run to the nasal side to 180° . The axis at which the cylinder is inclined is found by comparing the axis marked on the test-cylinder with the coinciding number on the trial-frame. However, as the trial-frame is not often perfectly adjusted, it is well for the surgeon to learn to estimate the angle, particularly in the vertical and horizontal merid-



FIG. 24.—TRIAL-FRAME FOR TEST-LENSES.

ians, with his eye. In placing strong lenses in the trial-frame it is well to have the convex surface of convex lenses turned away from the eye, and the concave surfaces of concave lenses turned toward the eye. In all cases the lenses should be placed as near the eye as possible.

Practical Procedure with the Test-lenses.—Having been assured that all the accommodation is suspended, we seat the patient to the left of the table containing the test-lenses, and commence the examination with the right eye, covering the left with an opaque lens or

metal disc. We then ask the patient to read down the card situated at five or six meters' distance, until he comes to the letters that are indistinct; we then commence the application of the lenses. Experience will give us a good idea what lens to start with, by noting the amount of interference with vision after mydriasis. If the patient is able to recognize only the largest letters on the card, he is either amblyopic, myopic, or highly hyperopic, and is quite likely in every case astigmatic. If the patient is amblyopic from intraocular disease or other cause, the application of a pin-hole perforated disc will not increase his vision, and it is not likely that glasses will improve his sight. If the trouble is only refractive, he will at once notice an improvement of vision through the small perforation. If he is astigmatic, he will select the stenopaic disc (a blank disc with a small open slit, described under Astigmatism) at an angle corresponding to the axis of his astigmatism, and the two meridians may be refracted separately by spheric lenses alone.

It is perhaps well to assume the simplest examination of a moderate degree of ametropia.

First using a low power + spheric lens (0.25), we inquire if the confused letters are improved by it; if the patient answers yes, we try a corresponding strength astigmatic lens starting at axis 90° , and inquire if the vision is still better; we then rotate the cylinder in the frame, finding the axis at which the letters are best seen. If the patient prefers the cylinder to the spheric lens, we put on the cylinder at the axis preferred, and determine the line read with this correction. A low power + spheric lens (0.25) is held in front of the eye which is already corrected by a cylinder, and we inquire if the vision is improved, and also whether a correspondingly low + cylinder still further improves the vision; if the spheric lens is preferred to the cylinder, it is put in the trial-frame, back of the cylinder first applied, and the same mode of procedure further pursued, testing with a low spheric lens and then a low cylinder until the vision can no longer be improved. The result is then noted and the examination of the other eye commenced in the same manner.

If, however, neither a + spheric nor a + cylinder lens improves the vision, a - spheric and a - cylinder are used in the preceding manner. It sometimes happens that a + cylinder is accepted, but further improvement can not be obtained by an advance in the strength of a cylinder, or by the addition of a + spheric lens; in

such case we immediately resort to a — spheric lens or a — cylinder, placed at an axis at right angles to the position at which the + cylinder was preferred. Occasionally rotating a cylindrical lens of one eye, with both eyes corrected and participating in vision, will definitely determine a doubtful axis better than if the fellow-eye is excluded by an opaque disc.

An exact knowledge of the proper manner in which to use the test-lenses can only be obtained by long experience; a few other practical points will be given in the discussion of the various forms of ametropia.

Other Methods of Determining Refraction of the Eye.—In this discussion the many other ingenious methods devised will be left to the numerous text-books on ophthalmology. For practical purposes it is only necessary to describe the ordinary and universally used subjective method with test-cards and test-lenses, and the objective methods of importance—namely, refraction with the retinoscope, with the ophthalmoscope, and the estimation of corneal astigmatism by the ophthalmometer.

PRESCRIBING AND TESTING GLASSES.

Mode of Prescribing Lenses.—The right eye is designated by R., R. E., or O. D. (*oculus dexter*), and the left eye by L., L. E., or O. S. (*oculus sinister*). Both eyes are generally designated by B. E. or O². The convex spheric lenses are designated + S. or Sph., and the concave spheric lenses — S. or Sph. A convex cylindrical glass is designated + C. or + Cyl., and a concave cylindrical glass, — C. or — Cyl. The combination sign \ominus and the diopter (D.) are superfluous, as they are understood. Ax. indicates axis. The degree mark is not necessary in ordering cylinders. To illustrate the various forms of prescriptions, examples of each are given.

Simple Hyperopia :

R., + S. 1.25

Simple Myopia :

L., — S. 1.25

Simple Hyperopic Astigmatism :

R., + C. 1.50 ax. 90

Simple Myopic Astigmatism :

L., — *C.* 1.25 *ax.* 180

Compound Hyperopic Astigmatism :

R., + *S.* 1.00 + *C.* 1.25 *ax.* 90

Compound Myopic Astigmatism :

L., — *S.* 1.00 — *C.* 1.25 *ax.* 180

Mixed Astigmatism :

R., + *S.* 1.00 — *C.* 1.50 *ax.* 180

L., — *S.* 1.00 + *C.* 1.75 *ax.* 90

In ordering a plane glass in cases in which one eye is blind or emmetropic, we use the term *plano*.

R., + *S.* 1.25

L., *Plano*

Bifocal glasses are indicated by the peculiar double form of prescription, and the word bifocal. A complete bifocal prescription, which may be taken as a model form of prescription, is as follows :

Adam Smith, M. D.,

5000 Chestnut St., Philadelphia.

January 1, 1897.

Mr. John Smith,

Bristol, Pa.

R., + *S.* 1.00 + *C.* 1.25 *ax.* 90 } *For distance.*
L., + *S.* 0.75 + *C.* 0.25 *ax.* 90 }

R., + *S.* 3.00 and *Cyl.* } *For near.*
L., + *S.* 2.75 and *Cyl.* }

Bifocals in 14-k. gold, rimless spectacles.

Adam Smith, M. D.

Opaque glasses, tinted glasses, etc., should be fully explained in English on the prescription.

Every prescription should state whether the glasses are for constant use, or for near or distant use only. Trade terms are convenient to indicate the style of glasses ordered—as, for instance, 798½ means 14-k. gold, rimless spectacles. However, it is possibly better to write the full directions out.

Finding the Center of Lenses.—Expert opticians will endeavor to make the geometric and optic centers of lenses coincide, unless decentration is desired to obtain prismatic effect. To find the optic center of a lens, we look at two lines, several inches long, at right angles to each other, in the shape of a + sign, through the lens held a few inches above. We rotate the lens until both the vertical and horizontal lines appear continuous when viewed through the lens, and when viewed beyond the lens. Then the point on the lens just opposite to the center where the two lines cross is the optic center of the lens, and should be marked in ink. It is necessary to know the optic center of a lens, to see if it corresponds to the center of the pupil when the glasses are in position on the face, and properly to apply a neutralizing cylinder.

Neutralization of Lenses.—The lens is held a few inches in front of the eye, and some object, such as the vertical and horizontal lines of a window-frame or the test-letters, is viewed through it. The lens is then moved to the right, and if it is convex, the object will move to the left; if it is concave, the object will move with the lens to the right. Having determined what sort of a spheric lens we have under examination, we proceed to neutralize it by holding successively a concave lens if convex, or a convex lens if concave, until no movement of the object is perceived through the lens; therefore, to find the strength of a spheric lens it is only necessary to combine it with successive lenses of the opposite sign until one is found which neutralizes the apparent movement of objects seen through the lens under examination. The more rapid the apparent movement, the higher the power of the lens required to neutralize.

Cylindric lenses only show movement in the direction opposite to their axes; the movement is against in convex cylinders, and with in concave cylinders. To find the axis, an object presenting a straight line, such as the vertical line of the window-sash or the edge of a frame, is viewed through the lens. As the lens is rotated about the

visual axis, the portion of the vertical line seen through the lens will appear to be oblique, as compared with that seen above and below the lens. (Fig. 25.) This oblique displacement takes place in a direction contrary to the rotary motion given a convex lens, and in the same direction as the rotary motion given a concave lens. To ascertain the position of the axis of a cylinder it is slowly rotated until the line seen through it appears continuous above and below. (Fig. 26) If motion from side to side produces apparent motion of the object, this line is the axis of the cylinder, and if no motion results, the line is at right angles to the axis of the cylinder. The axis being determined, the cylinder is neutralized by successive cylinders of opposite curvature applied in the same axis.

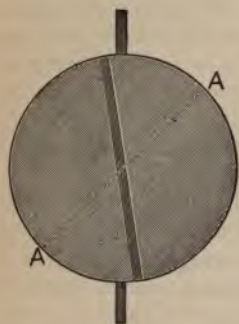


FIG. 25.

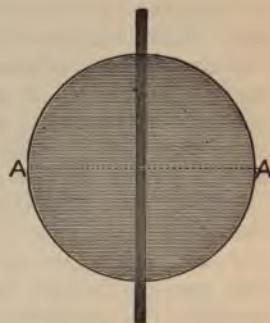

FIG. 26.

Spherocylindric lenses are neutralized the same way as two cylinders with their axes perpendicular to each other. Having neutralized the movement in one meridian, we note the result, and neutralize the movement in the other meridian.

The phacometer is an instrument designed to ascertain quickly the strength of a lens under examination. It is operated by pressing the surface of a spheric lens squarely against three steel pins, the central one of which is movable. When the central one is depressed until all three points touch the glass, the curvature of the lens is indicated on a dial.

Mode of Prescribing Prisms.—When it is found necessary to prescribe prisms, we may distribute the full prismatic strength between

the two eyes, or order it all in one eye; as, for instance, if we desire to order five degrees base out or five degrees base in, we can put the prism in either lens or we may distribute it $2\frac{1}{2}$ degrees base out—or base in, as the case may be—in each eye; or two degrees base out or base in in one eye and three degrees base out or base in in the other eye. In testing for hyperphoria we always record which eye has been tested—as, for instance, our record reads five degrees base up, left. If we desire to prescribe this prism entire, we insert it in the left lens; if, however, we desire to divide it, we order $2\frac{1}{2}$ degrees base up in the left lens, and $2\frac{1}{2}$ degrees base down in the right lens. If we had ordered $2\frac{1}{2}$ degrees base up in both lenses, one prism would have simply neutralized the other, and we would have had no correction of the vertical deviation, only a uniform downward displacement.

B. D. is a symbol for base down; B. U., for base up; B. I., for base in; B. O., for base out; R. stands for right, and L. for left.

The following is a form of prescription for a simple prism:

R., 2° prism B. O.

The following is the usual mode of combining a prism with the lens:

R., + S. 1.00 + C. 0.25 ax. 90

L., + S. 1.00 + C. 0.25 ax. 90

With prism 2° B. D., L. (i. e., base down, left); and prism 2° B. O., R. and L. (i. e., 2° base out in each eye).

Decentering spheric lenses produces a prismatic effect identical with the lens of the same strength combined with a prism. (Figs. 27 and 28.) The stronger the lens, the less decentering it requires to produce prismatic effect, and in cases in which it is desired to order a strong lens with a weak prism, decentering is of great value.

Rule.—To find the exact amount of decentering to produce a prismatic effect, we divide the number of centradts required by the strength of the lens in diopters. The quotient is the necessary decenteration expressed in centimeters. For example, to produce a prismatic effect of two centradts by means of a spheric lens of four diopters, it is necessary to decenter the lens $2 \div 4, \text{ or } .5 \text{ cm.}$

Neutralization of Prisms.—The apex of a prism may be determined by looking through it at fine lines crossed at right angles, or at the border of a card. Holding the prism so that its edge just touches one line at the point of intersection, we rotate the prism until the other line appears continuous through the prism and beyond it. The point of intersection in such case marks the true apex of the prism. The

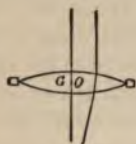


FIG. 27.

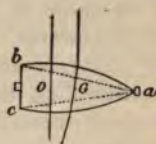


FIG. 28.

SHOWING THE PRISMATIC EFFECT OF DECENTERING.

The optic center O , in figure 27 coincides with the geometric center G . In figure 28, which represents a decentered lens of the same spheric curvature, O has been removed toward the base of the virtual prism b, a, c .—(After Maddox.)

strength of the prism is then ascertained by the prism with its apex pointing in the opposite direction that will neutralize the prismatic effect of displacement when looking at a distant object, such as the side of a picture-frame or a door jamb.

SPECTACLES AND EYE GLASSES.

The fitting of spectacles and eye-glasses is a most necessary adjunct to the art of ophthalmology. Spectacles should always have stout temple-pieces, to maintain their shape and stay in proper position by their weight. To prevent jarring while walking or running, the side-pieces should fit closely to the face and temples; in fact, it is sometimes preferable that they should exert sufficient pressure to slightly groove the skin. By this means a definite and fixed support is given. Fourteen-karat gold is to be preferred, and stout steel should be the second preference. Although silver does not rust, it can not be made of sufficient rigidity. Delicate wires, either of gold or steel, should not be accepted, as they can only maintain their position by uncomfortable pressure behind the ears and on the nose.

Spectacles are preferable to eye-glasses whenever there is astigmatism, or when the nose is not properly shaped for the ready adjustment

of eye-glasses. Hooks are to be preferred to straight temple-pieces when the glasses are to be worn constantly. Reading-glasses are sometimes more convenient with straight side-pieces, particularly in women, on account of the abundance of hair about the temples.

For constant use lenses should be slightly inclined at a compromise angle between the straight position and the inclination preferred for a reading-glass. Of course, the occupation of the patient must be taken into consideration in adjusting the glass.

In high defects the glasses should be fitted closely to the eyes and, if necessary, the lashes should be trimmed from time to time.

Glasses should be worn constantly in high defects, in astigmatism, and in all cases in which there are asthenopic or reflex symptoms.

Bifocal glasses are particularly valuable for a presbyope, or a high myope who is compelled to use a different glass for reading and for distance. The improved form, with a reduced curved segment cemented on the distance glass, is far more satisfactory than the old straight Franklin bifocals. The lower segment should be about 2 cm. wide, and the upper edge more curved than the lower. If the occupation of the patient subjects him to high degrees of heat or steam, the lower segment should be inserted into a groove in the bottom of the distance glass instead of being cemented on. Although it takes the patients some little time to become accustomed to bifocal glasses, they ultimately give far greater satisfaction and are more convenient than two different pairs of glasses.

Before discharging the patient, the adjustment of the glasses should be carefully examined and the correctness of the lenses verified by neutralization. The good effects of many a careful diagnosis of refraction are ruined by maladjusted and decentered glasses.

Tinted glasses of any kind should never be ordered for constant use, but only temporarily prescribed in inflammatory conditions, during mydriasis, for use at the seashore, etc. The habit of wearing tinted glasses once formed is difficult to overcome. Photophobia is usually due to uncorrected or improperly corrected ametropia. It is a well-known fact that tinted glasses are most used in countries in which the importance of eye-strain in comparatively low defects is unrecognized. When tinted glasses are ordered, it should be specified that London smoke plano lenses are wanted. Coquilles generally have some spheric or cylindrical effect on an irregular surface.

MYDRIATICS AND CYCLOPLEGICS.

Definition.—A mydriatic is an agent which produces dilatation of the pupil. A cycloplegic is an agent which produces paralysis of the ciliary muscle of the eye. In ophthalmology these two terms are usually considered interchangeable, as the ordinary drugs possessing the power of producing mydriasis, also produce in a more or less degree cycloplegia.

The mydriatics which have been used in the examination of the eye are atropin, belladonna, homatropin, cocain, hyoscyamin, duboisin, daturin, scopolamin, muscarin, mydrin, euphthalmin, and ephedrin. Atropin and homatropin are the drugs usually employed in refraction, and are the ones to be recommended, as they have been extensively used and their action and dangers are far better understood than those of the newer substances.

Physiologic Action.—Atropin and homatropin produce mydriasis by paralyzing the sphincter of the pupil and stimulating the dilator at the same time. Cocain affects the dilator of the pupil chiefly, stimulating it. Atropin paralyzes the ciliary muscle completely, and leaves the eye adjusted only for the far point. Homatropin paralyzes it less completely, but sufficiently for the purposes of refraction, when administered in the manner indicated. Cocain has a very slight paralytic action on the ciliary muscle. As usually administered, the effect of atropin lasts from ten days to two weeks; of homatropin, from one to two days; of cocain, only a few hours.

Indications in Refraction.—*In all first refractions of the eye of persons under forty-five or fifty years of age, in whom there is no suspicion of glaucoma.* No absolute diagnosis of the finer grades of astigmatism can be made without a mydriatic in a person possessing the power of accommodation.

Dangers.—These drugs may precipitate an attack of glaucoma in the eye of a person past middle life, or in whom there is already a tendency to increased intraocular tension.

It has been said that if a mydriatic ordinarily applied for purposes of diagnosis produces glaucomatous symptoms, the patient would likely have been the subject of insidious glaucoma later in life anyway, and that the early diagnosis by the mydriatic facilitates treatment.

Mydriatics may also cause general toxic symptoms in susceptible patients. The general symptoms are tickling and dryness in the throat, vomiting, diarrhea, redness of the face, and quick and irregular pulse; even fatal cases have been recorded. If there is any history of idiosyncrasy, the patient should always be instructed to press the finger against the lacrimal sac for ten minutes after using the drops. This danger may also be averted by using minute or divided drops of the solution. Congestion of the conjunctiva is often a temporary result of the instillation of a mydriatic. The systemic effects of a mydriatic may be combated with a full dose of paregoric.

Administration.—The most effective of this class of drugs, and that most frequently used, is the sulphate of atropin. A solution of one grain to two drams is ordinarily prescribed; one drop of this strength solution is placed in each eye three times daily for two days prior to the examination. An additional drop is generally applied at the office of the oculist before beginning the examination. For the reason of its prompt action and the short duration of its effect, the hydrobromate of homatropin offers a very efficient and necessary substitute for atropin in office practice. It is, however, a much more expensive drug than the sulphate of atropin. The best solution is a mixture of two-thirds hydrobromate of homatropin, ten grains to the ounce, and one-third hydrochlorate of cocain, ten grains to the ounce. A drop of the mixed solution is instilled in each eye every ten minutes for an hour preceding examination. If it is necessary to have repeated examinations of the eye or to have prolonged mydriasis, atropin should be invariably used. Cocain is useful to dilate the pupil to facilitate ophthalmoscopic or retinoscopic examination, but is valueless as a cycloplegic. The four per cent. solution is generally used. Sufficient dilatation is usually obtained in from fifteen to thirty minutes.

Hyoscyamin, duboisin, daturin, and scopolamin are sometimes used, but investigation has not yet definitely established reason why they should be preferred to the older drugs. These and the rarer mydriatics are further described in the section on Local Ocular Therapeutics.

AMETROPIA.

HYPEROPIA.*

Synonyms.—Hypermetropia, far-sightedness.

Definition.—A condition of the refraction of the eye in which, when the accommodation is at rest, the focus of parallel rays of light transmitted through the eye is beyond the retina.

Causes.—Hyperopia may be due to a lessening of the convexity of the refracting surfaces of the eye (*hyperopia of curvature*), change in the index of refraction of the dioptric media, or absence of the crystalline lens (*aphakia*). It is, however, most commonly due to a shortening of the anteroposterior axis of the eyeball (*axial hyperopia*).

Hyperopia may be looked upon as arrested development. Animals are, as a rule, highly hyperopic; and savages are, as a rule, more or less so. Children are usually hyperopic, and become emmetropic or even myopic while growing to maturity. Properly speaking, hyperopia is a failure of the modern eye to properly adapt itself for its uses in modern civilization. Hyperopia is often hereditary.

The results of hyperopia on the ciliary muscle are quite noticeable. Excessive contraction produces abnormal development, particularly of the circular fibers, which become greatly in excess of the radial fibers. The continuous contraction may lead to tonic spasm, which is very difficult to overcome, and renders refraction without thorough mydriasis most unreliable.

Axial Shortening in Hyperopia :

<i>H. in D.</i>	<i>Axis in Mm.</i>	<i>Diminution in Mm.</i>
0	22.824	0.00
1	22.51	0.31
2	22.20	0.62
3	21.90	0.92
4	21.61	1.21
5	21.32	1.50
10	20.04	2.78
15	18.91	3.91
20	17.92	4.90

* Although in ordinary practice it is the rule to find the simpler forms of ametropia associated with at least a small amount of astigmatism, for convenience astigmatic defects will be considered separately.

Disadvantages.—Parallel rays of light do not focus on the retina, but form circles of diffusion and hence a blurred image. Divergent rays impinging on the cornea form still larger circles of diffusion on the retina. The only rays that can focus exactly on the retina and give a distinct image are those rendered convergent to a certain degree by convex lenses. The eye contains a mechanism for overcoming its hyperopic defect. In order to render the rays more convergent, the anterior surface of the lens is made more convex by the continuous contraction of the ciliary muscle. In this way hyperopia, up to a certain point, varying with each individual, is involuntarily corrected. However, we can readily realize the result of a constant strain on the ciliary muscle. Nervous energy is consumed and the nervous equilibrium is disturbed, with the result not only of annoying local symptoms of pain, fatigue, and congestion, but more remote reflexes, such as headaches, gastrointestinal disturbances, and many general neurotic disorders. As the correcting effort of the ciliary muscle is involuntary, the resultant annoying symptoms of eye-strain can only be relieved by atrophy or paralysis of the muscle, or correction of the defect which necessitates the ciliary contraction.

Varieties.—**Manifest**, which is measured by the strongest spheric lens which, without mydriasis, gives the greatest acuity of vision. **Latent hyperopia** is that part of the total error which can only be revealed by mydriasis, as it is at all times masked by the accommodation. The younger and more vigorous the subject, the greater the amount of latent hyperopia. It is on account of the ever-present latent hyperopia in the eyes of persons younger than fifty years, that it is necessary to paralyze the ciliary muscle in order to measure the full degree of hyperopia. The old classification of *facultative*, *relative*, and *absolute* hyperopia is too vague to be used.

Symptoms.—The objective symptoms are inconsiderable. The leading subjective symptoms are caused by the strain upon the accommodation, and may be grouped under the heading "accommodative asthenopia." The patient will complain of inability to perform continuous near work: the letters and words are indistinct and seem to run together. Headaches and pains about the eyes are present. There is increased lachrimation and tendency to chronic congestion of the conjunctiva. The local reflex symptoms may range from a slight palpebral conjunctivitis to intense blepharitis and even granular lids. There may be such intense photophobia as to cause suspicion

of retinal disease. The remote systemic reflexes, such as headaches, nausea, indigestion, general neurotic disturbances, etc., are too numerous to be discussed here.

The distant vision is usually good, as the ciliary muscle is capable of overcoming a moderate defect. Hyperopia of a high degree, or complicated with astigmatism, markedly diminishes real acuteness.

There is an intimate connection between convergent strabismus and hyperopia. It is likely that the associated movements of accommodation and convergence are controlled by the same center, or by contiguous centers, acting automatically from long association. The increased strain on the accommodation causes extra innervation to convergence, which may result in permanent squint inward. Or, again, persistent stimulation of the adductors may weaken them and thus produce divergent squint. Very often if a child is hyperopic to some extent, and unequally in the two eyes, to avoid the discomfort of a blurred or double image one eye is turned in and becomes amblyopic. It has been estimated that over three-fourths of the cases of convergent strabismus are caused by hyperopia. We, therefore, see how very necessary it is to examine carefully the refraction of an eye beginning to converge in a child.

Hyperopia increases with age, on account of the lessening of the refractive power of the lens caused by a change in its substance. At the age of eighty this lessened refractive power is quite apparent.

Diagnosis can be made with certainty only by the use of a mydriatic, although failure of accommodation and recession of the near point incommensurate with age give strong reason to suspect hyperopia. The most important point in the diagnosis is the acceptance of a convex lens, and we usually estimate the full degree of hyperopia by the convex lens which gives the eye under complete mydriasis the best vision with the test-cards at six meters.

In the higher degrees of hyperopia the patient must choose between a small, more or less distinct, and a larger blurred image. As a rule, his choice is the latter evil, and to this end he will hold his book or instrument very close to his eye, simulating the action of a myope. In addition, the high hyperope complains of inability to see distinct objects, which makes another point of confusion with myopia. In casual examination of hyperopia with ciliary spasm, a weak concave glass may be accepted with relief. However, all confusion with myopia may be avoided by thorough mydriasis.

Besides the test-lenses, hyperopia is diagnosed and the degree estimated by the ophthalmoscope and the retinoscope in the manner described in the sections relating to these instruments.

The treatment of hyperopia consists in prescribing correcting lenses. Having estimated the degree of defect, several points must be taken into consideration in prescribing glasses. It is taken for granted that the patient has been thoroughly under a mydriatic during the preliminary tests. When he comes back to our office for a prescription, it very often happens that we find at the postmydriatic examination that a hyperope of a slight degree will not accept any of his correction, either for reading or for distance. In such case, if anisometropia is not present and if the patient has complained of no asthenopic symptom and is apparently vigorous, we do not prescribe a glass, but tell him of his defect, and warn him of the ultimate results of eye-strain, and urge him to come back at the first sign of trouble. It more often happens that a certain proportion, or even a full correction, is accepted for reading, but all correction is rejected for distance; in such case, if there is no prominent asthenopic reflex, we only prescribe a reading glass.

Prescription of glasses in hyperopia is a most important subject. No definite and dogmatic conclusions or rules are applicable in every case. We must study each case separately and be influenced by the degree of defect, the muscle-balance, the age of the patient, the constitutional condition, the asthenopic symptoms, and the occupation or habits of the patient.

It is very often necessary in young people with strong accommodation to make considerable deduction from the full correction in order to obtain sufficient distant vision. Young and vigorous adults who have never worn glasses will not accept their full correction. In such cases we must be governed by our judgment. As a general rule, we try to prescribe the highest convex lenses which allow sufficient distant vision; these are usually readily accepted for near work. If the patient is engaged in continual near work and complains of marked asthenopic symptoms, we order, for near vision, a large share of the full correction, and consider it advisable to blur slightly the distant vision. We must explain to the patient that such glasses will not be satisfactory at first, but that the eye will gradually become accustomed to them, and that the glasses were not ordered to improve the distant vision, and may diminish it at first, but that the point in

consideration is to effect easy near vision, and to avoid eye-strain and its distressing consequences.

In cases of very high defect with enormous accommodative power weak lenses are at first ordered, and these are strengthened at short intervals until the full correction is approximated. It is surprising to note the rapidity with which the eye will accommodate itself to what was at first an unacceptable correction.

The muscle-balance must always be tested before ordering glasses. In cases of orthophoria or exophoria we must reduce the correction in hyperopia to force the interni into action. The ideal hyperopic muscle-balance in most office patients is about two degrees of esophoria with the Maddox rod, or orthophoria with the Stevens phorometer. Cases of higher esophoria need a strong correction.

In presbyopia and in other cases in which a mydriatic has not been used we endeavor to order the full strength of the manifest refraction.

A final point is the influence of avocation. We readily see that the musician and artist, to obtain the best acuity and accommodation at their working distances, will require a different correction from that of the copyist and engraver.

MYOPIA.

Synonyms.—Near-sightedness, short-sightedness, brachymetropia.

Definition.—A condition of the eye in which parallel rays of light are brought to a focus in an eye at rest in front of the retina. It is most often dependent on the lengthening of the axial diameter of the eye, and such cases are called *true* or *static* myopia. A *false* or *functional* myopia is produced by spasm of the ciliary muscle, conic cornea, swelling of the lens in incipient cataract, etc. In such cases the sclera is of usual thickness and the axis of the eyeball is not lengthened; the change is in the refractive media.

Axial Lengthening in Myopia :

<i>Myopia in D.</i>	<i>Length of Myopic Eye.</i>	<i>Increase in Length</i>
	<i>mm.</i>	<i>mm.</i>
0	22.824	0.00
1	23.14	0.32
2	23.48	0.66
3	23.83	1.01
4	24.19	1.37
5	24.56	1.74
10	26.62	3.80
15	29.10	6.28
20	32.13	9.21

Causes.—It is rarely congenital, and, when so, it may be hereditary. An anatomic cause is said to be the peculiar construction of the orbit in certain people.

Devascularization and weakened resistance of the ocular tissues are predisposing causes. Scrofulous children are ready victims to myopia. The early necessity for increased convergence and accommodation by the precocious application of hyperopic eyes of childhood to continuous near work produces a hyperemia of the ocular tissues, which if of low resisting power are stretched, the eye gradually becoming lengthened, and, as a result, myopic. Myopia is often seen in persons of intellectual pursuits requiring excessive near work, such as students, artists, engravers, etc. However, in the congenital and hereditary types, the patients may be of the most ignorant classes of mere manual laborers. In such cases a low-grade choroiditis is an important etiologic factor. Myopia rarely results from an increased refractive power of the lens in the early stages of cataract in old persons, and to this fact may be possibly attributed the cases of so-called "second sight," in which aged persons find themselves able to read again without their convex lenses. However, their distance vision becomes markedly decreased.

The entire eyeball is not necessarily involved in myopia—as, for instance, myopia results from the condition known as conic cornea, the relation between the retina and other media being normal.

An occasional and a curious cause of myopia is a marked decrease in weight of an extremely stout emmetrope or a low degree hyperope. In a like manner we have noticed considerable decrease of myopia in persons who suddenly and markedly increase in weight.

Disadvantages and Dangers.—The axial diameter being too long, the parallel rays of light falling on the eye focus in front of the retina, and hence only a blurred image of external objects is received on the rods and cones. In moderate hyperopia a similar defect is overcome by the accommodation, but the myopic eye possesses no mechanism adapted to the correction of the refractive error. There is no way of diminishing the refractive power of the dioptric system, and hence distant objects are always blurred. There is false estimation of size and distance, and altogether the myope is at a decided disadvantage in sports or occupations. However, the myope is still able to see near objects distinctly, and unfortunately therein lies his greatest danger. Deprived of many out-door pleasures, he seeks

occupation and amusement within his own limited circle of vision. By holding his book or implements close to his eye, he is able to see distinctly; but in so doing he strains his power of convergence excessively, producing ocular congestion and compression of the eyeball; and by bending over he affords a favorable position for the distention of the ocular veins. The coats of the eyeball, already of weakened resistance and put upon the stretch, are further pulled and damaged. The eyeball becomes more and more lengthened, and the myopia increases. With the stretching of the ocular coats the nutrition of the eye is seriously disturbed, and, as a result, the choroid becomes diseased, and this causes associate retinal changes, defective vision, even with proper glasses, resulting. The nutrition of the vitreous and lens is also seriously damaged. The consequences of this denutrition in the highly myopic eye are serious, and such eyes are liable to cataract, vitreous opacities, and retinal detachment. The danger is, of course, greatest in youth.

Contrary to the popular impression, the myopic eye should be considered as a "sick eye." However, if proper glasses are prescribed and constantly worn and excessive near work interdicted, a moderate degree of myopia *unaccompanied by posterior staphyloma* is not liable to progress, but will remain more or less stationary through adult life. This again offers another argument for the early correction of myopia.

Another danger of excessive convergence in a myopic child is *divergent squint*. The strain in excessive convergence, necessitated by the diminished distance for near work, and extra effort to rotate the elongated eyeballs, may be so great that the effort to converge both eyes is finally relinquished, and one eye diverges.

A final danger of myopia is the liability to accidents on account of the inability to see distant objects clearly.

Progressive or malignant myopia is the serious type in which the ocular coats continue to stretch and become devitalized until they ultimately give way. The bulging occurs at the weakest portion near the posterior pole, to the temporal side of the disc, and constitutes what is known as *posterior staphyloma*. The destruction of the choroid is accompanied by many conditions which are readily recognized through clear media with the ophthalmoscope. The *myopic crescent* (C, Fig. 29) is caused by the absence of the pigment of the stretched choroid and retina, usually at the nasal margin of the

disc, allowing the sclerotic to show through as a white crescent. Other white spots indicative of chronic choroiditis may be seen scattered throughout the fundus. Hemorrhages and extravasations sometimes produce retinal detachment. In extreme cases the vitreous becomes fluid and the eyeball soft. Vitreous opacity and luxation of the lens may result. With such serious sequels we readily see that the ultimate result of unchecked malignant myopia may be disorganization of the whole eye and total blindness; and in all cases of high myopia, whether progressive or stationary, there are pathologic changes of such import as to produce more or less amblyopia.

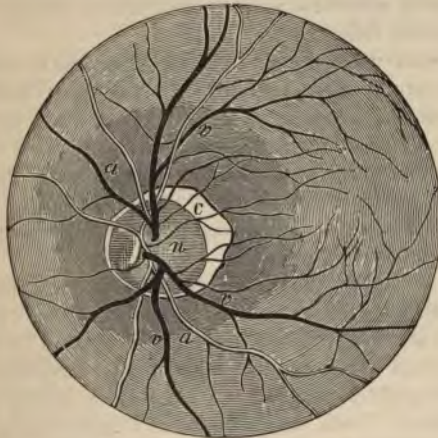


FIG. 29.—MYOPIC CRESCENT.

Symptoms.—The objective symptoms in the lower grades of myopia are of little importance. In the high degrees the eyeballs may be prominent, and when strongly converged are seen to be elongated. In such cases the pupils are large and inactive. The myopic crescent and the choroidal condition help the diagnosis.

The most noticeable subjective symptom is the interference with vision. In moderate myopia distant objects can not be seen distinctly. Myopic children complain that they can not see the clock across the room or distinguish writing on the blackboard at school, although they are able to read at close range with apparent ease. In

extreme cases of myopia or in the progressive type the far point is so close to the eye as to render the eye virtually useless for distant vision. Scotomata, limitation of the visual field, vitreous opacities, photophobia, photopsia, muscæ, and ocular pains are additional symptoms of the higher degree of myopia.

As a rule, the symptoms of accommodative asthenopia and the remote reflex irritations from eye-strain are not complained of in myopia, as the ciliary muscle is passive rather than active. Its radial fibers are better developed and are greatly in excess of the circular fibers, the opposite of the condition in hyperopia. However, because of the strain on the convergence, evidences of muscular asthenopia, such as headache, weariness and sense of heat in the eye, and chronic conjunctivitis may follow.

Diagnosis rests upon the diminished acuteness of distant vision, the ophthalmoscopic examination (refraction and fundus-changes), the retinoscopic examination, and the acceptance of and visual improvement by a concave lens. Conic cornea is easily differentiated from myopia by the peculiar protruding appearance of the cornea, the depth of the anterior chamber, and the characteristic retinoscopic reflex. Hyperopia with ciliary spasm simulating myopia is readily differentiated under mydriasis.

Treatment.—Prophylactic measures consist in the careful examination of children's eyes, particularly about the time they are to start to school, and in securing the best hygienic conditions for them during their school hours. Good ventilation, properly-constructed desks, and sufficient and rightly directed light are requisites for the maintenance of normal vision. There should be a north light coming in over the left shoulder, and not falling directly on the desks. The walls and ceilings should be painted in light colors. There should be one foot of window space for every five feet of floor space, and small type should be distinctly read in the most remote corner of the school-room on a cloudy day. Books should be printed in large, broad-faced type and on dull-faced paper. The desks should be sloping and so arranged as to avoid all stooping positions. In young myopes excessive near work must be interdicted. Such children should be urged to forego studying, reading, and other in-door amusements, and must be encouraged to go out into the open air and take plenty of healthful exercise, meanwhile rigorously wearing their correcting glasses.

In myopia the book, writing, etc., should be placed at a distance of

at least 13 inches from the eye, artificial or insufficient light should be avoided, and the eyes should be given frequent intermissions of rest.

In the progressive type of myopia, and in the extremely high degrees, near work must be virtually excluded from the daily occupation. In such cases the treatment depends upon rest, abstinence from near work, constitutional and hygienic measures, the relief of any increased ocular tension by the administration of eserin, or iridectomy, attention to the associate choroiditis and other pathologic changes, and the constant use of correcting lenses.

Prescription of Glasses.—Ordinarily, it is desirable to prescribe spectacles that will give fair distant vision and, at the same time, enable the patient to read easily at the proper working distance. However, in cases of persons doing much near work, a pair of weak lenses may be ordered for reading, etc., and stronger glasses for outdoor use, theaters, receptions, etc.

In myopia of three diopters or over the far point is inside of the ordinary reading distance, and there is necessarily extra convergence; but unfortunately there is no necessity for accommodation; the adductors are deprived of this stimulus, and exophoria results. In order to cause the requisite accommodative stimulus to the adductors, constant use of the full correction of myopia has been urged. The theory of this is plausible, but the strain on the undeveloped accommodation is too severe and serious asthenopia results. We unfortunately find that most myopes complaining of unsatisfactory glasses are wearing not only their full correction, but are, in a majority of cases, overcorrected. A myope will naturally select a strong lens, and we should be cautious in the trial with the test-lenses, and accept as the proper refraction the weakest lens which gives normal vision, and which does not diminish the size of the letters, and, as the patients so often say, makes them seem better but farther away.

In prescribing glasses for constant use, some deduction from the full correction should be made in cases of children and young adults, in order that compromise lenses may be continually used which give fair distant vision, but which necessitate only a moderate accommodative effort in reading. It must always be remembered that overcorrected myopia may produce as distressing symptoms as uncorrected hyperopia.

At the presbyopic age bifocal lenses should be constantly worn and the full distance-correction ordered in the upper segment. In

the high degrees of myopia (above six to eight diopters) the full correction is never tolerated. In the unfortunate cases of extremely high myopia (12 to 20 diopters), with extensive choroidal changes, glasses are often of little service in making a useful working eye, and are so bulky and heavy as to be uncomfortable.

Removal of the Lens for High Myopia.—It is a well-known fact that the removal of the crystalline lens makes an emmetropic eye hyperopic by about 12 or 13 diopters. In the knowledge of this fact it has been suggested that removal of the lens would be an advisable procedure in cases of extremely high myopia—for instance, of from 15 to 20 diopters. Although this operation has been performed quite a number of times recently, the actual practical results are not definitely settled; there is great danger of retinal detachment, and, moreover, it is too radical a treatment to be advised to the beginner in ophthalmology. An ideal indication for this operation would be lenticular myopia.

ASTIGMATISM.

Definition.—An error of refraction usually due to some irregularity of the curvature of the refracting surfaces of the eye. The cornea is most often the faulty structure, but lenticular astigmatism is not uncommon; in fact, it is said that all eyes possess some irregular astigmatism in the lens, and for this reason a point of light at a great distance is not seen as a point, but as a star. However, it must be remembered that light coming from the heavens travels through media of different refractive powers. In simple myopia or hyperopia, while the refraction is faulty, the corneal meridians are all of equal curvature. In astigmatism the curvature of the meridians is different; one principal meridian may be of proper curvature while the other is markedly defective. It must be remembered that astigmatism does not depend upon the length of the globe, but upon the curvatures of the cornea and lens.

Varieties.—Regular astigmatism is present when the two principal meridians—*i. e.*, those of greatest and least curvature—are at right angles to each other.

Irregular astigmatism is a condition in which the unequal curvatures of the cornea bear no definite relation to each other. There are no principal meridians, and different parts of the same meridian may have different refractive powers. This form of astigmatism is

usually due to cicatrices of the cornea following injuries, surgical operations, or destructive inflammations. If the cornea is clear and apparently regular, we are safe in attributing irregular astigmatism to a difference in the refractive power of the different sectors of the lens, or to its oblique position.

Causes of Regular Astigmatism.—As previously stated, the chief factor in the production of regular astigmatism is imperfect curvature of the cornea. Regular astigmatism may be congenital or hereditary. Congenital malformation of the cornea may be a part of a general anatomic defect in the bones of the face and skull.

The causes of acquired regular astigmatism are not exactly understood, but as almost every person is slightly astigmatic, we must say that among civilized nations regular curvature of the corneal surface is the exception rather than the rule. However, the excessive use of the eyes in modern life is attended by so much muscular and accommodative effort that we may readily believe that both tension and torsion on the coats of the eyeball by the muscles are prime factors in the meridional change in corneal curvature. Pressure of the lids, particularly in ametropia and when they are hypertrophied and uneven after some marked conjunctival inflammation, is often suggested as a cause. Finally, after operations on the cornea or sclera, the subsequent changes during cicatrization may produce a high degree of astigmatism.

Explanation of the Several Varieties of Regular Astigmatism.—Ordinary refraction through a perfect dioptric system causes rays of light from a point to be focused as a point. When, however, there is meridional difference of curvature, the point of light appears as a group of lines. If the surface bounding one meridian is more curved than that bounding the other meridians, the rays of light impinging on this surface will be focused sooner than those striking the less curved meridian.

If a cone of light passing through a regularly convex spheric surface corresponding to the normal cornea be divided perpendicular to its axis, either at a point in front of its focus or after the rays have crossed and are divergent behind the focus, a circle is formed. If, however, the parallel rays passing through a convex spheric surface are refracted more in the vertical than in the horizontal meridians, the resulting cone will be more or less ovoid, and form a circle only when the rays of the vertical meridian, diverging after focusing, cross

the converging rays of the horizontal meridian, not yet focused, on the intersecting plane. (Fig. 30, line 4.)

In figure 30, V V are rays impinging on the vertical meridian, and H H are rays striking the horizontal meridian; V V are brought to a focus at the line V 2, while H H are not focused until they reach the line H 6. If we suppose the intersecting lines 1 to 7, dividing the

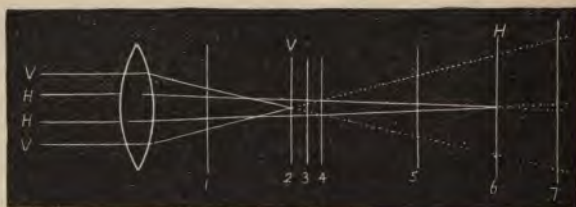

FIG. 30.

rays, to represent the retina in different forms of ametropia, instead of forming a circle, the resultant cones will be similar to the geometric figures represented in figure 31. Instead of distinct images, the result is circles of diffusion and blurred outlines.

The several possible combinations in the differences of refraction of the principal meridians give rise to the five varieties of regular astigmatism.

Simple hyperopic astigmatism is the form in which one meridian

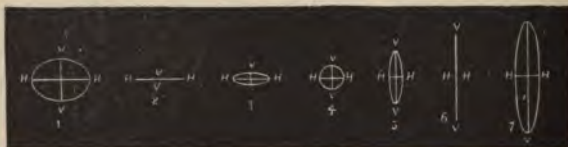


FIG. 31.

is emmetropic and the other hyperopic. If we presume line 2 to be the retina, it is obvious that for rays passing through the vertical meridian V V it is emmetropic, while the rays through the horizontal meridian focus behind the retina,—i. e., they would cause a hyperopic refraction,—and a horizontal straight line is formed.

Simple myopic astigmatism is a form in which one meridian is emmetropic and the other myopic. If the retina be supposed at line 6, the horizontal rays focus directly upon it, while the vertical rays focus in front of it; *i. e.*, they would produce a myopic refraction. The image is a larger and longer vertical straight line.

Compound hyperopic astigmatism is a form in which both meridians are hyperopic, but one more so than the other. If the retina is at line 1, both sets of rays have their focus behind, and an oblate oval is formed.

Compound myopic astigmatism is a form in which both meridians are myopic, though unequal in degree. If the retina be at line 7, both sets of rays focus behind it, and the resultant image is a large prolate ellipse.

Mixed astigmatism is a variety in which one meridian is hyperopic and the other myopic. If the retina be at lines 3, 4, or 5 (Fig. 30), the vertical rays will focus in front and the horizontal rays will focus behind, and the images 3, 4, or 5 in figure 31 are formed.

Astigmatism with the rule is a term given to cases of hyperopic astigmatism with the axis in or near the vertical meridian, and to cases of myopic astigmatism with the axis in or near the horizontal meridian.

Astigmatism against the rule is the reverse of foregoing condition.

Symmetric astigmatism is the usual form in which the axes of the two eyes added together make exactly 180—as, for instance, R. axis 30, L. axis 150; or, R. axis 180, L. axis 180 (in this case one of the axes in the left is taken as 0).

Unsymmetric astigmatism is the troublesome form in which the two axes collectively do not make 180—as, for instance, R. axis 130, L. axis 40; or, L. axis 180, R. axis 140. This form is a prolific cause of asthenopic symptoms.

Disadvantages.—An astigmatic eye sees a point as a line; hence images are distorted and marked visual disturbance results. It is believed that there is an involuntary effort on the part of the ciliary muscle and even the external muscles to remedy the astigmatic defect. By constant unequal contraction the ciliary muscle partly compensates for moderate inequalities in the curvatures of the cornea. Such continuous and unequal accommodative effort must result in eye-strain, and consume much of the normal nervous energy, eventually producing reflex manifestations of disturbance of the nervous equilib-

rium. Therefore, an astigmatic person may be able to improve his vision only at the expense of his health. Uncorrected astigmatism, particularly in delicate and nervous women, results in the worst forms of reflex asthenopic symptoms.

Symptoms.—Nearly every person consulting us for refraction is more or less astigmatic, and in the majority of cases part of the astigmatism is masked by the accommodative effort of the ciliary muscle. Under this natural correction the visual acuity is more or less undisturbed, and in the moderate degrees of astigmatism the reflex symptoms are the most prominent signs. The patient complains of headache, nausea, anorexia, indigestion, inability to perform continuous near work, etc. In reading, the letters often fade and seem to run together. There is significant confusion of such letters. Commonly there will be noticed an inclination of the head

to one side, the patient saying that he can see better with his head in that position. In very high degrees of astigmatism the pupil may be oval, and the asymmetry of the cornea may be detected by simple inspection.

From the preceding remarks as to the involuntary correcting action of the ciliary muscle, the use of a mydriatic in determining the full degree and correct axis of the astigmatism is seen to be necessary.

Tests for astigmatism are very numerous; there are a dozen or more valuable methods of qualitative and quantitative diagnosis of astigmatism. The astigmatic cards and dials, the stenopaic disc, and the keratoscope furnish us easy methods for simple diagnosis, while the ophthalmoscope, ophthalmometer, retinoscope, and test-lenses are valuable methods for the more exact determination of the kind and degree of astigmatism. Besides these tests we have the perforated chimney disc, the cobalt glass, etc.

The diagnosis of astigmatism by the ophthalmoscope, by the retinoscope, and by the test-lenses has been described in the sections dealing with these special instruments, and in the following lines we shall attempt to describe only instruments especially designed for the detection of astigmatism.



FIG. 32.—ASTIGMATIC CHART.

Astigmatic cards and charts are of several varieties. Snellen's cards consist of a series of equally colored dark lines arranged like the spokes of a wheel, with the angle of inclination of each line marked opposite to it. (Fig. 32.) Seated at six meters and looking at this card, an astigmatic person sees clearest the lines corresponding to his principal astigmatic meridian, and sees poorest the lines at right angles to it. Another form is the arrangement of lines similar to a clock-dial; the numbers of the clock are used to indicate the chief meridians, as these are so well known by the patient and can be easily indicated by him to the physician.

Pray's astigmatic letters (Fig. 33) are formed of equally black lines inclined at different angles. The letter seen the blackest is the one formed of lines at an angle corresponding to the axis of the patient's astigmatism. Many other forms of cards and charts have been suggested.

The stenopaic disc consists of a round disc of metal or hard rubber containing in one of its diameters a fine linear slit-like opening. It is mounted in a test-lens cell for use in the trial-frame. One eye is excluded from vision with an opaque disc, and the disc is placed before the other. The patient is directed to look at the test-letters or astigmatic chart. The stenopaic disc is then rotated in the trial-frame until it reaches the position in which the letters are seen

most clearly, or in which the lines on the chart are of nearest equal distinctness. The angle marked on the trial-frame corresponding to the inclination of the slit indicates the least defective meridian, and also the axis of the necessary correcting cylinder, as such a cylinder would correct only the defect of the meridian at right angles to its axis (the most defective meridian). The convex or concave glass that gives the best vision is put down as the refraction of the first meridian. The slit is turned exactly 90° , and the second meridian is similarly refracted. If both meridians are hyperopic or myopic, the refraction of the first meridian represents the spheric defect, and the difference is the cylindrical defect at the axis of the first meridian. If the slit is preferred in the vertical meridian (axis 90°), and the




FIG. 33—PRAY'S ASTIG-MATIC LETTERS.

refraction of this meridian is + 1.00 D., and the refraction of the horizontal meridian (axis 180°) is + 2.00 D., the defect would be expressed thus: + S. 1.00 + C. 1.00 ax. 90.

If the refraction of the first meridian is myopic, say, - 1 D., and the refraction of the 180 meridian, hyperopic, say, + 2 D., the defect could be expressed either - S. 1.00 + C. 3.00 ax. 90, or + S. 2.00 - C. 3.00 ax. 180. The first would be the better formula to use, as the meridian of least defect is generally taken for the spheric correction.

The stenopaic disc furnishes a simple means of refracting astigmatic eyes, but it is not always accurate. It is of greatest value in cases of mixed astigmatism. It has the advantage of not requiring cylindrical lenses in refraction.

A ready means of detecting astigmatism is the application of a low power cylinder before the eye, which if preferred in any special axis gives a strong reason to suspect astigmatism in that axis or at right angles to it. Indeed, after the acquirement of considerable expertness no device except the test-lenses and the test-letters are required for the accurate diagnosis of astigmatism, with paralyzed accommodation, swinging the cylinder 10° or 20° readily locates the precise axis even in low degrees of defect.

A keratoscope is an instrument for examining the cornea and testing the symmetry of its meridians of curvature. Several forms have been devised, such as the **Wecker-Masselon**, which is a black board 18 cm. square, bordered by a white stripe about 15 mm. broad. Through a hole in the center, the image of the white frame is seen reflected on the cornea. By turning the board on its handle the white frame will take a position from which a rectangular image is reflected. When this position is found, we have the direction of the principal meridians in an astigmatic cornea. If the mirror is held in any other direction, a rhomboid image of the retina is seen. The degree of astigmatism is found by comparing the size and shape of the image with a series of rectangles printed on an accompanying card, showing the appearance of the corneal image in astigmatic conditions from 0 to 10 D.

Placido's disc is a white disc about ten inches in diameter, upon the surface of which are painted concentric black rings one inch apart. The observer looks through a hole in the center of this disc and notes the appearance of the image of the rings that is reflected

upon the patient's cornea. The image is elliptic or distorted, according as the astigmatism is regular or irregular. In emmetropia the rings appear circular.

A ready method of keratometry is to place the patient in front of a window having several panes of glass in it, and observing the appearance of the image of the sash on the patient's cornea. The lines are curved or irregular if astigmatism is present.

The ophthalmometer (Fig. 34) is an instrument used for the determination of the kind and amount of corneal astigmatism. It is less exact than the retinoscope, and, moreover, it is very expensive. That of Javal and Schiötz consists of a telescope attached to a graduated arc, upon which are two objects called mires, the left one being fixed, while the right is movable. These mires are white enamel, one quadrilateral in shape and the other the same size, except that on one side it is cut out into five steps. The observer looks through the tube, which contains a combination of convex lenses and a birefracting prism, and sees four magnified images in a line on the cornea under examination. He first finds the meridian of least refraction by moving the semicircular arm to the position in which the two central images are farthest apart. The mires are then moved together until the two central images on the observed cornea touch and their central black lines coincide, the lowest step of one image with the side of the other. The arm is now turned at right angles to this meridian, and we notice the overlapping of the two central images; for each step overlapping there is a difference of one diopter between the meridians. In higher degrees of astigmatism we add five diopters to the number of steps protruded on the other side. At five diopters of astigmatism the steps exactly cover the plain quadrangular mire.

The meridian of least curvature corresponds to the axis of astigmatism. The findings of the ophthalmometer are not exact. No account is taken of the lenticular astigmatism, and even though the cornea is at fault, no rules for adapting the ophthalmometric results can be formulated. Speaking broadly, the total astigmatism is approximately equal to the amount indicated by the ophthalmometer, expressed as myopic astigmatism, combined with an *inverse* myopic astigmatism of 0.75 D.; or, in other words, when there is no corneal astigmatism by the ophthalmometer, the test-lens will likely show about 0.75 D. of inverse astigmatism (Bull).

Treatment of regular astigmatism consists in using the proper cor-



MIRES EXACTLY APPROXIMATED.



MIRES OVERLAPPING ONE DIOPTR.




FIG. 34.—THE OPHTHALMOMETER OF JAVAL AND SCHIÖTZ.

- A.* The perimeter-bar. *B, B.* Telescope. *C.* Chin-rest. *D.* Disc of radiating lines and concentric circles. *E.* Eye-piece, at which the observer sits. *H.* Head-rest. *L.* Lights. *M, M.* The mires, or targets. *P.* Pointer, indicating the axis by the degree numbers on the peripheral border of the disc.

recting glasses. The full astigmatic correction should be ordered, and in the compound or mixed forms, combined with the spheric correction. If the degree of defect is high, or if there are symptoms of accommodative asthenopia, the glasses should be worn constantly. Sometimes in cases of simple hyperopic astigmatism of high degree, it is necessary to order —S. 0.25 or 0.50 in addition to the cylinder, to enable the patient to see at a distance. This is particularly the case with first glasses. We should generally urge the patient to wear spectacles, as eye-glasses are continually getting out of shape, and we can never be sure that the glass is applied to the eye at the proper axis. In very sensitive eyes the slightest tilting of the axis of the cylinder is provocative of the most disagreeable asthenopic symptoms, and often a proper glass wrongly adjusted will aggravate the condition.

Treatment for irregular lenticular astigmatism is worthless. For irregular corneal astigmatism, generally due to a corneal cicatrix, stenopaic glasses—*i. e.*, discs having small openings in the middle to prevent the rays of light from being received on any but an extremely limited corneal area, the curvature of which may be regular—have been used. However, the field of vision is so limited in these cases that the glasses are of little value. By patiently applying the test-lenses to an irregularly astigmatic eye, we can sometimes find a cylindrical combination which at a particular axis seems to improve the vision.

PRESBYOPIA.

Synonym.—Old-age sight.

Definition.—A condition of the eye in which the power of accommodation is either partially or wholly lost by age. Properly speaking, presbyopia implies diminution of the accommodative power in adults past middle life, to such an extent as to interfere with near vision. Presbyopia usually occurs between forty and fifty years of age. As a hyperopic eye is obliged to exert a portion of its power of accommodation to overcome its refractive error, it necessarily has less accommodative power in reserve, and consequently becomes presbyopic sooner than an emmetropic or myopic eye. An uncorrected myope may never exhibit the signs of presbyopia, as he can read at his far point, but if he wears a distant correction, he will have the same need

for a reading glass about the presbyopic age as the emmetrope or hyperope.

Cause.—The direct cause of presbyopia is the diminishing elasticity of the lens simultaneously with the solidification and sclerosing conditions which take place elsewhere in the body with advancing age. As a consequence of the changes in the lens-structure, it gradually loses its power to become convex, and hence to refract diverging rays from a near point so that they will meet directly on the retina and give a clear image. This diminution in the refractive power of the lens is physiologic, and when it has advanced to such a point that rays at the average reading distance—about thirteen inches—are no longer refracted exactly on the retina, presbyopia is said to have commenced.

Notwithstanding the fact that each patient should be studied individually, and no arbitrary rules can be constructed by which we can estimate the relative range of accommodation to age, for convenience it is desirable to have the following tables in the mind in refracting presbyopes:

<i>Age in years.</i>	<i>Acc. in diopters.</i>	<i>Age in years.</i>	<i>Acc. in diopters.</i>
10,	14	45,	3.5
15,	12	50,	2.5
20,	10	55,	1.75
25,	8.5	60,	1
30,	7	65,	0.75
35,	5.5	70,	0.25
40,	4.5	75,	0

<i>Age.</i>	<i>Additional glass required to produce a comfortable working near point.</i>
45,	+ 1 D.
50,	+ 1.75 D.
55,	+ 2.50 D.
60,	+ 3 D.
65, or over,	+ 3.50 D.

Symptoms.—The chief symptom of recession of the near point beyond the ordinary working distance is dimness of vision for near work, the patient particularly complaining of inability to read, write, or sew, without holding the work at an uncomfortably increased distance. The ordinary symptoms of accommodative asthenopia are very often present, and it is quite likely that the headaches, dyspepsia, and neurotic conditions in women about forty-five years of

age, so often attributed to the menopause, are really directly due to eye-strain. The gradual progress of presbyopia, together with the attempt of nature to remedy the defect by narrowing the pupil, somewhat delays the marked symptoms, and unfortunately most presbyopes unconsciously undergo considerable eye-strain before seeking the oculist.

Diagnosis rests on the age of the person, the history of failing near-vision, the recession of the near point as tested with Jaeger types, and the acceptance of a convex lens at close range. A disproportionate loss of accommodation with the age is indicative of ciliary palsy or insufficiency.

Treatment.—In every case it is necessary to detect and correct the full amount of hyperopia, myopia, or astigmatism that may exist; and for this purpose, in strong, vigorous persons under fifty, the administration of a mydriatic is necessary. Following the ordinary method of prescribing lenses for distance in the kind and degree of ametropia detected, we correct the presbyopia by adding to the distant correction a convex spheric lens that gives the best vision at an ordinary working distance. If allowed to choose the glass and distance, the presbyope will usually select a strong glass at a close reading point, and thus lead the examiner into error. Always try the test-lenses with the reading card at least thirteen inches from the eye. Again, it must be constantly borne in mind that the patient's occupation is an important factor to be considered in prescribing presbyopic glasses. The engraver will need a stronger glass than the seamstress, and, conversely, persons working at a comparatively long distance, such as musicians, artists, ministers in the pulpit, etc., will need a weaker glass in the pursuit of their occupations than they will in ordinary reading.

ANISOMETROPIA.

Definition.—A term used to indicate marked inequality in the refraction of the two eyes. Minor differences are the rule in the ordinary refraction, but these are not practically considered.

Varieties.—Anisometropia may be produced by almost any combination of refractive disturbances. The eyes may be myopic, hyperopic, or astigmatic, in different degrees, or there may be emmetropia, myopia, hyperopia, or astigmatism in one eye and an entirely differ

defect in the other. The condition may be classed according to the manner in which the visual act is performed. Following this classification, we have the following three varieties:

1. Cases in which there is synchronous fixation and, in the narrower sense of the word, binocular vision; for, even though the retinal images are not of equal distinctness and size, binocular vision is still possible. In such cases it seems likely that satisfactory near-vision may be obtained by unequal accommodation for each eye.

2. Cases in which there is alteration of fixation in vision—as, for instance, the eye with the weaker refractive power may be used for distant objects, while the other, with the greater refractive power, is used for near objects. In this condition the patient has such satisfactory vision and so extensive a range of accommodation that he is often not aware of any defect. Alternating vision can easily be discovered by successively covering each eye and testing for near and distant objects. In this class there is usually correct position of the eyes.

3. Cases in which only one eye takes part in vision, the active eye being usually the one with the least refractive error; the inactive eye, being excluded from vision, deviates, and there is a noticeable squint. Even in this condition the patient is very often unconscious of the fact that one eye has lost its visual acuity, and usually discovers this fact by accident. Few of the laity are conscious of the fact that a squinting eye is usually more or less amblyopic, and that the refractive error is directly the cause of the squint, and indirectly the cause of the amblyopia. With this knowledge we see how important an early examination is in cases in which there is a tendency for one eye to deviate in either direction.

Treatment.—It is in this condition that all the judgment and patience of an oculist is called forth. Many arbitrary rules have been advanced, but none have been found that are satisfactory. Each individual case presents new phases, and must be treated separately and with the greatest introspection and caution. The two opposing factors in the treatment of anisometropia are the ambition of the oculist to prescribe such correction as will give synchronous binocular vision and equal acuity, and the rebellion of the established visual system to such a marked innovation.

It can hardly be doubted that many eyes amblyopic from disuse could be saved by care and patience. It should be the ultimate ob-

ject of every oculist skilled in the finer refraction to do all in his power to establish equal acuity and harmonious action in every instance of anisometropia, and to strive, even under the most unfavorable circumstances, to bring an amblyopic eye into function. As would naturally be supposed, the best results are obtained in children and young adults; but even in older persons there is a strong response on the part of nature to measures of restoration, faithfully pursued.

To better enable the beginner to obtain an idea of the mode of procedure in this condition, we will consider a hypothetical case of a child who comes to us with a convergent squint in the left eye. We immediately suspect anisometropia, and on examination we find a slight refractive error in the right eye, but a high degree of compound hyperopic astigmatism in the left. It may be that the left eye is amblyopic to such an extent that vision is reduced to counting fingers at a few feet, and refraction can not be satisfactorily estimated with the test-lenses, and we resort to some objective method, preferably the retinoscope. We prescribe the proper correction for the right eye and slightly under-correct the left eye. We then instruct that these glasses be worn constantly; and for a short period each day, beginning with a few minutes and gradually increasing, we direct that a blinder be worn over the good eye, thus necessitating the use of the amblyopic eye. It is astonishing how quickly vision is restored in a young and healthy child. We must impress upon the mother or guardian of the child the importance of the blinder-exercise and of prompt appearance at the oculist's office at stated intervals for re-examination.

If the patient be an adult, and particularly if of nervous temperament, the case is sure to be a tedious one. With advancing age there is less response to recuperative measures, the long-established visual habit is abruptly broken, and all sorts of distressing symptoms intervene. In such cases, rather than resort to any arbitrary rules, irrespective of variety, we must explain to the patient the overwhelming advantages of binocular vision and the dangers of amblyopia in one eye. The active eye is under extra strain, and is hence more liable to disease; and in such case obscuration of vision, as by cataract in that eye, means almost total blindness; whereas if the amblyopic eye is restored, not only are the dangers to the one eye lessened, but there is still left a more or less active eye on which to depend in case of accident or disease. We then instruct the patient to use the

greatest persistence in the blinder-exercise, and to constantly wear his correction, and we only suspend our restorative treatment after a long and faithful trial. Ignoring the refraction of an undiseased amblyopic eye is unpardonable in a scientific oculist.

ASTHENOPIA.

Definition.—Weakness or speedy fatigue of the ocular muscles or visual powers.

Causes.—Errors of refraction, excessive use of the eyes, muscular insufficiency, and constitutional denutritive processes, such as anemia.

Varieties.—1. **Accommodative asthenopia**, generally due to hyperopic astigmatism or to simple hyperopia producing strain of the ciliary muscle.

2. **Muscular asthenopia**, due to weakness, incoordination (heterophoria), or strain of the external ocular muscles. Myopia, by necessitating extra convergence and straining of the internal recti, is a common cause.

3. **Retinal, or nervous, asthenopia** is a rare variety caused by retinal hyperesthesia, anesthesia, or other abnormality, or by general nervous affections. In overworked school-children it is manifested by complaint of haziness and dimness of the letters, occasional diplopia, photophobia, lacrimation, and local ocular pain. In neurasthenic and hysteric adults all these symptoms are aggravated, and such patients constitute very troublesome cases.

Symptoms.—Symptoms of asthenopia are of such diversity and differ so in degree that a thorough discussion of the effects of eye-strain would necessitate a volume in itself.

As a causative factor in the production of headache, eye-strain is by far the most important. Anorexia, dyspepsia, constipation, heart-burn, nausea, repeated attacks of vomiting, etc., represent some of the gastric reflexes. Amenorrhea and dysmenorrhea are menstrual anomalies sometimes caused by eye-strain. Insomnia, nightmare, chorea, nocturnal enuresis, and even epilepsy, have often owed their existence and perpetuation to uncorrected eye-strain in some form. The multiformity of the effects of eye-strain can only be properly realized when we understand how vital the function of vision is to every act, emotion, and thought. The visual centers are in the

closest connection with the other brain-centers, and the slightest disturbance of the visual mechanism produces sympathetic irritation in the entire motor, sensory, and psychic systems. Happily, the manifold effects of eye-strain, so long ignored, are being appreciated and recognized more and more every day. Besides the reflex symptoms, which are often remote and only brought out by careful questioning (the usual complaint in asthenopia is discomfort in near-work), the patient complains of inability to read or sew for any length of time; the print runs together, there is heaviness of the lids, and often excessive lachrimation. Local congestion soon produces conjunctivitis or blepharitis, and it is our duty to examine the refraction in all cases of chronic conjunctival and palpebral inflammations instead of carelessly dismissing the patient with a time-worn formula for an ointment or a wash. So long as uncorrected ametropia exists there will be recurring attacks of inflammation.

A peculiar rule in asthenopia is that the amount of local or constitutional reflex is in direct proportion to the debility or neurotic tendency of the patient. Strong, vigorous men may, by accommodative and muscular effort, overcome ametropia to such a degree as to entirely mask the condition, and such patients may pass all their lives without experiencing a single uncomfortable reflex; on the other hand, a nervous school-girl or a neurasthenic woman may suffer severest headaches or be the victim of anorexia, nausea, dyspepsia, etc., from the slightest astigmatic error. There is also sometimes noticed an interchangeability of reflexes. When the vision continues normal in spite of the ametropia, reflexes are present; if the vision suffers, reflexes are less conspicuous. Intense local symptoms are also usually unattended by severe reflex symptoms, and vice versa.

Diagnosis rests on a careful examination of the refractive condition of the eye and of the muscular power and muscle-equilibrium. In all cases in which there is presumed to be retention of accommodative power, a mydriatic must be used.

Treatment.—In the accommodative form, rest of the eyes, abstinence from excessive near-work, and constant use of correcting lenses are necessary. Constitutional and hygienic treatment must be urged. If there is any muscular anomaly, it must be corrected by gymnastic exercise with prisms, constant wearing of prisms, or in extreme cases tenotomy and advancement. For nervous asthenopia, near-work

must be reduced to a minimum, and out-door exercise, good food, the administration of tonics, massage, or electrotherapy, are indicated.

AMBLYOPIA AND AMAUROSIS.

Definition.—*Amaurosis* is a term which, from its vagueness, is happily becoming obsolete, signifying partial or total loss of vision. When partial, the term *amblyopia* is now used; when complete, *blindness*. The word is still sometimes used to express blindness when the cause is unknown or doubtful. Properly speaking, *amblyopia* means subnormal acuteness of vision, due neither to dioptric abnormalism nor to visible organic lesion.

Amblyopia exanopsia is a term applied to partial or total blindness in an eye from disuse. It is of common occurrence in anisometropia and in strabismus. The individual with a squinting eye naturally has double vision; in order to obtain monocular vision he must either turn the axis of the squinting eye or learn to mentally suppress the image of that eye. If for anatomic reasons rotation is impossible, or if there is such difference of refraction that images of different distinctness and size are observed, the mental suppression of the image is the only alternative, and progressive amblyopia results.

Treatment is successful directly in proportion to the youth of the patient. It consists in restorative measures, such as correction of refractive error and subsequent exercise of the weak eye. In cases of strabismus, tenotomy or advancement is necessary. The treatment of anisometropia has already been reviewed.

Night-blindness (*hemeralopia*) may in itself constitute a disease due to over-stimulation or lack of proper nourishment, or it may be a symptom of retinitis pigmentosa or similar degenerative disease of the retina, alone or with disease of the choroid. It is sometimes noticed among people the subject of extreme denutrition from climatic and social influences, such as the lower classes of the Russians; and the disease is, in fact, almost endemic in some parts of Russia after the religious fast during Lent.

Treatment consists in rest from bright light by protective glasses, improvement of the general health, and the administration of tonics, cod-liver oil, etc.

Other forms of retinal injury from prolonged exposure to extreme glares, such as the sun's rays upon the sea, upon vast expanses of snow, and continual gazing at a bright light, such as an electric light, are the causes of temporary amblyopia and amaurosis. Snow-blindness, moon-blindness, electric-light-blindness, sun-blindness, are the significant terms applied in such cases. The treatment consists of rest under favorable hygienic circumstances.

Nyctalopia etymologically means night-blindness, but the general usage making the term mean night-vision is so strongly entrenched that it is useless and confusing to reinstate the old significance. The condition in which one sees better at night, relatively speaking, than by day, is due to some lesion in the macular region rendering it blind; at night the pupil dilates more than in the day-time, and hence vision with the extramacular or peripheral portions of the retina is correspondingly better. Nyctalopia is a symptom of macular disease and not a disease in itself. All night-prowling animals have widely-dilated pupils, and in addition to this they have in the retina a special organ called the *tapetum lucidum*, the function of which is to reflect to a focus in front of them the relatively few rays of light that enter the widely-dilated pupil and thus enable them the better to see their way. Hence the luminous appearance of the eyes of such animals in the dark.

Toxic amblyopia may be due to such conditions as provoke supersaturation of the blood with toxic ingredients—as, for instance, in disease of the kidney we may have accompanying the resultant uremic poisoning, amblyopia, or even total blindness of both eyes, appearing sometimes suddenly and sometimes after a day or two of gradually failing vision. The disturbance in such a case is supposed to be cortical. If the patient survives the attack of uremia, the blindness may disappear completely in a few days. Diabetic amblyopia is distinguished by its association with the ordinary symptoms of diabetes.

Amblyopia from malarial fever and quinin has been reported, and in rare cases complete blindness has intervened. Quinin itself has produced bilateral amblyopia, and conversely has cured malarial amblyopia. Other poisonous substances, such as tobacco, alcohol, lead, etc., by causing either macular disease or retrobulbar optic neuritis, produce subnormal acuity of the central field. These will be discussed under Diseases of the Retina and Optic Nerve.

Traumatic amblyopia follows blows upon the sku¹¹

directly on the eye, or on so remote a portion as the spinal cord. Rigid miosis may follow such injuries. The visual disturbance is caused directly either by hemorrhage into, or pressure upon, some portion of the visual apparatus, either in the orbit or in the brain, or reflexly, as after spinal injury.

Hysteric Simulation and Malingering.—Hysteric amblyopia is not uncommon, but very many cases so diagnosed are properly the sequence of asthenopia. Malingering by the declaration of amblyopia or blindness may be found in insurance examinations and in military life, and often to procure damages after alleged injuries. Many ingenious devices have been adopted to expose the simulant, all depending upon the fact that in ordinary visual perception there is no account taken of the exact participation of the two eyes. If we hold a book before the patient's eye and interpose a pencil in front of the eye supposed to be active, the reading will be slightly interrupted if the left eye is amblyopic; if, however, the amblyopia is feigned and not real, the left eye will escape the pencil and the reading will be uninterrupted. Another way is to interpose a highly convex lens in front of the eye supposed to be well, and if test-type is removed beyond the focal distance of the lens and is still legible, we know that the other eye participates in vision. The production of double images by the interposition of prisms also proves binocular vision. Still another method depends upon colored letters placed upon a dark background which can not be seen through glasses of complementary colors. A person looking at green-blue letters on a dark ground through a red glass over the sound eye, and a white or green glass over the alleged blind eye, will be unable to see the letters if the allegation is true.

Amblyopia from Entoptic Phenomena.—*Muscæ volitantes* are curious dots or rings of all shapes which float before the eye, and in some conditions, such as high myopia, are so numerous that they can not be ignored, and cause considerable disturbance of vision. The origin of *muscæ* is not exactly understood, but they are probably the remnants of some ocular debris. It has been suggested that they are intraocular manifestations of general waste-tissue accumulation (uric acid diathesis), and that they are relieved by appropriate diet, exercise, and medication. Subjective examination of the *muscæ* is of interest, and they can be studied by lying on the back and looking at a bright cloud in the sky. By what is called ocular

ballotement, turning the eye downward and arresting the movement very sharply and suddenly, one may get a positive rebound of *muscæ* from the bottom of the chamber up to the line of visual perception. **Micropsia** is a condition in which images of objects seem too small, and is supposed to be due to a dispersion of the retinal end-organs, so that fewer receive the image. **Megalopsia** is the opposite of this condition.

Metamorphopsia is an apparent distortion or change of the form of objects, supposed to be produced by changes in the relative position of the retinal end-organs.

Little can be done for the relief of entoptic phenomena. Proper correction of the refraction and muscular anomaly, together with hygienic precautions and the use of eliminatives, as sodium phosphate and the iodids, will sometimes diminish *muscæ*.

COLOR-BLINDNESS.

Color-perception.—A beam of light passed through a small opening, or if passed through a prism, will separate into an arrangement of colors on a screen. This arrangement is called the spectrum. The explanation of the spectrum is that the beam of white light is made of a number of rays having different wave-lengths or rates of vibration. Rays under four hundred billion vibrations a second are not perceived by the human retina as light, and are called heat rays. The range of the perceptible spectrum is from red light, about four hundred million millions vibrations a second; to violet, having over seven hundred and fifty million millions a second. Between red and violet are found orange, yellow, green, and blue rays. Rays having a higher rate of vibration than violet can not be appreciated by the human eye, and are only recognized by their chemic and physical effects. Therefore, the usual definition of color-sense is the power of the eye to distinguish different wave-lengths. Different explanations are given of color-perception. We know that the irritation on the rods and cones of the different wave-lengths is carried back through the optic chiasm to the visual center in the occipital lobe in the brain; but in exactly what manner we become conscious of color-impression, and in what way it can be altered, we are not definitely certain. The majority of observers in this field seem to forget that the retina is a substance of considerable thickness and not

hypothetic plane, and also the participation of the visual center of the brain in color-consciousness and color-blindness. At the present time there are two important theories, both of which have been found faulty, but which have become so identified with this subject that we briefly note them. According to the **Young-Helmholtz theory**, the retina possesses three sets of color-perceiving elements,—those for red, green, and blue or violet. According to **Hering's theory**, the color-sense and the light-sense depend upon chemic changes in the retina, or in the substance called the visual purple of the retina. He suggests that there are three different visual substances,—the white-black, red-green, and blue-yellow,—and that sensations of light and color are due to the using up and restoration of these substances.

Varieties of Color-Blindness.—Total and partial ; congenital and acquired.

Total color-blindness, in which the solar spectrum appears grayish, is very rare.

Partial color-blindness is quite common. Statisticians tell us that the proportion is 1 : 25 among males, and 1 : 400 among females. There may be blindness to blue, yellow, red, or green. However, the colors that most often fail to make proper impressions are red and its complementary color, green. These colors do not appear as absolutely black, but they can not be distinguished from one another and from certain shades of gray and brown. In extreme cases there is total blindness for red and green, and even the brightest shade of red can not be distinguished from green. Unfortunately, the colors most often at fault have been selected by railroad companies and navigators as their signal colors ; hence, we see how important it is for the employees of transportation companies to have the color-sense absolutely perfect.

Congenital color-blindness is the most common form. It is often hereditary, and sometimes skips several generations. The discoverer of color-blindness was Dalton, a distinguished professor of chemistry, who himself was color-blind, a fact which he ascertained by accident.

Acquired color-blindness may be the result of disease or accident. Defective color-sense often appears after disease of the optic nerve, and is a particular symptom in optic neuritis and atrophy due to excessive use of tobacco and alcohol. However, central color-blindness may be seen in all forms of toxic amblyopia. A peculiar point to be noted in tobacco-amblyopia is the fact that the patient may be

able to distinguish colors close to the eye, but when they are farther removed, he is color-blind, particularly for green and red. This makes it quite important to test for color-blindness at the normal signal distance in addition to the skein-test at close range. Color-blindness is sometimes the result of traumatism; occasionally, after blows upon the head, color-blindness is noticed in one-half the field of vision only, the other half being normal in its color-perception.

Chromatopsia is a condition in which all objects become tinged with certain colors. It is common after cataract extraction. Large doses of *santonin* have the peculiar property of rendering the whole field of vision yellow.

Diagnosis.—In the ordinary **Holmgren test**, the person is given a test-skein of wool of a light-colored pink, and told to *select* (and not name) from a mass of similar skeins those which most nearly resemble the skein to be matched. If he is color-blind he will confuse the grays, the greens, the pinks, the browns, and the reds. As a confirmative test, he is then given a light pure green skein to match in the same way. To distinguish between green-blindness and red-blindness, the *rose-test* is used, and the color-blind patient will select, indifferently, either the blues intermingled with the rose, or, perhaps, the blue-greens or grays. Finally, the red test is used as a control.

Dr. William Thomson has devised a convenient apparatus for testing for color-blindness, which has been widely adopted by railroad examiners. It consists of a stick to which numerous bundles of yarn are attached, a light green being used as the test-skein. The method of using the Thomson stick is described by its author as follows: Using the light-green test-skein, the patient under examination is asked to match it in color from the yarns on the stick, which are arranged in alternate green and confusion colors, and which are numbered from one to twenty. The selection of ten tints is required, and the examiner notes the number of the tints chosen. The odd numbers are green and the even ones the confusion colors. If the patient has a good color-sense, his record will exhibit none but odd numbers; if he is color-blind, the mingling of even numbers betrays the defect.

There are other color tests, but these two are sufficient for practical purposes. The field for vision for different colors is tested in the same manner as the field for white, using a colored object instead of a white one.

In the *peripheral* field of vision there is a contraction for colors ranging from white thus: Yellow, blue, red, and green. In contradistinction to this, we find the *central* vision for red the most distinct, and violet least distinct. Hence the use of red for signals.

The tests for distant color-vision should be made with colored lamps or lanterns, under normal conditions, either on the track or in the depot.

Treatment for the congenital form is useless. The treatment for acquired color-blindness is directed to the cause. In the toxic forms abstinence from tobacco and alcohol is necessary.

THE FIELD OF VISION.

The field of vision of an eye is that portion of space before the eye from which, when at rest, it can receive impressions of light. Ordinarily speaking, the field of vision is considered the space before the eye in which small objects can be seen while the visual axis is fixed in one position. The *binocular field* is the space in which objects can be seen with both eyes open without moving the head. The *field of fixation* designates that portion of the field of vision in which objects may be directly looked at.

Modes of Testing the Field of Vision.—The simplest method is to face the patient, covering the eye not under examination, and closing your own eye opposite the patient's covered one—as, for instance, in testing the patient's left eye, close his right eye and your left eye. Then tell the patient to look directly at your open eye, and while standing accurately in front of him, you meet his gaze; then, holding your finger off to the side beyond the field of vision, you gradually bring it in and note the point at which the patient first sees the finger. This test can be tried in every direction, and if the surgeon's field of vision is normal, by comparison he can readily estimate any alteration in the patient's field. Due allowance must be made for extra prominence of the brow or nose. This test will do for simple diagnosis, but it is somewhat unscientific, and does not bring out the finer points which it is so often necessary to detect.

The *perimeter* is an instrument for exact measurement of the field of vision. It consists of a graduated arc, which turns at its center upon a pivot. At the inner side of the arc, and directly opposite the pivot, is a small, white disc, upon which the patient's gaze must be

steadily fixed. The most improved form of perimeter (Fig. 35) is self-registering, and marks on a special card the exact limitation of the field at every angle to which the graduated arc is turned. The patient is seated in front of the perimeter, with the chin on a rest, which brings the eye to be tested into the middle line directly oppo-




FIG. 35.—IMPROVED MCHARDY PERIMETER.

site the point of fixation. The other eye is covered. During the whole examination the patient must gaze directly at the white spot in the center of the perimeter. A movable disc containing a small white surface is gradually brought in toward the center until it is seen by the patient as white. This is repeated at every angle, and the results recorded upon a special perimetric chart. The fields for

color are obtained in the same manner, using instead of a white object a tinted one, corresponding to the color to be tested for. In order to detect scotomata, the disc should be moved all the way in to the center, and any point within the field at which the color disappears should be noted. If the patient is amblyopic or cataractous, instead of the ordinary disc, a lighted candle may be moved along the arc of the perimeter, and another light put at the point of fixation. The perimeter may also be used to examine the angle of deviation in strabismus.

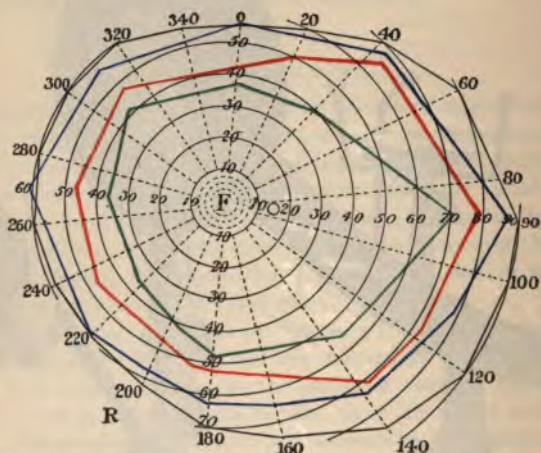


FIG. 36.—PERIMETRIC CHART FOR WHITE, BLUE, RED, AND GREEN (RIGHT EYE).—
(After Fick.)

The normal field of vision (Fig. 36) is naturally contracted at the nasal side to about 65° on account of the projection of the bridge of the nose. It contains a physiologic "blind spot" to the temporal side of the fixation point, between 10 and 20, as shown by the small circle in the diagram. The fields for blue and yellow are somewhat smaller than that for white, the field for red still more contracted, and green is the innermost field. However, the size of field for any color varies considerably for different persons, and for the same person with different degrees of illumination.

Alterations in the field of vision may be concentric or regular contractions in all directions, or distinctly uneven and irregular contrac-

tions, according to the amount of fundus-involvement. **Scotomata** are patches in the field of vision in which there is blindness to the object under observation. A **positive scotoma** appears as a dark spot before the patient's vision; a **negative scotoma** is generally only detected by examination with a perimeter, and appears as an appreciable interval in which there is blindness. It is usually due to some loss of perceptive power, which, when located at the macula, or in the central fibers of the optic nerve, causes the well-known **central scotoma**, which is particularly noticeable for red, and which is an important sign in many toxic amblyopias. The physiologic scotoma, or **blind spot**, represents a point at which the optic nerve enters the eye. The changes in the field of vision are of diagnostic importance in many pathologic conditions of the fundus, and the perimeter is an efficient aid not only in diagnosis, but in showing the exact results of treatment.

The disadvantages of limitation of the field of vision may be readily understood when we look through a long tube. Peripheral objects are not seen, and unless the patient continually moves the head from side to side and rotates the eyeballs, he will stumble over neighboring objects. It sometimes happens that the central vision may remain so good that the smallest print can be read while the peripheral vision is absolutely destroyed. In central scotoma the patient must look above, below, or to one side of the object, for, if he fixes directly on it, the object is not visible.

Hemianopsia is a term used to indicate obliteration of half the visual field in both eyes. It may be complete, but is usually incomplete. There is generally a bending out of the hemianopsic line at the point of fixation, giving us reason to believe that the fovea is supplied by fibers from both optic tracts, whereas the remainder of the retina is supplied by the tract on its side—that is, the right optic tract supplies the right halves of the two retinae, and the left the reverse.

When the obliterated half is on the same side in both eyes, we speak of **homonymous hemianopsia**. (Fig. 37.) Such a condition is indicative of disease or pressure behind the chiasm, before the fibers have crossed. In left-sided hemianopsia there is some lesion of the right optic tract or its connection with the cerebral cortex, and the reverse of this in right-sided hemianopsia. In **heteronymous or crossed hemianopsia**—that is in both temporal or both nasal halves—there is probably a lesion at some part of the chiasm which

cludes the decussating fibers of both tracts. **Vertical hemianopsia** is due to partial lesion in front of the decussation.

In **homonymous hemianopsia** we have additional aid in locating a tumor or lesion by the pupillary reflex to light. The pupillary centers are near the corpora quadrigemina; if we carefully direct rays of light upon the blind side of a retina in a case of homonymous hemianopsia, and yet get pupillary reaction, we know that the pupillary centers and all the region in front in the path of pupillary reaction are intact, hence the lesion is back of the corpora quadrigemina; conversely, if pupillary reaction is destroyed, we have reason to believe that the lesion is somewhere between the corpora quadrigemina and the chiasm. This test is known as **Wernicke's sign**.

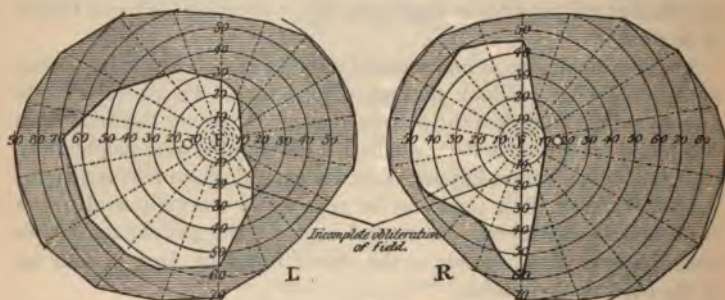


FIG. 37.—INCOMPLETE HOMONYMOUS HEMIANOPSIA, RESULTING FROM UNILATERAL CEREBRAL HEMORRHAGE.—(After Fick.)

The dark areas indicate the obliterations. The normal areas remaining are contracted.

Causes.—Hemianopsia is usually due to hemorrhage, embolus, traumatism, or tumor.

The clinical significance of hemianopsia depends on the amount and form of the obliterated field and the associate symptoms, such as hemiplegia, hemianesthesia, aphasia, etc.

Transient hemianopsia is a sign of some cortical disturbance, and is probably the result of spasm of the superficial cerebral arteries. It is often associated with unilateral headache, vertigo, aphasia, amnesia, and other symptoms referable to a cerebral origin. In a number of the patients there is a family history of epileptiform seizures.

THE OCULAR MUSCLES.

Anatomy.—The eye is moved by the following six muscles: the superior, inferior, external and internal recti, and the superior and inferior obliques. (Fig. 38.)

The superior rectus rises from the upper margin of the optic foramen and from the fibrous sheath of the optic nerve, and is inserted by a tendinous expansion into the sclera, about 7.7 mm. from the margin of the cornea.

The inferior rectus rises from the lower margin of the optic foramen, in common with the internal rectus, and from the fibrous

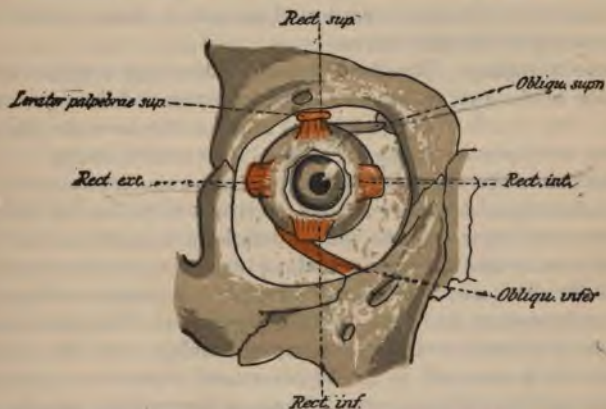


FIG. 38.—THE EYE-MUSCLES SEEN FROM IN FRONT.—(After Merkel.)

sheath of the optic nerve, and is inserted into the inferior portion of the sclera, about 6.5 mm. from the margin of the cornea.

The internal rectus is the thickest and shortest of the straight muscles, and arises from the common tendon and fibrous sheath of the optic nerve, and is inserted into the inner surface of the sclera about 5.5 mm. from the corneal margin.

The external rectus, the longest of the straight muscles, arises by two distinct heads, one from the location of the common tendon of the inferior and internal rectus, and the other from the upper margin

of the optic foramen with the superior rectus. It is inserted into the outer surface of the sclera 6.9 mm. from the margin of the cornea. Passing between its heads are the nasal, third, and sixth nerves.

The superior oblique arises from the upper margin of the optic foramen, and from the fibrous sheath of the optic nerve, and passes forward to the pulley beneath the internal angular process of the frontal bone; its tendon is then reflected beneath the superior rectus muscle to the outer and posterior surface of that part of the sclera near the entrance of the optic nerve. At the point at which it passes through the pulley the tendon is inclosed in a synovial membrane.

The inferior oblique is a thin, narrow muscle, arising from the inner margin of the superior maxilla, immediately exterior to the lacrimar groove. It passes beneath the inferior rectus to be inserted into the external and posterior portion of the sclera, about 5.5 mm. from the entrance of the optic nerve.

Nervous Supply.—The third nerve (oculomotor) supplies all the muscles of the eye, except the external rectus and the superior oblique. The fourth nerve (trochlear) supplies the superior oblique; and the sixth nerve (abducens) supplies the external rectus.

Function.—The eye is turned out by the abductor muscles—the external rectus and the two oblique; it is turned in by the adductor muscles—the internal rectus and the inferior and superior recti. The superior rectus and the inferior oblique turn the eye upward, and are called the elevators; the inferior rectus and the superior oblique turn the eye downward, and are called the depressors. The upper part of the eye is rotated inward by the superior oblique and the superior rectus; the lower part of the eye is rotated inward by the inferior oblique and the inferior rectus. There is harmonious impulse and concerted action of the muscular apparatus of the two eyes.

FUNCTIONAL ANOMALIES.

Muscular Balance.—When the visual axes of the two eyes exactly meet at the object to which they are directed, the eyes are said to be balanced or in equilibrium. This muscular balance is maintained by the constant and equally distributed innervation of the ocular muscles, and is directly dependent upon the relative anatomic *formation and physiologic* strength of the muscles. Any disturbance of

these factors produces muscular imbalance. However, muscular imbalance does not imply inability to perform perfect binocular fixation, for in some cases the visual axes are rightly directed by increased innervation, and it is this necessary extra expenditure of nervous energy that causes the asthenopic symptoms so frequent in minor disturbances of muscular equilibrium.

Perfect binocular vision requires that the visual axes should exactly meet on the point of fixation and that the retinal impression of both eyes should be simultaneously conducted to the brain and be fused as one image in the visual centers. When there is any deviation from these normal requisites, diplopia, or double vision, results.

In studying the classification of the functional anomalies of the ocular muscles, it must be remembered that both eyes are involved, and the nomenclature used qualifies the fault, but does not locate it—for instance, right hyperphoria indicates that either the right superior rectus is too strong for the right inferior rectus, or the left superior rectus is too weak for the left inferior rectus—that is, one eye tends to turn upward, or the other downward.

Arbitrary classification of the functional anomalies can not be made; the differences are of degree rather than variety, and the dividing line is somewhat indistinct. Cases of muscular imbalance in which the equilibrium is maintained by increased innervation of any of the muscles, or in which the deviation of the visual axes is only transient or slight, may be classed under the head of insufficiency. Cases in which there is decided deviation, which can not be overcome by increased innervation, may be classed under the head of strabismus. In the ordinary acceptance of the two words we may consider insufficiency as latent or nearly corrected squint, and strabismus as manifest or uncorrected insufficiency.

Adduction is the power of rotating the eyes inward—that is, of overcoming the diplopia produced by prisms, bases out.

Abduction is the power of rotating the eyes outward—that is, of overcoming the diplopia produced by prisms, bases in.

Sursumduction is the power of rotating the eyes in the horizontal meridian—that is, of overcoming the diplopia produced by prisms, bases up (infraduction) or bases down (supraduction).

Stevens, of New York, has suggested a descriptive nomenclature for the functional anomalies of ocular muscles which has been universally accepted in this country. For normality and the different varie-

ties of disturbance of muscular equilibrium, or latent squint, he suggests the use of the following terms :

Orthophoria, perfect binocular equilibrium.

Heterophoria, imperfect binocular equilibrium.

The varieties of heterophoria are :

Hyperphoria, a tendency of one eye to deviate upward.

Esophoria, a tendency of the eyes to deviate inward.

Exophoria, a tendency to deviate outward.

Hyperesophoria, a tendency of one eye to deviate upward and inward, or of its fellow to deviate downward and inward.

Hyperexophoria, a tendency of one eye to deviate upward and outward, or of its fellow to deviate downward and outward.

For cases in which there is *absolute turning* or *deviation* of the visual axis instead of only a *tendency*, and hence inability to effect perfect binocular fixation, the following terms are suggested :

Orthotropia, perfect binocular fixation.

Heterotropia, a decided deviation from parallelism (squint).

Of the different varieties of heterotropia we have :

Esotropia, a deviation inward (convergent squint).

Exotropia, a deviation outward (divergent squint).

Hypertropia, a deviation of one eye upward or the other downward.

Hyperesotropia and *hyperexotropia* are combinations of the above.

TESTS FOR FUNCTIONAL ANOMALIES.

General Remarks.—A prism deflects rays toward its base ; hence, by placing a prism before an eye the rays entering the eye will be so bent as to cause them to leave the visual axis, and, unless there is muscular compensation, in such a case *diplopia*, or double vision, is the result. A high-degree prism base down before an eye will so bend the rays that they will reach the retina at a point below that upon which they would have impinged had they not been interrupted. By the mental habit of judging the position of an object, the deflected rays are referred to a point above the optic axis ; in the same way, rays impinging on the nasal side of the retina cause an impression of an object on the temporal side, and vice versa. The forms of diplopia may be illustrated by figures 39 and 40.

In figure 39 the right eye is turned in, and instead of perceiving a

single object, *ob*, diplopia results, and the patient sees one image, which he refers to *ob*, and another, which is referred to *F. ob*. The image of the right eye is to the right of that of the left eye, and the case is designated homonymous diplopia. In figure 40 the right eye is turned out, and the apparent position of the object *ob* is at *F. ob*. The images have crossed in their relative positions; that of the right

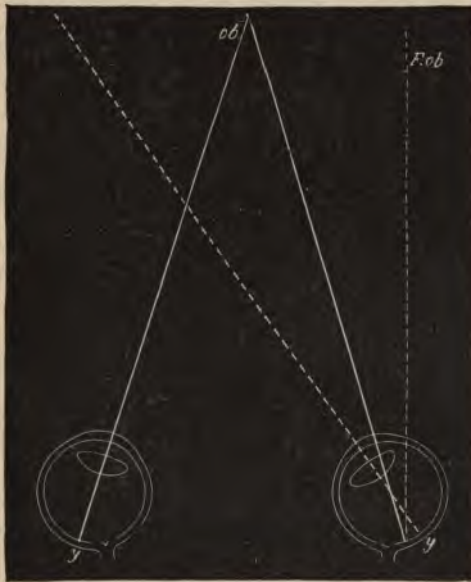


FIG. 39.

ob. Object. *F. ob*. Apparent position of object seen by right eye.

eye is seen to the left of that of the left eye, and the case is called crossed diplopia.

The amount of muscular insufficiency is measured by the strength of the prism, which, placed before the eye at rest, will deflect the imperfectly directed rays of light in such a manner that there will be perfect binocular fixation.

The strength of the ocular muscles is measured by the prism which they can overcome, and, by increased innervation and action, main-

tain perfect binocular fixation. The muscular strength varies with each individual, but there is a normal relation between the strength of certain muscles. The adductors can normally overcome prisms from 20° to 30° , and the abductors can overcome prisms of from 6° to 8° .

It must be remembered that in cases of stable muscular equilibrium

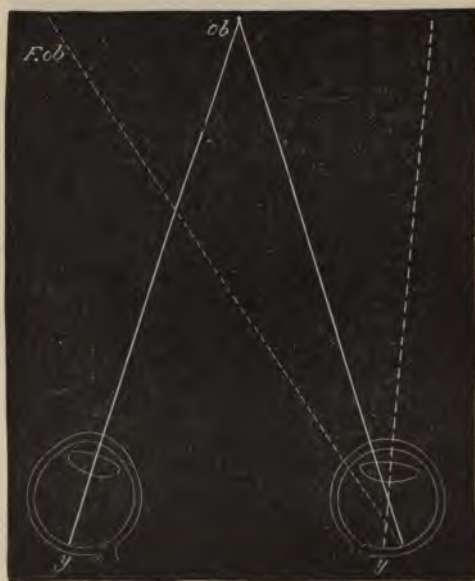


FIG. 40.

ob. Object. *F. ob.* Apparent position of object seen by right eye.

there may be still decided insufficiency and disproportion in the normal relative strength of the adductors and abductors.

Tests for the strength of ocular muscles are based upon their ability to overcome prisms while both eyes are fixed on a small light about six meters' distance. In these tests we aim to measure the associated powers of the muscles concerned in abduction, adduction, and sursumduction rather than the strength of the individual muscles which *may never have* individual action. To test adduction, the prisms

are placed bases out; to measure abduction, bases in; to measure the elevators (supraduction), bases down; to measure the depressors (infraduction), bases up.

It is the measurement of the strength of the abductors and adductors that is of most practical importance in ordinary practice, and in all cases in which there is reason to suspect any muscular insufficiency in the causation of asthenopic symptoms not only should the tests for muscular equilibrium be applied, but also the power of adduction and abduction should be measured.

Cases of apparent orthophoria sometimes show great insufficiency of the lateral muscles of the eye. The performance of reading and other near-work with a weakened power of adduction gives rise to the most annoying symptoms.

The ordinary procedure in testing adduction and abduction is to seat the patient about six meters away from a small flame, and instruct him to fix his vision on the flame. To measure abduction, prisms, bases in, are placed before the eye until permanent diplopia is produced. The highest prism that can be overcome is the measurement of the abduction. In testing for adduction, prisms, bases out, are used until increased convergence is no longer able to maintain the image of the light single. The highest prism that can be overcome is the measurement of adduction.

A more convenient mode of testing adduction and abduction is by the so-called "prism-battery" suggested by the senior author.

Rotary variable prisms are constructed in such a way that two prisms of equal strength shall be equally rotated in opposite directions. During the rotation certain components of the two prisms neutralize each other, while the remaining components act together and give the variable effect. Risley's rotary prism (Fig. 41) is an adaptation of the Crétés prism. Two 15° prisms are mounted in a milled-edge containing-cell, having the same diameter as employed in the ordinary test-lenses, and will therefore readily fit in the common trial-frames. The superimposed prisms are caused to rot



FIG. 41.—ROTARY VARIABLE PRISM.
—(Risley.)

over each other by means of a milled-edge screw projecting from the front. The strength of the resulting prisms is indicated by a graduated scale engraved on the front plate of the containing cell. To produce more delicate results in the lower prismatic powers, Jackson has employed three prisms, one stationary of 15° and two rotary prisms of $7\frac{1}{2}^\circ$ each.

Phorometer.—The ocular muscle tests may be simplified and made more exact by the use of instruments called phorometers, by which the degree of insufficiency existing in a muscle can be easily found. Stevens, of New York, has devised an excellent instrument of this description, consisting of two revolving 4° prisms so arranged

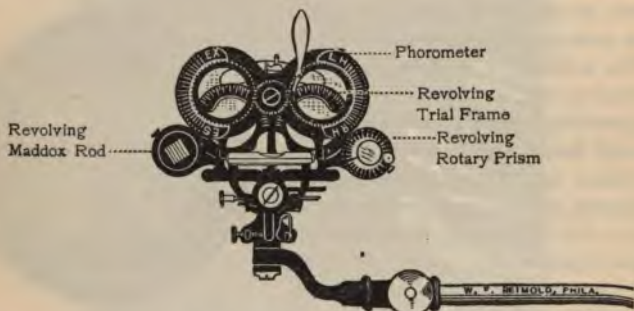


FIG. 42.—IMPROVED OPTOMETER.

that diplopia is produced and any heterophoria discovered and measured simultaneously.

Various optometers have been devised, including trial-frame, phorometer, revolving Maddox rod, and revolving rotary prism. With these instruments the powers of adduction, abduction, and sursumduction, as well as heterophoria, may be measured. The best of these instruments is that represented in figure 42.

By careful stimulation at progressively increasing distances, the full amount of the adducting power, called the convergence-stimulus adduction, may be measured. The patient fixes first on an object brought within six inches of the eyes and then slowly carried away toward the flame, transferring the vision on the flame just as the object reaches it.

Tests for Heterophoria.—The "cover test," although unreliable and not available in low degrees, sometimes enables the physician to detect the tendency toward deviation. For rough diagnosis the patient is placed in front of the physician, with his eyes at about the level of the bridge of the physician's nose, at which he is told to look steadily. A card is placed over one of the eyes and a moment afterward withdrawn; if there is a tendency to deviate outward, a slight movement inward is noticed immediately after the withdrawal of the card. In the same manner a tendency inward will be detected by quick movement outward after the withdrawal of the card. Both eyes can be tested in this manner.

In cases of insufficiency, so slight an obstacle as a colored glass placed before one eye may produce immediate diplopia—for instance, in a case of unstable muscular equilibrium, we place a red or a blue glass before the *left* eye; the patient may immediately declare he sees two images of the light at six meters' distance, the colored one being to the left of the white image, showing that we have **homonymous diplopia**, and consequently a tendency toward inward deviation. If the colored light were seen to the right of the white one, we would have **crossed diplopia**, and hence a tendency toward outward deviation. There

might also be a tendency toward upward or downward deviation in addition to the lateral forms. The tendency toward deviation produced by the interposition of a simple colored glass is soon overcome, and for this reason the test is unreliable. Another disadvantage lies in the fact that the lateral and horizontal defects can not be measured separately and distinctly.

The **Maddox rod** consists of a glass rod or series of rods which, acting as a strong cylinder, distort the natural image of a small flame at six meters into a streak of light. It is usually mounted in a metal disc to fit in the trial-frame. (Fig. 43.) When a Maddox rod is placed before one eye, the difference between the images seen before the two eyes is so marked that, unless there is perfect muscular equilibrium,



FIG. 43.—MADDOX ROD.

binocular fixation is impossible. In order to make the difference more marked and readily to call the patient's attention to the streak, the Maddox rod is ordinarily colored red, or a white rod may be used ; or a plane colored glass may be placed before the other eye. In testing with the Maddox rod the patient, as before, is seated six meters in front of a small flame, which should be placed in the darkest portion of the room and beyond confusion with any other lights. The rod must be placed in the trial-frame, exactly before the pupil, or no streak will be seen. To begin the test, the eye containing the rod is first covered and the point of light noticed ; the other eye is then covered and the rod, adjusted until the streak is seen ; then both eyes are uncovered, and if the adjustment is correct, both streak and flame will be seen simultaneously.

To test for a tendency toward lateral deviation the rod is placed horizontally before the *left* eye ; being refracted through a cylinder, the image is seen running at right angles to the axis of the rod, which, in this instance, being horizontal, the streak will appear vertical. If there is orthophoria, the streak will run immediately through the light. If there is exophoria, the streak will be to the right of the light ; if there is esophoria, the streak will be to the left of the light ; and the degree of defect is measured by the prism, base in or base out, which will bring the streak immediately through the light. The rotary prism or individual prisms mounted in cells may be used for the measurement.

To test for hyperphoria the rod is placed vertically before the left eye, and if the streak, which now runs horizontally, is above or below the light, a prism, base up or base down, as the case may require, that brings the streak immediately through the light is a measurement of the hyperphoria. In recording results it must be mentioned which eye the prism is placed before ; as, for instance, base down left and base up right. It is well to establish uniformity in using this test, and we invariably place the Maddox rod and the correcting prisms before the left eye.

We have found that the segment of a high-power glass cylinder just large enough to fit in the test-lens cell will give as good a streak as the Maddox rod.

The Maddox rod is usually perfectly satisfactory, but if for any reason the streak is not plainly seen, or we believe that the patient is voluntarily attempting to overcome his heterophoria, we must resort

to the use of prisms in testing for the heterophoria. Procedure in this case depends upon the production of diplopia by prisms of such strength that they can not be overcome by increased action of the ocular muscles. To test the lateral muscles an artificial hyperphoria is produced by placing a prism of about eight degrees base up or base down before one eye, and a red glass before the other. If there is perfect muscular equilibrium, the two images will be seen, one immediately above the other. However, should there be exophoria, there will be crossed diplopia, and the left image will be seen on the right-hand side. The degree of exophoria is measured by the prism, base in, which, placed before the left eye, brings one image directly above the other. If there is esophoria, homonymous diplopia is present, and the left image will be seen to the left of the right image. The degree of esophoria is measured by the prism, base out, which, placed before the left eye, will bring the two images in the same vertical plane.

To test hyperphoria, a prism of about ten degrees, base in, is placed before one eye and a red glass is placed before the other eye. If there is perfect equilibrium, the two images will be seen by the patient exactly on the same horizontal level. If the red glass is before the left eye and the red image is seen lower than the white one, there is left hyperphoria, and conversely. The degree of hyperphoria is measured by the prism, base up or base down, which, placed before the left eye, will bring the two images on an exact level. The phorometer is the most convenient means of measuring deviations made manifest by the production of diplopia.

TREATMENT OF FUNCTIONAL ANOMALIES.

As anomalies of refraction are the chief causes of heterophoria in almost every case, the refraction should be examined under a mydriatic, and ametropia corrected. We must also bear in mind the muscular condition when prescribing. If the patient is hyperopic, we must order a weak correction in exophoria, reduce the correction slightly in orthophoria, and only use a strong correction in esophoria. (See treatment of hyperopia.) In many cases such procedure alone will sufficiently modify the defect, or even perfectly restore the muscular balance, and relieve such reflex symptoms as headache, nausea, indigestion, vomiting, and various other nervous phenomena. It is

said that hyperopia and hyperopic astigmatism are the errors most associated with esophoria, and that exophoria is frequently associated with myopia and myopic astigmatism. This is theoretically correct, but it is not always confirmed in practice.

Another cause of heterophoria is distinctly weakened general vitality, and we expect no decided results until the systemic condition is improved. In young or vigorous persons we may expect to increase the muscular power and innervation sufficiently by normal exercise of the eyes with the correcting lenses. If, however, the patient is extremely debilitated or weak, the only relief that can be given is by the use of correcting prisms. However, in such cases a partial correction should at first be applied, which, if satisfactory, should be worn for a while and, if possible, afterward carefully reduced in strength, or, if unsatisfactory, should be gradually increased until comfort is obtained. Tenotomy should be a last resort.

Treatment of Insufficiency of the Adduction.—In healthy individuals, even past middle life, we expect the best results in cases of insufficiency in adduction (a common defect), by systematic exercise with prisms, bases out. To prescribe a prism for permanent use or to perform tenotomy in such cases without a prolonged trial of gymnastic exercise with prisms is assuredly unwarrantable and bad practice.

Patients suffering from insufficiency of the interni are chiefly persons whose habits and occupations cause excessive use of the eyes. The intense headaches and gastric neuroses accompanying this defect call for a special mode of treatment. To prescribe prisms is only affording a crutch and encouraging the insufficiency. Permanent cure can hardly be effected by such treatment. The principle of tenotomy in exophoria is to weaken a strong or normal muscle to such a degree that it will be equally insufficient with its defective fellow. Such treatment as this can hardly increase the adducting power, the deficiency of which is at the root of all the uncomfortable symptoms. Advancement of the interni does not secure increased innervation. In view of these facts, the only rational treatment is that of a tonic nature, effected by the best hygienic and constitutional treatment, and careful and graded gymnastic exercise of the deficient muscles.

It is a noteworthy fact that the prescription of healthful, open-air exercise will of itself be sufficient to cause the muscular defect to

disappear and the asthenopic symptoms to subside, and it is also a fact that the general health will improve very often under the ocular gymnastics, which, by remedying the muscular defect, removes the exciting cause of the systemic troubles.

The skepticism as to the value of ocular gymnastics in cases of insufficiency of adduction is largely due to the fact that the treatment has not been carried out rationally and systematically, and we especially call the student's attention to the proper *modus operandi*. For minor cases the "thumb exercise" is of value. This consists of exercising the convergence by drawing a thumb gradually toward the bridge of the nose, meanwhile trying to maintain a single image of the finger. The thumb should be withdrawn immediately when diplopia results. This exercise should be repeated a dozen times at each exercise, and the exercises should be used several times daily.

The more important method is that by graduated exercise in overcoming successively higher prisms, bases out. The following is the usual mode of treatment: The amount of exophoria is noted, the abduction and adduction is then measured, followed by the measurement of the convergence-stimulus adduction. This is obtained by coaxing the patient to overcome as strong a pair of prisms, with the bases out, as possible in the following manner: A pair of prisms just a little stronger than the normal power of adduction are placed in the trial-frames; these will, of course, cause diplopia for the distance, but not, as a rule, at the near point. The patient is then requested to fix his gaze on a mark made on a card (a cross or a dot seven or eight mm. in size), which is held at the reading distance or nearer. The card is then gradually withdrawn to a small gas-jet, the size of a candle-flame, about six meters from the patient's chair, the patient endeavoring and being encouraged to maintain a single image all the time. When this point is reached, the patient can transfer his gaze and fuse the double image of the flame instead of the mark on the card. This manœuvre is then repeated with stronger pairs of prisms until the limit of adduction is reached. It will generally be found that a pair of 10° or 15° prisms is as much as can be overcome at first, but if the exophoria is not too great, it is seldom that, after a few trials, a patient can not fuse the image of a candle-flame at 20 feet with this handicap.

The examiner should then prescribe a pair of prisms, bases out, suiting the strength to the indications, giving slightly less than the

full amount of adduction. It is of great importance to have the prism set in a well-adjusted frame. Figure 44 shows the ordinary interchangeable prism-frame.



FIG. 44.—PRISM-SPECTACLES FOR OCULAR GYMNASTICS.

The patient is instructed to place himself 20 feet from a flame, and endeavor to fuse the double image; if, as is usual, it is impossible for him to fuse at this distance, he must approach the flame until he gets the single image, then walk backward, keeping his gaze steadily fixed on the flame, until he reaches his starting-point. This is much more difficult for the patient than having some one withdraw the marked card from the near point to the flame; so that whenever feasible it is preferable to call in the assistance of a second person, particularly in the earlier days of this treatment. This assistant, unfortunately, is not always available. If the image is still single, the patient is told to hold it steadily so for about a quarter of a minute, then to raise the glasses and gaze at the flame with naked eyes for the same length of time, and repeat this ten or twenty times three times a day. The patients are instructed to continue this exercise for a week. During the first few days complaint may be made that the exercise is difficult and tires the eyes, but before the week is over it becomes easy. At the next visit the strength of the prisms is increased and the exercise continued at home, and at each succeeding visit an addition of about five degrees may be prescribed until the patient can, without the slightest trouble, overcome a pair of 25° or 30° prisms. Patients can sometimes be educated to overcome a combined prism-strength of over 100° . In such cases the ability of convergence is remarkable. An arrangement may be effected with an optician to lend prisms and make the necessary changes for a very moderate charge, and the patient is thus saved the expense of buying a whole outfit of

glasses that would be useless to him after a few weeks.

In moderate degrees of exophoria, or in cases in which there is no exophoria, but a lack of power of convergence, the symptoms disappear after the second week; but this is no indication to stop treatment, for unless the adduction is forced up to 50° , or 40° at least, the trouble is likely to return; if the patient can overcome a pair of 25° prisms, the cure is probably permanent. The higher the degree of insufficiency, the more necessary does it become to force up the power of convergence.

Insufficiency of adduction is not necessarily accompanied by exophoria; it is not usual, but still quite possible, to find a lack of converging power in cases of esophoria.

Occasionally a case of divergent strabismus may be cured by prism exercise; but a partial tenotomy of the external recti, one or both, may accelerate the cure and save much valuable time. It is a safe rule to follow, never to over-correct by a tenotomy, and to follow up the operation immediately with prism exercise,—“not to wait for the tenotomized muscle to unite in its new position and later on contract, but stimulate the internals to fight and push their advantage to victory while their opponents are nursing their wounds.” (Bennett.) Much, however, can be done without operation, and many a nervous woman will go through months of treatment rather than submit to the slightest cutting procedure.

It often happens that in cases of mixed muscular defect, by correcting the ametropia and properly exercising the adduction with prisms, not only is the adducting insufficiency remedied, but general muscular balance is restored and all the asthenopic symptoms relieved.

Hyperphoria is often thus relieved. If it persists despite this treatment, it must be treated by correcting prisms, base up or base down, ground in the ametropic correction, or by tenotomy. It is not uncommon to find that hyperphoria increases when it is corrected by prisms. Tenotomies are often unsuccessful, as the hyperphoria may return after a few months. The defect is likely innervational, and not anatomic.

High esophoria is rare, and the low defects seldom cause distressing symptoms. Esophoria should be treated by prescribing a strong ametropic correction, the use of correcting prisms, or by tenotomy and advancement. Prism exercise is of little use, as there is no stimulus in man to cause bilateral divergence. Sometimes prolonged mydriasis is helpful by suspending accommodation and, hence, convergence.

STRABISMUS.

Synonyms.—Heterotropia, or manifest squint.

Varieties.—The difference between strabismus and insufficiency is only one of degree. In strabismus the muscular insufficiency is uncorrected, the squint is manifest, and diplopia is produced. However, strabismus may be only periodic, as when the patient is fatigued or the systemic condition weak; or it may be present only when the patient looks at distant objects or accommodates for near-work.

Concomitant strabismus is a variety in which there is equal movement of the eyes, but one eye deviates on account of some defect in the musculature.

Paralytic strabismus is due to paralysis of an ocular muscle, and when the eyes are turned toward the paralyzed muscle, one eye is deficient in movement. This form will be fully discussed in the section on ocular paralysis.

Spastic squint is a term applied by some authors to cases in which deviation is caused by spasmodic contraction of one muscle. It is very rarely, if ever, present, and must result from some peculiar central irritation.

Alternating strabismus is fixation with either eye, the other eye deviating. Part of the time one eye squints and part of the time the other eye is at fault. It occurs when the vision is nearly equal in the two eyes, or when one eye is used for near-work and the other for distance.

Monolateral or constant strabismus is the name given to those cases in which the squint is always in the same eye.

Internal strabismus, or convergent squint, is deviation inward of one or both eyes, and is usually due to the increased convergence of an ametropic eye. The converging eye is usually highly hyperopic. Homonymous diplopia is produced.

External strabismus, or divergent squint, is a deviation outward of the visual axis of one or both eyes, and in most cases is due to insufficiency of adduction rather than to overaction of the abductors in an ametropic eye. The diverging eye is usually highly myopic. Crossed diplopia is produced.

Disadvantages.—When there is uncorrected deviation of one eye, diplopia results. To overcome this anomaly of vision, one eye is thrown out of use and the image suppressed, and if this amblyopia

is untreated for any length of time it gradually increases until the affected eye may become practically blind. Before the eye is turned out of use and the amblyopia exanopsia developed becomes discommoding, asthenopic symptoms are caused by the struggle for perfect binocular fixation. In long-continued convergent squint the temporal half of the retina being continually unstimulated, loses its sensibility; in such cases there is sometimes a quite accurate simulation of hemianopsia. This condition we have named *squint hemianopsia*. The cosmetic disadvantage of squint needs no discussion here.

Diagnosis.—Ordinarily, strabismus is apparent on simple inspection. However, we can not depend on the symmetric situation of the cornea, as it sometimes happens that the visual axis is to one side of the center, and an eye is thought to squint which is really properly directed for perfect binocular vision. The cover-test is reliable for the simple diagnosis of strabismus. The patient is told to fix his vision on an object and the fixing eye is then covered, and immediately the other eye will turn into position and fix while the other deviates.

The movement of the sound eye when covered is called *secondary deviation*. In *concomitant strabismus* the sound eye makes a movement in its deviation equal to that made by the squinting eye in its effort to fix. In *paralytic strabismus* the paralysis in the affected eye prevents full movement, and the *secondary deviation* is always greater than the primary squint. The *primary* and *secondary deviations* may be measured by marking on the lids the boundaries of the corneæ before the test, and the boundary of the cornea of the affected eye when attempting to fix, and the boundary of the cornea of the sound eye diverging under cover. The markings on the lid of the squinting eye show the primary deviation, while those on the lid of the other eye show the secondary deviation.

In paralytic squint there are :

- (1) Contraction of the field of vision.
- (2) Secondary deviation greater than the primary.
- (3) Disturbance with double images.

In concomitant squint there are :

- (1) Displacement of the field of vision, but no contraction.
- (2) Secondary deviation equal to the primary.
- (3) No disturbance with double images.

It often happens that there is horizontal as well as lateral squint,

and to study properly the exact character and degree of deviation we must try to compel recognition of the double images which are received; unfortunately, after some time the image in the squinting eye becomes suppressed, and it is very difficult to get the patient to recognize two images; but by placing a deeply colored glass before the fixing eye its image is so modified that the false image which is ordinarily suppressed may be recognized by the squinting eye.

Treatment.—As strabismus is often due to ametropia, or more commonly anisometropia, the first object should be to correct the refractive error in both eyes and to strive to bring the squinting eye into function by the blinder-exercise, in the manner described under the treatment of anisometropia. The muscular insufficiency should be treated by systematic exercise, at first by the thumb-exercise, and afterward with prisms. Periodic squint is particularly amenable to this treatment. In young children in whom there is a tendency to strabismus, the constant use of a weak solution of atropin in the sound eye will often bring the other eye into function and correct the squint, or it may be necessary to completely paralyze the accommodative effort for some time by using the mydriatic in both eyes.

When, however, binocular vision can not be obtained by the foregoing procedures, an operation must be resorted to. For internal strabismus, tenotomy of the internal recti is indicated. For external strabismus, tenotomy alone of the external recti or in conjunction with advancement of one or both tendons of the internal recti may be necessary. In regard to the relative indications of tenotomy and advancement it should be remembered that in concomitant squint with relaxed tendons we should perform advancement, and with tense tendons we should perform tenotomy. However, it is sometimes necessary to advance an apparently tense tendon and regulate a tenotomy by subsequent advancement. The great difficulty with tenotomy is that, despite the most careful and assiduous static and dynamic testing and operative dexterity, we can not be absolutely sure of the exact effect of the operation after cicatrization and contraction are completed. Advancement seems to offer more definite results.

PARALYSIS.

Varieties.—Suspension of the function of a muscle or a set of muscles constitutes true *paralysis*; impairment of the function alone

is called *paresis*. One muscle alone may be paralyzed, or a set of muscles may be affected, or there may be total paralysis of all ocular movement.

Total ophthalmoplegia is paralysis of all the ocular muscles, due to some destructive cerebral lesion.

External ophthalmoplegia indicates paralysis of the external muscles of the eye—the four recti and the two obliques. It is an occasional symptom of locomotor ataxia.

Internal ophthalmoplegia, or paralysis of the ciliary and pupillary muscles, is very rare, but partial internal ophthalmoplegia often follows an attack of diphtheria. We generally speak of this partial paralysis of the internal muscles as paralysis of accommodation, which is discussed in another section of the book.

Paralytic strabismus may also be divided and classified according to the nerve involved.

Paralysis of the third or oculomotor nerve causes paralysis of the muscles of the lid (ptosis), and paralysis of the superior, inferior, and internal recti and the inferior oblique. The manifestations of such paralyzes are inability to move the eye from its central position inward and upward, and hence divergent or vertical squint with crossed and more or less vertical diplopia. There are also mydriasis and loss of accommodation.

Paralysis of the sixth or abducens nerve produces convergent squint and homonymous diplopia, due to a loss of power in the external rectus, which is supplied by this nerve.

Paralysis of the fourth nerve is manifested by loss of power in the superior oblique muscles, causing imperfect movement of the eye down and out, and hence diplopia and slight convergent squint.

According to A. Graefe, the proportionate frequency is as follows:

- 32 per cent., isolated paralysis of an external rectus;
- 16 per cent., isolated paralysis of a superior oblique;
- 8 per cent., isolated paralysis of one of the four remaining muscles;
- 44 per cent., combined paralysis of all these four remaining muscles in one or both eyes.

Symptoms of paralysis of an ocular muscle are marked and significant. The objective symptoms are limitation of movement of the affected eye on the side and in the direction of a paralyzed muscle. This limitation can generally be perceived when the patient holds

his head still and attempts to follow the movements of the physician in various directions. If the paralysis is slight, it may not be recognized objectively. Another significant objective sign is the tendency of the head to be inclined obliquely, in a characteristic position for each form of paralysis. The deficiency in the affected muscle is partly corrected and the diplopia controlled by keeping the head turned toward the side of the affected muscle.

Subjective Symptoms.—Diplopia, occurring when the patient looks at an object situated within the sphere of action of the paralyzed muscle. The two images of an object seen in the median line are more widely separated when the object is moved in the direction of the action of the paralyzed muscle. The image seen by the sound eye is the true image, and that seen by the affected eye the false image. A study of the relative position of the two images enables us to determine the special muscles or set of muscles paralyzed.

Vertigo, nausea, headache, and incorrect estimation of position in space are disagreeable symptoms of ocular paralyses. As the patient forms incorrect location of objects, his gait is often uncertain.

Special diagnosis of the ocular palsies depends upon the relative position of the images in diplopia. To determine the eye and muscle affected, we must remember that the loss of motility and diplopia increase upon the side of the paralyzed muscle. The image of the affected eye is always found on the side opposite that to which the cornea is turned. A ready method is to tell the patient to look straight at a pencil, and to follow the movements given it, until two images of the pencil are seen. Then one eye is covered, and according to which image disappears, we know whether there is crossed or homonymous diplopia, and the relative position of the two images will give us an idea of the muscles paralyzed. To aid in the diagnosis we append a tabulated arrangement of the conditions in paralysis of the ocular muscle, modified after Landolt, showing the nature and position of the images and other important correlated details.

Causes.—The lesion directly causing the paralysis may be a primary affection of the nerves themselves, or may be situated in the cerebral centers from which the nerves originate. Syphilis and tubercular meningitis are probably the most common causes. Of the infectious diseases, diphtheria is most active in causing ocular paralyses, which, however, in these cases are more manifest in the *internal muscles of accommodation*. Influenza, rheumatism, typhoid

fever, and diabetes have also been mentioned as causes. Poisons, like nicotin, alcohol, lead, the ptomaines, carbonic oxid gas, and exposure to cold have all been reported as causes. Orbital tumors and abscesses, exophthalmic goiter, aneurysm, cerebral hemorrhage, and fractures at the base of the brain may cause paralysis by pressure.

Prognosis.—The duration of the paralysis is more or less chronic. In the most favorable cases several months are required for a cure. The prognosis is favorable when a paralysis is a sequel to diphtheria, some mild injury, or transient intoxication. Ocular paralysis associated with locomotor ataxia in the early stages is likely to disappear as the disease progresses. The prognosis is uncertain when the true nature of the causative disease can not be made out. In cases of long duration, muscular atrophy may occur. The prognosis is bad when the paralysis is discovered to be the result of some grave spinal or cerebral lesion.



Treatment.—Treatment should be directed to the removal of the cause and the relief of the symptoms. Syphilis yields to mercurials and iodids and diaphoresis. Meningitis must be treated in the usual manner. Diabetes demands dietary and hygienic treatment. Paralysis of rheumatic origin require the salicylates, colchicum, and other ordinary rheumatic therapeutics. Diphtheric palsies generally disappear with healthy bodily nutrition and the best tonic treatment. The influence of mercuric chlorid should never be overlooked. Both the galvanic and faradic currents are sometimes of value. For the relief of the diplopia it is well to occlude the unsound eye from vision, either by a bandage or an opaque disc. The simple patch is the least cumbersome occlusive bandage. In all cases we must remember that a long period of diplopia and its consequent distressing symptoms will elapse before a cure can be effected. If the paralysis continues in spite of all treatment, we may try to remedy the patient's discomfort by prisms, but these are rarely of value. In cases beyond the possibility of cure in which strabismus has developed, tenotomy or advancement may be performed to relieve the disfigurement. In cases of secondary contracture an attempt should be made to oppose the development of the contracture by stretching the antagonist of the paralyzed muscle, by seizing the overlying tissues with fixation forceps and strongly rotating the eye several times toward the side of the paralyzed muscle.

Nystagmus is involuntary oscillation of the eyeball resulting in spas-



PARALYSIS OF THE OCULAR MUSCLES.



The black figure represents the image of the left eye throughout. The light figure, that of the right eye. (Modified after Landolt.)

The Muscle.	Limitation of Motion.	Direction of the Affected Eye.	THE IMAGES.	POSITION OF THE IMAGES.		Direction of the Sound Eye during Fixation of the Paralyzed Eye.	Position of the Face.	REMARKS.
				Paralysis of the Left.	Paralysis of the Right.			
Rectus externus.	Outward.	Inward. No inclination of vertical meridian.	<p>Homonymous. The images are upon the same plane and parallel; their distance apart is increased by the patient directing his gaze to the side of the affected eye. The dividing line between single and double vision is, in the upper part, somewhat inclined toward the affected eye; in the lower, toward the sound one.</p>			Inward.	Turned upon its vertical axis toward the affected eye.	Pathologic convergence becomes clearer in looking downward, divergent in looking upward.
Rectus internus.	Inward.	Outward.	<p>Crossed. On the same plane and parallel. Their distance apart increases when the patient looks to the side of the sound eye and upward. In looking upward and to the sound side, the image of the paralyzed eye is a little lower than the other, and its upper part is inclined inward. In looking downward and to the sound side, the image of the paralyzed eye is higher and its upper part inclined outward. The line between single and double vision is inclined to the vertical, with its upper part toward the sound side.</p>			Outward.	Turned upon its vertical axis toward the affected eye.	

<p>Rectus superior.</p> <p>Upward and a little inward.</p> <p>Downward. In looking upward, downward and outward.</p>		<p>Upward.</p>	<p>The upper lid of the paralyzed eye is slightly elevated in looking upward. In paralysis of the rectus superior or inferior, the deviation is particularly shown in the position of abduction.</p>
<p>Rectus inferior.</p> <p>Outward.</p> <p>Upward and outward.</p>		<p>Downward and slightly outward.</p>	<p>One image is above the other and slightly crossed, especially in the upper half of the visual field. The image of the affected eye is above the other, and its upper part is inclined away from the image of the sound eye. The difference of elevation increases upon looking upward and inward. The lateral distance decreases in looking either to the right or to the left. The obliquity of the images increases in looking toward the sound side. The line between single and double vision is inclined to the horizontal from above, and from the side of the sound eye downward and toward the affected eye.</p>

PARALYSIS OF THE OCULAR MUSCLES.—(Continued.)

The Muscle Paralyzed.	Limitation of Motion.	Direction of the Affected Eye.	THE IMAGES.	POSITION OF THE IMAGES.		REMARKS.		
				Paralysis of the Left.	Paralysis of the Right.			
				Direction of the Sound Eye during Fixation of the Paralyzed Eye.	Position of the Face.			
Obliquus superior.	Downward and outward. In complete paralysis of this muscle, rotation downward is lessened.	Upward and inward. Vertical meridian is inclined outward, especially in looking downward.	The images are one above the other and homonymous, especially in the lower half of the field. The image of the paralyzed eye is below, its upper end inclined toward the image of the sound eye. Their perpendicular distance apart increases by looking downward and toward the sound side. The lateral distance is decreased by looking to either side. The obliquity increases toward the side of the affected eye. The image of the affected eye appears to be nearer than the other. The line between single and double vision is inclined toward the horizontal from above, and the sound side downward and toward the paralyzed eye.			Downward and inward.	Downward and inward to the sound side. To avoid this position of the head, the patient holds the object above and to the sound side.	In paralysis of either obliquus, the act of looking upward or downward is always accompanied by a convergence caused by the exclusive action of the recti muscles. Divergence is observed in the paralysis of the recti. The inclination of the images is reversed. In paralysis of either obliquus the vertical deviation toward the nose, and obliquity to the temple, is increased; the reverse takes place in paralysis of the recti.

Obliquus inferior.	Upward and outward.	Downward and inward.	<p>The images are one above the other and homonymous, especially in the upper half of the field. The image of the paralyzed eye is above, and its upper end turned away from that of the sound eye. The perpendicular distance increases in looking upward and inward. The lateral distance increases in looking upward and outward. The obliquity of the two images increases upon the side of the paralyzed eye. The line of division between single and double vision is inclined to the horizontal, and the end corresponding to that of the affected eye is above the other.</p>		Upward and inward.	Outward and slightly inclined toward the sound side.	The maximal elevation and intermediate positions result from the combined actions of the superior and external recti.
Recti, obliqui, levator palpebrae superior, ciliary, and iris circular.	Inward, upward, downward, and intermediate positions.	Outward.	<p>Crossed. The image of the paralyzed eye is a little above that of the sound; its upper end is inclined to that of the sound eye, and it seems to the patient that it is nearer him than the other one is. The perpendicular distance is increased by looking upward, and likewise the obliquity. This is decreased by looking downward and to the affected side. The lateral distance is increased by looking to the sound side.</p>		Outward.	Inclined to the sound side and slightly raised.	The affected eye is somewhat prominent. Ptosis of the upper lid, mydriasis, ophthalmoplegia interna.

modic jerking movements of the eye, not interfering with the voluntary movements, but accompanying them. It is the result of defective coordination. The involuntary movements may be horizontal or vertical, oblique, or rotations about the visual axis. Internal squint is a frequent accompaniment, and there may be simultaneous shaking of the head.

The commonest form of nystagmus is that following some deficiency of vision in both eyes, beginning in childhood, particularly amblyopia the result of the destructive changes of ophthalmia neonatorum and of retinitis pigmentosa. It also exists in microphthalmus, albinism, and some varieties of congenital cataract. The disease may be found in miners who constantly strain their eyes in the darkness. Nystagmus from cerebral disease is only of symptomatic significance. It is especially important in the diagnosis of multiple sclerosis.

Treatment beyond simple rest and the relief of the distressing symptoms is of little value. It must always be remembered that there is a possibility of improving the visual acuity and modifying the disease by correcting lenses. The prognosis of the nystagmus is never encouraging, even under the most favorable circumstances.

OPERATIONS ON THE OCULAR MUSCLES.

Tenotomy.—The eye should be thoroughly cleansed and rendered aseptic. The section of the tendon is best performed under cocaine or other local anesthetic, as in general anesthesia the result can not be seen during the operation. The lids are held apart by an eye-speculum. (Fig. 45.) The eye is turned in a direction away from the muscle to be divided, and held by fixation forceps. (Fig. 46.) A fold of conjunctiva lying over the muscle is grasped with the fixation forceps, and a short vertical incision is made about four mm. from the corneal margin through the conjunctiva and capsule of Tenon. The conjunctiva is freed from the underlying tissue by means of a pair of blunt scissors or other blunt instrument; when the muscle is exposed, a strabismus hook (Fig. 47) is passed underneath the tendon, which is raised from the globe and divided close to the sclera with a pair of blunt scissors. (Fig. 46.) If complete tenotomy is desired, any fibers remaining undivided may be caught by a strabismus hook and

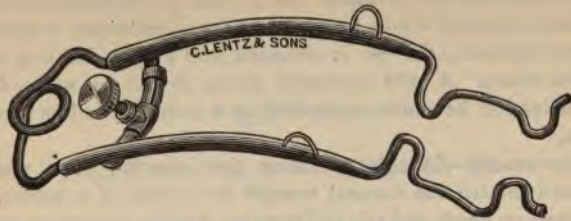

FIG. 45.—SPECULUM.



FIG. 46.—FIXATION FORCEPS.



FIG. 47.—STRABISMUS HOOK.

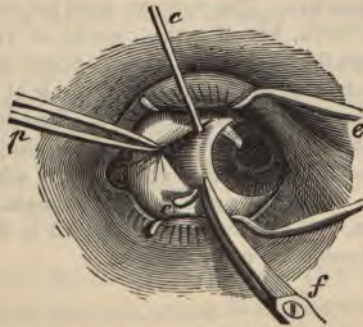


FIG. 48.—SECTION OF THE TENDINOUS INSERTION.

cut through with the scissors. As a rule, no conjunctival stitch is necessary, although it may be used in cases of tenotomy of the interni. After the operation the eye is cleansed and a light dressing applied for a few hours. A mild antiseptic lotion should be ordered. The divided tendon becomes reattached at a point beyond its former insertion.

Advancement.—In this operation the insertion of a muscle is advanced toward the corneal margin by means of a suture. It is performed on weak and relaxed muscles, and in connection with tenotomy of the opposing strong muscle. The process of separating the tendon is the same as in tenotomy, and the tendon is lifted away from the globe by a strabismus hook. A needle threaded with silk of sufficient strength is then introduced in the tendon near the upper margin, from behind forward, and a sufficient number of millimeters back of the insertion to produce the requisite advancement. Another suture is similarly introduced at the lower border of the tendon. With the blunt-pointed scissors the tendon is then divided near the sclera, and the needle of the upper suture is carried beneath the conjunctiva to a point near the upper corneal margin, where it is then brought through, leaving the ends of the thread hanging free. In a like manner the needle of the lower suture is brought out near the lower corneal margin. The ends of the two sutures are then tied together, the threads being drawn tight enough to slightly overadvance the tendon beyond the point of necessity. This latter precaution is taken to counteract the diminution of advancement with healing. If desired, the tendon may be divided last, after the sutures are brought out through the conjunctiva. The surgeon must be careful not only to pierce the conjunctiva, but also the capsule of Tenon, as sutures would tear through the conjunctiva alone. Some surgeons excise a small portion of the conjunctiva and the capsule of Tenon, between the insertion of the tendon and the cornea. The sutures should be removed on the third or fourth day. A mild antiseptic solution may be used as a lotion. Various other operations of advancement have been suggested. Landolt's capsular advancement is a deservedly popular operation, and the student is referred to the modern textbooks for a full description of its technic.

PART II.
DISEASES OF THE EYE.

DISEASES OF THE EYELIDS.

Anatomy.—The eyelids are composed of the following structures, from without inward: Skin, areolar tissue, fibers of the orbicularis palpebrarum, tarsal cartilage, fibrous membrane, Meibomian glands, and conjunctiva. The upper lid is the larger, and is freely movable; it is furnished with a special muscle, the levator palpebræ superioris. The angles which correspond to the junction of the upper and lower lids are called the *canthi*. The inner canthus is prolonged toward the nose, and the two lids are thus separated by a triangular space called the *lacus lacrimalis*. The *lacrimal papilla*, or *caruncle*, is a small conic elevation on the outer margin of each lid, at the commencement of the lacus lacrimalis. The *tarsal cartilages* are thin plates of fibrocartilage, about an inch in length, and give the main support to the lid. The cilia or eyelashes are attached to the free edge of the lids. The upper cilia are more numerous, and curve upward, while the lower curve downward. An excellent idea of a vertical section through the upper eyelid is given in figure 49.

The *Meibomian glands* are situated on the inner surface of the eyelids, between the tarsal cartilages and the conjunctiva. Their ducts open on the free margin of the eyelids, and furnish a sebaceous secretion which prevents adhesion of the lids and epiphora. The *muscles of the lids* are the orbicularis palpebrarum, corrugator supercilii, tensor tarsi, and the levator palpebræ.

DISEASES OF THE SKIN OF THE LIDS.

HERPES ZOSTER OPHTHALMICUS is an acute febrile disease accompanied by herpetic eruptions extending over the superficial

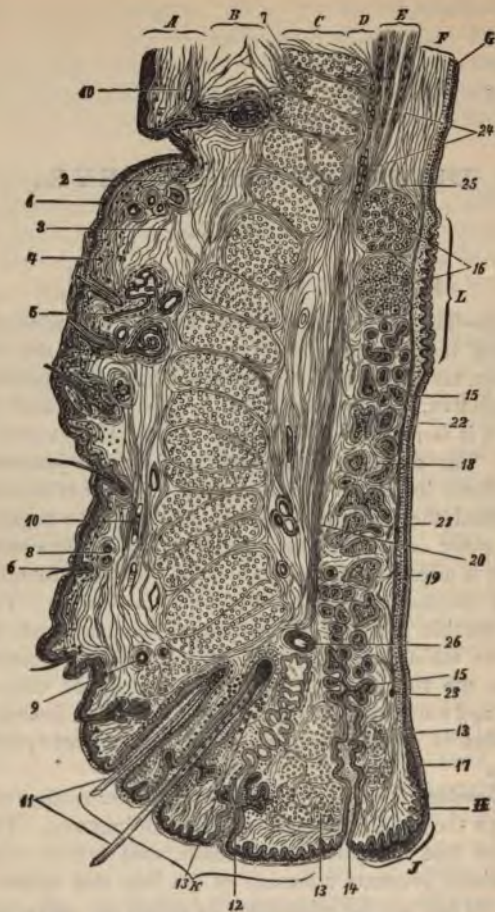

FIG. 49.—VERTICAL SECTION THROUGH THE UPPER EYELID.

A. Cutis. 1. Epidermis. 2. Corium. *B.* 3. Subcutaneous connective tissue. *C.* 7. Orbicularis muscle. *D.* Loose submuscular connective tissue. *E.* Insertion of H. Müller's muscle. *F.* Tarsus. *G.* Conjunctiva. *J.* Inner, *K'* outer, edge of the lid. 4. Pigment cells. 5. Sweat-glands. 6. Hair-follicles. 8, 23. Sections of nerves. 9. Arteries. 10. Veins. 11. Cilia. 12. Modified sweat-glands. 13. Circular muscle of Riolan. 14. Meibomian gland. 15. Section of an acinus of the same. 16. Posterior tarsal glands. 18, 19. Tissue of the tarsus. 20. Pretarsal or submuscular connective tissue. 21, 22. Conjunctiva, with its epithelium. 24. Fat. 25. Loosely-woven posterior end of the tarsus. 26. Section of a palpebral artery.

distribution of the supraorbital, supratrochlear, and infratrochlear nerves. The nerve twigs supplying the cornea may be affected. The symptoms are local inflammation, herpetic vesicles, and general systemic involvement. The eruption does not pass the middle line of the nose and forehead. The prognosis is good, provided the cornea is not extensively involved. The treatment consists in relieving the pain, and the application of powders and ointments for drying up the vesicles and softening the scabs.

ECZEMA OF THE LIDS begins in vesicles and pustules, and dries in scales and crusts. All the various forms of eczema are seen in this location; the chief subjective symptom is itching. The treatment consists in protecting the skin and greasing the lids with some simple ointment, such as yellow oxid of mercury gr. j, vaselin ℥ij. The scales should be moistened with warm oil and removed.

FURUNCLES AND PHLEGMONS of the lid should be incised, and dressed with antiseptic precautions.

HEMORRHAGE INTO THE LID, commonly known as "black eye," may be the result of traumatism directly to the lids or adjacent structures, or may be due to injury to remote parts, such as fracture of the skull. In ordinary "black eye" the extravasation and discoloration follow soon after the injury. "Black eye" appearing several days after an injury points strongly to fracture of the orbit. Certain dyscrasias, such as scurvy, may cause hemorrhage into the lid by diapedesis. Treatment is usually unnecessary; the extravasated blood will disappear in a few weeks. If seen early, cold applications may be ordered to prevent extravasation. Later, hot compresses promote absorption and relieve pain; lead-water and laudanum, or a pressure bandage, may be ordered. Incising very puffy lids is not to be recommended, as the swelling soon disappears without treatment, or, at least, on the application of heat and pressure. For cosmetic effect, the discolored lid may be painted a flesh tint.

EDEMA OF THE LIDS is a regular accompaniment of any inflammatory process therein. If there is inflammation of the bulbar conjunctiva or of the cellular tissue of the orbit, edema of the lid is a serious symptom. The treatment consists in opening any pustular formation about the lid, applying a pressure-bandage, or, as a last extreme, incising the lid.

NONINFLAMMATORY EDEMA OF THE LIDS is a sign of disease of the heart, kidneys, or liver. The general dropsy of Bright's disease is often first seen in the lower lids.

EMPHYSEMA OF THE LIDS may be the result of making a false passage in probing the nasal duct, or of fracture of the bones of the orbit or adjacent bones of the face, opening the nasal passages or sinuses. In such cases blowing the nose increases the emphysema.

DISEASE OF THE EDGES OF THE LIDS.

BLEPHARITIS is an inflammation of the free edges of the lids.

The synonyms are blepharitis simplex, blepharitis marginalis, blepharitis ciliaris, blepharitis ulcerosa, blepharitis hypertrophica, blepharadenitis, ophthalmia tarsi, tinea tarsi, sycosis tarsi, and eczema of the lid-edges.

Causes.—Uncorrected ametropia; eczema; some inflammatory process, such as conjunctivitis, keratitis, etc.; inflammation of the roots of the cilia; or the condition may be the result of strumous diathesis. The disease is said to accompany general disturbances of the sexual organs and syphilis. Lice are sometimes a cause. There is also reason to attribute it to special bacteria. Dirty children are very susceptible to blepharitis. Continued eye-strain undoubtedly lies at the bottom of many obstinate cases. Obstruction of the lacrimal apparatus and intranasal disease are causes not to be overlooked.

Symptoms.—The lid-edges are swollen and reddish, and may cause intolerable itching and soreness. There is a gummy and yellowish secretion in the lashes and on the skin near the lid-edge, which, when dried, deposits as scabs and crusts. The lids are glued together after being closed for some time, particularly in the morning. The eyes tire easily. The protean character of eczema may be present about the lid-edge, and possibly in other parts of the body. The cilia are often dwarfed or entirely absent, causing a disagreeable disfigurement. In the hypertrophic variety the lids may be everted, exposing the puncta lacrimalis and causing the tears to overflow, thus keeping up the condition, and, indeed aggravating it, as the edge of the lower lid soon becomes water-soaked. The most annoying sequel of *blepharitis* is *trichiasis*, a condition in which the lashes become misplaced and scratch the cornea, and which leads to actual entropion.

Treatment.—As this is a frequent affection, it is well to thoroughly

discuss the treatment. These cases are sometimes very obstinate, and despite all efforts at relief they cause the patient long years of discomfort, and produce a most annoying facial blemish. We should first of all search for one of the causes enumerated. It is advisable to examine the refraction of the affected eyes, and be sure that the lacrimal apparatus and nasal chambers are unaffected. Treat any possible cause. All the scales should be removed and the lid-edges kept clean and fresh. For this purpose warm water or a weak boric or bichlorid solution (1 : 5000) should be used. In the eczematous variety, bichlorid in itself is an efficient remedial agent. The local treatment by massage with a weak Pagenstecher ointment (gr. j to ʒij) is probably the best at our command. Ulcers may be painted with a two per cent. solution of silver nitrate. The treatment of the trichiasis consists in epilation of the distorted cilia, their destruction by electrolysis, or operation. Disease of the conjunctiva and cornea should be treated simultaneously with the blepharitis. The treatment of the sequels will be discussed separately.

HORDEOLUM OR STYE.—A furuncular or phlegmonous inflammation near the hair-follicles or margin of the lid. Eye-strain is a common cause.

Symptoms.—It begins with a pricking pain, soon followed by swelling of the affected lid. A tender hard spot is easily located by palpation, and may be inspected by raising the lid away from the eyeball, when a yellowish point will be seen.

Treatment.—If pus is seen, it should be let out, and, as a rule, the symptoms will usually subside immediately. To prevent recurrence, cleanliness and disinfection with a lukewarm bichlorid solution (1 : 5000) are demanded. A ten per cent. sulphur ointment may be used. Recurrence of styes is suggestive of refractive error or constitutional disorder, and the ametropia and general health should be looked after. Small doses of calcium sulphid are said to be efficient.

CHALAZION is a small tumor arising from an inflammation or closure of a duct of a Meibomian gland. It is the size and shape of a split pea, the convex side being toward the skin. It usually points toward the palpebral conjunctiva. It may be distinguished from hordeolum by its location, its chronic course, and noninflammatory symptoms. The conjunctiva is often red and spongy-looking, especially directly over the tumor. The skin over the tumor is freely movable, and normal in appearance.

Treatment consists in excising and curetting the tumor, under cocain, using a special forceps. (Fig. 50.) In excising through the conjunctiva, the scarification following an extensive excision may cause entropion, and a simple incision should be made in the direction of the gland, and curetting alone should be resorted to. In excising through the lid, an incision parallel to the edge of the lid is made over the chalazion, its capsule is opened, and the whole mass

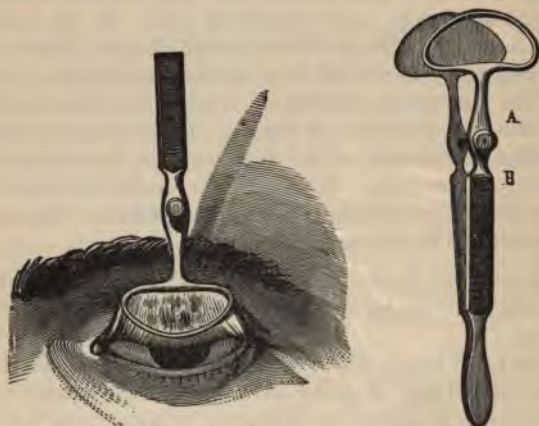


FIG. 50.—EXCISION OF CHALAZION, DESMARRES' FORCEPS.

excised and the cavity curetted or the sac dissected out. Suture of the wound is optional.

MALPOSITIONS OF THE LIDS AND LID-EDGES.

NARROWED FISSURE.—The normal palpebral fissure in the adult is 26 to 28 mm. long, and about one cm. wide. Narrowing of the fissure is either called *ankyloblepharon* or *blepharophimosis*. The first condition is an actual union of the external angle of the lids, and may be congenital or due to a cicatrix following a burn or an ulceration. *Blepharophimosis* indicates that a fold of skin covers the external angle, and results from a contraction of the skin of the lid after a chronic conjunctivitis.

Treatment of ankyloblepharon consists in an operation called canthoplasty. (Fig. 51.) The adhesions are dissected up, the external canthus split, and the external canthal ligaments cut, leaving a denuded V-shaped wound, the conjunctival edges of which are drawn together by sutures. Blepharophimosis may be corrected by cutting away the redundant skin and stitching the edges of the wound together.

WIDENED FISSURE is usually a cleavage of the external canthus due to an injury, after which union is not perfect. It is remedied by

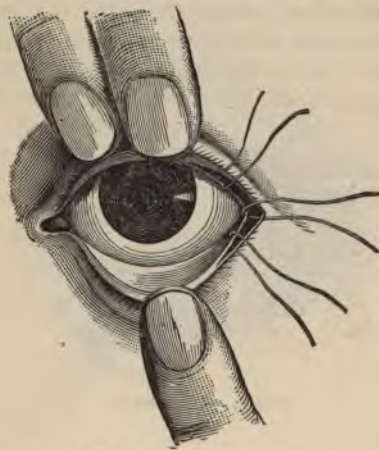

FIG. 51.—CANTHOPLASTY.

an operation called tarsorrhaphy, in which both edges of the lids are denuded and the raw surfaces sutured together.

LAGOPHTHALMOS is a condition in which the eyeball is so extruded that the lids can not be completely closed. The exposure of the eye following this condition is accompanied by the greatest danger to the cornea. Lagophthalmos may be due to staphyloma of the cornea, ocular or orbital tumor, or paralysis of the orbicularis muscle.

EXOPHTHALMOS is protrusion of the eye from the orbit, and may be due to increase in the bulk of the eye by disease, orbital cellulitis, an orbital tumor, a foreign body in the orbit, myopia, or probably

the accompanying sign of exophthalmic goiter. It may be present in a slight degree after tenotomy. If so marked as to cause deleterious exposure of the cornea, a modified tarsorrhaphy should be performed. Exophthalmos may cause blindness by excessive stretching of the optic nerve.

TRICHIASIS is a condition in which the cilia are misplaced or misdirected, and rub against the cornea, causing more or less corneal irritation. The condition may apply to all the cilia, or only a few may be misdirected. The common cause of trichiasis is trachoma, although blepharitis or any inflammation about the cilia may produce it. Cicatricial contraction after injury and operation is a cause. The treatment consists in curing the causative condition, and by epilation, electrolysis, illaqueation, excision, and plastic operation.



FIG. 52.—ENTROPION.

DISTICHIASIS is a condition in which there is a double row of cilia, one directed inward and one directed normally outward. The result of this condition is corneal irritation. The treatment is similar to that of trichiasis.

ENTROPION is inversion of the edge of the eyelid. (Fig. 52.) It results from cicatrization following trachoma, blepharitis, wounds, burns, etc. Blepharospasm and pressure from bandaging are causes. It should be distinguished from simple trichiasis, in which the cilia alone are displaced. In entropion the edge of the lid is wholly or partly inverted, as well as the cilia.

Treatment.—If spasmodic entropion is due to a faulty bandage, *such cause must be removed.* One end of a piece of adhesive plaster *fastened below the lashes* and the other end to the cheek may secure

relief. The classic operative measure for entropion is excision of a horizontal fold of skin parallel to the edge of the lid, with suture of the wound. Other operations are described in the following pages.

OPERATIONS FOR DISTICHIASIS, TRICHIASIS, AND CICATRICAL ENTROPION.—Electrolysis is performed by attaching the needle to the negative pole of the battery, the positive pole being placed on the temple; the point of the needle is thrust into the bulb of the lash, and the circuit closed. Destruction of the bulb is indicated by bubbles of gas about the needle. Each lash must be treated separately.



FIG. 53.—FLARER'S OPERATION FOR DISTICHIASIS.

Illaqueation is a name given to a method of changing the direction of misplaced cilia by withdrawing them, by a noose, through an opening in the adjacent tissue of the lid. Unfortunately, the eyelashes frequently regain their abnormal position by reason of their own elasticity.

Excision.—A V-shaped incision is made in the skin of the lid, including the misdirected cilia, the whole flap is excised, and the margin of the loss of tissue is drawn together with sutures. **Flarer's operation** (Fig. 53) consists in splitting the lid into two portions as far back as the ends of the hair-bulbs of the cilia. The anterior flap, containing the *hair-bulbs*, is then cut away by incision through the

skin from above. In cases involving the whole length of the lid, this operation is not advisable.

Transplantation.—The Arlt-Jaesche operation is performed by splitting the lid along the whole intermarginal edge for about five mm. deep, the anterior layer containing the orbicular muscle and the integument with all the hair-bulbs, and the posterior containing the tarsus and conjunctiva. A second incision is made about six mm. from the margin and parallel to it, extending the whole length of the lid. A third incision is made in a curved line from one end of the second incision to the other. The semilunar fold of skin thus formed is dissected off, and the exposed margins are brought together by

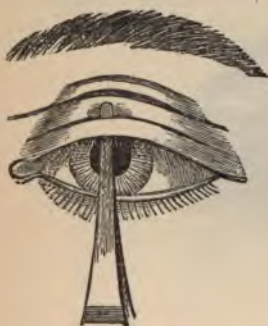

FIG. 54.



FIG. 55.

DIANOUX'S OPERATION.

sutures. The height of the curved incision is proportionate to the effect desired.

Dianoux's operation is performed by incising the integument to the cartilage only, in a line parallel to the lid-edge and about four mm. from it. On the intermarginal edge the lid is split between the cartilage and muscle until the knife meets the preceding incision at right angles to it, thus forming a bridge of lid-edge containing the cilia and their roots. Another and slightly longer line of incision is now made, parallel with the first one and about three mm. above it. The strip of skin between the two is dissected up in the middle and left detached at both ends. The bridge of the lid-margin is then drawn up and over the strip of loosened skin, and fastened by sutures to

the upper border of the highest incision, while the loosened strip is drawn down and stitched to the intermarginal edge. (See Figs. 54 and 55.) The objection to this operation is that occasionally the cutaneous hairs on the transplanted flap irritate the cornea, and these hairs, being much finer than cilia, are more difficult to remove.

Van Millingen's operation consists in splitting the eyelid, as in the Arlt-Jaesche operation, from end to end, sufficiently to produce a gap three mm. wide in the center and becoming narrower toward the canthi. Sutures are passed through folds of skin on the upper lid, which prevent the gap from closing. A strip of mucous membrane as long as the lid and about two mm. broad is cut out of the inner surface of the patient's under lip, and is slipped into the gap. Sutures are superfluous. In this operation the transplanted tissue, being mucous membrane, is free from the objectionable fine hairs.

Streatfield's operation and Snellen's modification of it consist in grooving the tarsus, and removing a wedge-shaped piece of skin, the length of the lid, and about two mm. from it. When the edges of the wound are brought together, the cilia are turned outward and into their normal position.



FIG. 56.—ENTROPION.

In von Graefe's operation an incision through the skin is made 3 mm. from the margin of the lid, and a triangular skin-flap is excised. The edges of the triangle are dissected up slightly, and brought together by three points of suture, while the horizontal incision is not sutured. The size, especially the width, of the triangular flap to be excised is proportional to the looseness of the skin. This operation is recommended in senile entropion, when excision of a horizontal piece of skin or the application of subcutaneous sutures are not sufficient.

Hotz's operation for the same condition consists in excising the skin and muscle down to the tarsus, some four to six mm. from the lid-edge, laying bare the tarsus and drawing the two skin-margins together and holding them until union is effected, thus giving—

fulcrum for the everting force of the cicatrix and skin, which Hotz thinks is wanting in other methods.

ECTROPION is eversion of the lid. (Fig. 56.) It is not attended by the severe symptoms of entropion. Epiphora, with the consequent eczema which follows it, is the worst symptom. In severe cases the whole lid may be everted, leaving the conjunctiva unprotected, a condition popularly called *blear eye*. This deformity results from relaxation of tissues in old age, or paralysis of the orbicularis, cicatricial changes due to injuries, burns, etc., and follows chronic conjunctivitis, blepharitis, or other inflammatory conditions about the lids. The scars of lupus and syphilis are occasional causes. Both lids may be affected.

Treatment.—For eversion of the puncta—slitting the lacrimal canal and clearing the nasal duct may give relief. Any discernible cause should be treated. Mild antiseptic lotions should be used on the denuded surfaces. The patient should be instructed to wipe the eye from below upward, thus tending to reduce the eversion by a sort of massage.

OPERATIONS FOR ECTROPION are designed to raise the under lid or to stretch it out horizontally. The usual plastic operation is excision of a V-shaped piece of skin below the lid-margin. The edges of the denuded triangular area are brought into position by sutures, as depicted in figures 57 and 58. Snellen's sutures are threads entered on the conjunctival side of the lids from above downward, and brought out on the skin at about the level of the edge of the orbit, the ends being knotted over pieces of tubing or a ball of cotton. In cicatricial ectropion, the first step is to sever the adhesion between the lid and the bone, and to cover the remaining scar by a transplanted flap or by skin-grafting.

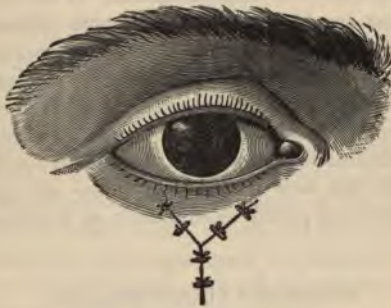PTOSIS is drooping of the upper lid. It may result from any effusion or inflammation weighing down the upper lid. Excessive deposits of fat in the lid may cause it to droop. Ptosis also results from injury to or paralysis of the levator palpebræ muscle.

The treatment of ptosis consists in removing the cause if possible. In paralysis of the levator muscle, strychnin and the galvanic current are useful. Several ingenious lid-elevators have been devised for the relief of this condition. Operative interference has for its object the removal of a piece of the skin of the upper lid, or the insertion of

silver wire to hold the lid up. The tendón of the levator muscle may be advanced, or the tarsus may be sutured to the temporal muscle. The patient can often relieve ptosis by learning to use the



The Incision.



The Sutures in Position.

FIGS. 57 AND 58.—OPERATION FOR ECTROPION.

temporal muscle, or by throwing the head backward in order to see better.

A simple and effective operation for ptosis consists in passing a stout silk ligature vertically under the skin from the eyebrows to the margin of the lids, and firmly tying the ends. The noose formed in

this manner is tightened every day until it has cut its way through the confined tissues; the resultant cicatrix draws the lid to its normal position.

CLONIC SPASM OF THE ORBICULARIS is called **NICTITATION**, and is really frequently-repeated involuntary winking. It may be associated with hysteria, chorea, or general neurasthenia; in fact, it may be a symptom of nearly any reflex neurosis. It often becomes a habit. Clonic spasms of the orbicularis sometimes appear after the use of eserine. In persons doing considerable eye-work, there is doubtless some uncorrected error of refraction. The treatment of this condition consists in administering remedies alleviating the nervous condition, or in correcting the ametropia.

BLEPHAROSPASM is a tonic contraction of the orbicularis, often affecting both eyes. It is generally reflex, from irritation of the conjunctiva or cornea by a foreign body or from inflammation of some kind in these regions. It is a disagreeable accompaniment of phlyctenular conjunctivitis and keratitis, and corneal ulcer. Often the irritation caused by an inverted eyelash is the seat of the trouble. Photophobia often leads to blepharospasm. If no local cause is discernible, we must suspect ametropia, or some reflex from a distant irritation, such as intranasal disease, or even a decayed tooth. The spasm may be of central origin. Treatment of the cause is the only way to attack the spasm. Pressure on the facial nerve at its exit at the styloid foramen is said to stop the spasm. Galvanism is useful. By all means examine the refraction. In children with phlyctenular disease, plunging the face under cold water will often cause the orbicularis to relax and permit examination of the corneæ.

CONGENITAL ANOMALIES.

COLOBOMA is a perpendicular fissure of the lid, usually the upper one. It is congenital, and is often associated with hare-lip or cleft-palate.

EPICANTHUS is a condition in which a perpendicular fold of skin extends from the nose over the inner canthus. It causes the nose to look broad and the fissure to appear small. It is a racial characteristic of the Mongolians. When congenital, it may gradually disappear. Excision of a piece of skin of the nose, called *rhinorrhaphy*,

is sometimes performed for cosmetic reasons. Eye-glasses with stout nose-pieces are sometimes used for cosmetic effect.

NEW GROWTHS.

EPITHELIOMA should be distinguished from **chancere** of the lid by its slower development, and the absence of syphilitic symptoms elsewhere. In syphilis there is early involvement of the lymph-glands at the angle of the jaw, and edema is more apparent. The treatment of epithelioma consists of prompt and thorough incision, and, if the wound is large, a subsequent skin-grafting. In some cases a careful curetting will suffice, but on the whole excision is safer. The application of pure formalin is a substitute for curetment. After excision, the conjunctiva and skin should be sutured separately.

OTHER TUMORS of the lids are warts, angiomas, and xanthomas. All of these may be removed with ease and impunity. Angiomas are bluish-red in color, while xanthomas are dirty yellow.

DISEASES OF THE LACRIMAL APPARATUS.

Anatomy and Physiology.—The *lacrimal apparatus* consists of the lacrimal gland, its excretory duct, the puncta lacriminalia, the lacrimal canaliculi, the lacrimal sac, and the nasal duct. (Fig. 59.)

The *lacrimal gland* is situated at the upper and outer angle of the orbit. It is invested in a dense, fibrous membrane, and is in contact superiorly with the periosteum. The secretion of the lacrimal gland is carried by 8 to 12 small ducts, which run for a short distance beneath the conjunctiva, and open upon its surface by a series of pores, about $\frac{1}{10}$ of an inch apart, situated in a curved line, a little above the upper border of the tarsal cartilage.

The *lacrimal canaliculi* commence at minute openings in the *lacrimal papillæ* of the inner canthus of the lids, called *puncta lacriminalia*. They are directed inward to the lacrimal sac. The superior canaliculus at first ascends, and then, turning suddenly inward, forms an abrupt angle with the nose. The inferior canaliculus descends at first and then turns abruptly inward. These canaliculi are dense and elastic tubes about twelve mm. long, and act as capillary tubes, being constantly open.

The *lacrimal sac* is lodged in a groove of the lacrimal bone, and when distended may be compressed through the lid. It is lined with mucous membrane, and is really a dilatation of the nasal duct.

The *nasal duct* is a bone-canal, about $\frac{3}{4}$ of an inch long, through

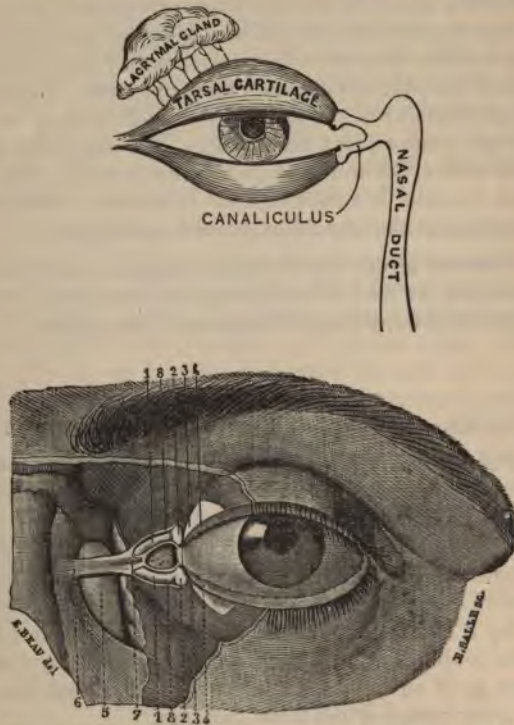


FIG. 59.—RELATIONS OF THE EYE AND THE LACRYMAL EXCRETORY APPARATUS.

- 1, 1. Canaliculi. 2, 2. Puncta lacrimalia. 3, 3. Inner extremity of tarsal cartilage.
4, 4. Free borders of lids. 5. Lacrimal sac. 6. Attachment to maxillary bone of superior tendon. 7. Bifurcation of lacrimal sac. 8, 8. Two branches.

which the tears are conveyed from the eye to the nose. It is lined with ciliated mucous membrane, continuous with that of the inferior *meatus of the nose* into which it opens. Its direction is downward, outward, and backward.

Vessels and Nerves.—The lacrimal gland is supplied with blood from the lacrimal branch of the ophthalmic artery, and with nerves by the lacrimal branch of the ophthalmic and orbital branch of the superior maxillary.

The forces at work in the passage of tears from the gland to the nose are capillary attraction as furnished in the canals, gravity causing them to fall over the conjunctiva and through the canals, and muscular movement in winking. In winking, the tear-sac is expanded by the traction of the muscles, and the tears sucked into it. Contraction of the sac is passive, due to the elastic action of tense tissues.

The *lacrimal secretion*, called *tears*, is a faintly alkaline fluid containing about one per cent. of solids, of which a small part is proteid in composition. The lacrimal secretion is slightly antiseptic, and contains sodium chlorid.

DISEASES OF THE LACRIMAL GLAND.

ABSCESS AND INFLAMMATION of the lacrimal gland are very rare. The diagnosis depends on the presence of swelling or the signs of abscess in the region of the gland. An abscess should be incised, and any inflammation of the gland treated with a mercurial ointment or potassium iodid.

NEW GROWTHS are mostly adenoids. A chloroma is a malignant greenish tumor which sometimes attacks the lacrimal gland. Sarcoma and carcinoma are also occasionally found in this location. However, disease of the lacrimal gland is such a rare affection that many men of vast experience have never seen a case. The treatment of a tumor is prompt excision.

DACRYOPS is a condition in which a lacrimal duct becomes occluded and the lumen full of secretion, forming a bluish tumor on the outer upper fold of the conjunctival sac. It should be opened with a fine needle.

FISTULA of the lacrimal gland is usually the result of injury or operation. The fistula should be connected with the conjunctival sac, after which the dermal opening soon heals.

DISEASES OF THE LACRIMAL PASSAGES.

The all-important sign of diseases of the lacrimal passages is the *overflow of tears, or EPIPHORA*. The first purpose of treatment in such

cases is to clear the passages so that the tears will run into the nose. However, we must remember that in oversecretion the tears will run over the cheeks. Thus, on a windy day or in emotional weeping, there is not only extra secretion into the nose, causing sniffing, thus proving that the nasal duct is patulous, but, in addition, epiphora. Oversecretion of tears may be due to conjunctivitis, keratitis, an especially irritable trigeminus nerve, uncorrected ametropia, and a number of other causes.

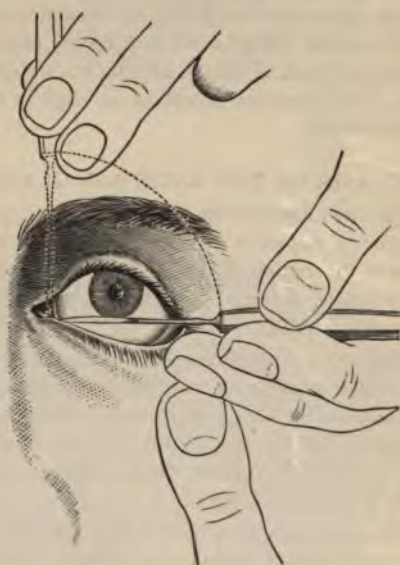

FIG. 60.—SLITTING THE CANALICULUS.

AFFECTIONS OF THE PUNCTA LACRIMALIA.—Eversion of the puncta, or even of the lower punctum alone, will cause epiphora. We should immediately endeavor to correct any malposition, as the sequences of epiphora are very serious, eventually leading to ectropion. *In cutting operations on the lids, or in the application of caustics, we must always be careful that the puncta are not involved, as eversion, with its annoying sequelæ, will result if this precaution is not taken.*

Although it is always well to preserve the puncta, which have a physiologic function of importance in keeping solid, irritating bodies from the nasal duct and lacrimal sac, it is often necessary, for immediate drainage, to slit the canaliculus involved. This simple operation is performed as follows (Fig. 60): The lower lid is drawn downward and outward, and slightly everted by the thumb of one hand, while the probe point of a canaliculus knife (Fig. 61) is introduced vertically with the other hand. When the knife is well inserted into the canal, its point is turned inward and slightly backward, reaching the inner wall of the lacrimal sac. During this manœuver the edge of the knife is turned toward the conjunctiva, and the whole length of the canaliculus is divided, close to the mucocutaneous junction, by bringing the knife up boldly from the horizontal to the vertical position. In dividing the upper canaliculus, the upper lid is made tense, and the knife is introduced into the upper punctum and passed into the sac in a direction downward and inward. If the canaliculus is very small, a fine-pointed conic probe should first be used to dilate it. There are various modifications of the operation—



FIG. 61.—WEBER'S STRAIGHT CANALICULUS KNIFE.

with a groove director, fine scissors, etc. The wound should be examined at short intervals, and kept open with a probe.

AFFECTIONS OF THE CANALICULUS.—Obstruction of the canaliculus is often due to a foreign body, such as an eyelash, which not only occludes the canal, but scratches the cornea. The obstruction may be due to a stone in the canaliculus, called a dacryolith. Polypi of the canaliculi may grow so luxuriantly as to protrude from the puncta. The treatment in these cases is to remove the foreign body if it protrudes from the punctum; or, if the obstruction is due to a stone or polypus or there is absolute stenosis or obliteration of the canaliculus, it should be promptly slit to its full extent.

AFFECTIONS OF THE LACRIMAL SAC.—The lacrimal sac is lined with mucous membrane, which is subject to inflammation and catarrh like any other mucous membrane. Any condition which obstructs the free passage of the tears predisposes to disease of the sac, and

particularly if the obstruction is in the nasal duct. The sac also becomes diseased by extension of any inflammatory process from the nose. Inflammation of the sac leads to *blennorrhœa*, and this, in its turn, leads to *dacryocystitis*, or abscess of the lacrimal sac. The contents of a constantly suppurating tear-sac are very infectious, and although the patient may go on for many years with epiphora, conjunctivitis, and crusting of the lids in the morning, yet the infection may be so severe as to set up an inflammation which will eventually destroy the eye. The slightest abrasion of the cornea may become infected and a dangerous ulcer result.

Dacryocystitis.—The initial symptoms are conjunctivitis, local pain, and redness of the skin. The distended sac soon appears as a tumor involving the tissues near the inner canthus of the eye. If left to itself, this tumor may ulcerate and the pus burrow through the skin, establishing what is known as a lacrimal fistula, which may remain a lifetime, and become in itself a safeguard against a new attack. Often the distended sac loses its elasticity and becomes a permanent tumor, called *hydrops sacci lacrimalis*. The diagnosis between simple *catarrh*, *blennorrhœa*, or *hydrops*, is easily made by emptying the sac with pressure of the finger: in *catarrh*, a watery secretion appears at the punctum; in *blennorrhœa* there is more or less pus; in *hydrops*, the sac may empty into the nose and no secretion appear. *Dacryocystitis* and fistula need only be seen to be recognized.

Treatment.—Any nasal affection should be corrected, and a free passage of tears into the nose established. The latter is generally effected by the passage of sounds. Bowman's sounds or probes (Fig. 62) are usually employed. The canaliculus should be slit, and the following day the passage of probes commenced. It is optional which canaliculus is used, but the upper is shorter and easier to sound.

To pass a lacrimal sound or probe, the point of the sound must be passed along the floor of the slit canaliculus to the nose, until it is felt to strike against bony resistance; the sound is then rotated until it points downward; keeping close to the inner wall of the sac, the sound is then firmly pushed along. Under ordinary circumstances, if the probe is in the right position, it will pass along the nasal duct with a moderate pressure; undue resistance to a small probe indicates stricture of the duct or a false passage; in either case the pressure should be used cautiously. If the sound has passed easily, it should be left in position several minutes; in fact, it may remain a half hour

often to advantage. If the passage has been tight, the sound should be immediately withdrawn. The sounding of the passage should be repeated every three or five days, and the size of the sounds progressively increased. In some cases it is well for the patient to wear a leaden stylet constantly for several days. Theobald and others advocate the use of very large lacrimal sounds. A special probe-pointed knife has been devised for slitting strictures of the nasal duct. In treatment of the lacrimal passages we should resort to frequent syringing, various astringent and antiseptic preparations being used. Weak solutions of silver nitrate are of benefit in cases of blennorrhœa.

Recently there has been a reaction against promiscuous probing in lacrimal disease. The results are generally unsatisfactory and the case is often protracted. As a substitute there has lately been advised

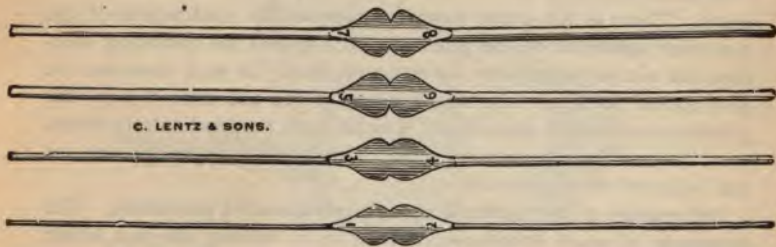

FIG. 62.—LACRIMAL SOUNDS.

copious syringing with a fountain-syringe attached to a hollow No. 4 Bowman's probe. The canaliculus need only be split half way, and in some cases not at all. Boric acid and weak antiseptic solutions are used in the irrigations.

A simpler treatment of lacrimal obstruction, which dispenses with mutilation of the puncta and canaliculus and probing, consists in the following manipulations:

First empty the sac and canaliculi by dextrous pressure, and cleanse the eye and palpebral pockets of the unhealthy material. Then cant the patient's head back and to one side, or have him lie so that a teaspoonful of liquid will be held in the depression formed by the nose, orbital border, and superior maxilla. Fill this space with a weakly antiseptic solution. The solution we use is composed, to the ounce of distilled water, of boric acid, ten grains; common

salt, three grains; chlorid of zinc, one grain—all deeply tinted with pyoktanin-blue, and doubly filtered after long standing. With the little finger again slowly empty the sac and canaliculi by pressure, and then, as slowly lessening the pressure, allow these spaces to refill, by suction and capillary attraction, with the solution under which the puncta are submerged. Again, in half a minute, empty the canaliculi and sac by pressure, but this time beginning the pressure from the canthus toward the nose and downward, so as to force the antiseptic solution downward into the duct. These alternate emptyings and refillings of the sac may be repeated several times and as often as desirable to meet the indications of the case. It will usually be found that the sac will soon become healthy and that pressure upon it will not cause regurgitation of morbid material through the puncta.

A certain number of cases, however, will not yield to this treatment. There is too great stenosis or spasmodic contraction of the muscular sphincter of the punctum, etc., so that the cleansing solution can not be forced into the sac and duct. In such cases we are accustomed to insert one sharp point of the iris scissors into the punctum and snip it open about $\frac{1}{8}$ of an inch, perpendicularly downward toward the conjunctival fold. This gives a larger opening for the indrawal of the solution.

Obliteration of the lacrimal sac is a questionable procedure. The treatment of acute dacryocystitis consists in voiding the pus, either through the canaliculus or by an incision through the skin. The fistula is treated like other fistulous passages, and will generally heal if the obstruction to the passage of tears is removed. Repeated irrigation, syringing, and probing are the important after-treatments of all these affections.

DISEASES OF THE CONJUNCTIVA.

Anatomy.—The conjunctiva is the mucous membrane of the eye, and when the lids are shut, it forms a closed sac. (Fig. 63.) The part covering the eyeball is called the *bulbar conjunctiva*, and the part reflected over to the inner surface of the lids is called the *palpebral conjunctiva*. The part forming the fold between the two is called the *fornix*, and the regions between the two palpebral and bulbar portions are called the *sulci*, or palpebral sinuses. The superior sulcus

is the deeper. The conjunctiva covering the cornea is thin, closely adherent, and contains no blood-vessels. Upon the sclerotic it is thicker and less adherent; but upon the inner surface of the lids it is somewhat closely connected, and exceedingly vascular. The conjunctiva is directly continuous with the mucous membrane of the mouth and nose, and is sympathetically affected by disease of these cavities and their continuations. Inflammation of the gastrointestinal and pulmonary tracts may cause congestion of the conjunctiva. The conjunctiva is traceable into the lacrimal gland above, and into the lacrimal sac below. Immediately to the outer side of the caruncle is a

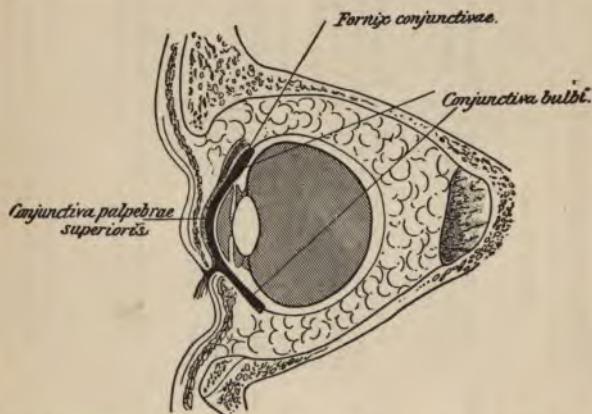


FIG. 63.—CONJUNCTIVAL SAC (IN HEAVY BLACK, EXAGGERATED FOR SAKE OF CLEARNESS).—(After Merkel.)

slight duplicature of the conjunctiva, called the *plica semilunaris*. This is analogous to the rudimentary third lid or nictitating membrane of birds.

Diagnosis of Superficial and Deep Congestion.—To distinguish congestion of the conjunctival vessels from engorgement of the deeper vessels, we must bear in mind that the conjunctival vessels are tortuous, easily movable upon the sclera, are bright red, and may be traced along their entire course. In deep congestion the individual vessels can not be seen clearly, and run straight, and there is a bluish-red or violet injection.

DIFFERENTIAL DIAGNOSIS OF OCULAR INFLAMMATIONS.

The student should become thoroughly familiar with this table, as it embodies the most important points in the diagnosis of inflammatory conditions of the eye.

SYMPTOMS.	ACUTE CONJUNCTIVITIS.	ACUTE IRITIS.	KERATITIS.	ACUTE GLAUCOMA.
COLOR OF THE INJECTION.	Red, but less marked near the cornea.	Red; most marked near the cornea; bright zone of ciliary redness.	Rose-pink; conspicuous near the cornea.	Dark red.
VESSELS.	Superficial, tortuous, and irregular in distribution; freely movable.	Vessels run deeply and straight toward the corneal margin (ciliary region); not movable with conjunctiva.	Vessels run straight, and break into fine network in the immediate vicinity of the cornea.	Vessels widely distributed and dilated.
CONJUNCTIVA.	Thickened; vessels on the everted lid concealed in the general redness; easily thrown into folds.	Not much thickened; distribution of vessels on everted lids easily seen; not easily thrown into folds.	No thickening in simple keratitis.	No thickening.
SECRETION.	Hypersecretion of mucus seen in flakes; lashes matted; lids glued together in the morning.	No considerable hypersecretion of mucus.	Free lachrimation, but no hypersecretion of mucus.	No hypersecretion.
PAIN.	Not severe; smarting and burning; sense of sand in the eye; no tenderness.	Neuralgic and paroxysmal; worse at night; eyeball tender.	Moderate, but constant; sticking, lancinating; no tenderness of the eyeball.	Same character as in iritis, but more severe; not markedly worse at night.

PHOTOPHOBIA.	None, unless the cornea is affected.	Slight.	Severe and conspicuous.	Slight.
IRIS.	Normal.	Thickened, dull-looking, and, if light, discolored.	Normal.	Slightly discolored.
PUPIL.	Normal.	Small, sluggish, or fixed; irregular, not round.	Normal.	Dilated, sluggish, and greenish in color.
CORNEA.	Clear, if not secondarily affected.	Clear, unless corneal complications.	Clouded or opaque, obscuring the view of the pupil and iris.	Haziness; or in extreme cases steamy, like ground glass.
TENSION.	Normal.	Normal, or in ciliary involvement possibly slightly increased.	Normal.	Increased. (The important diagnostic feature.)
ANTERIOR CHAMBER.	Normal.	Normal.	Normal.	Shallow; iris and lens pushed close to the cornea.
CORNEAL SENSITIVENESS.	Normal.	Normal.	Increased.	Diminished (if touched with a wisp of cotton).
VISION.	Little change.	Dimmed, but not suddenly.	More or less impairment by corneal turbidity or opacity.	Suddenly and greatly diminished at the onset of the attack.
FIELD OF VISION.	Normal.	Normal.	Possibly limited by opacities.	Contracted.
ATROPIN AND ESERIN.	No effect on condition.	Atropin soothes; eserine aggravates pain.	Little immediate effect; both beneficial ultimately.	Atropin greatly aggravates the pain; eserine mitigates all symptoms.

As the gravest mistakes in the treatment of ocular disease by the inexperienced are due to a lack of knowledge of the salient and characteristic features of each of the different types of ocular inflammation, the following table (a modification of that of Bruns) is given on pages 162 and 163. The student is urged to review carefully this table before reading farther on diseases of the eye; remembering, however, that the typical signs of each condition are often more or less modified or absent, and that combinations of the different processes are frequently present.

SIMPLE CONJUNCTIVITIS.

HYPEREMIA OF THE CONJUNCTIVA is a symptom rather than a disease, and is generally the sequence of some irritation of the membrane, such as foreign body, weeping, heat or cold, exposure to light, etc. The treatment consists in removing the cause, which, in many instances, is a small foreign body which the patient has been unable to locate.

CHRONIC HYPEREMIA, OR DRY CATARRH, of the conjunctiva is caused in many ways. Irritation by dust, peculiar to such occupations as those of the miller, stone-mason, etc., is a fruitful source. Any derangement of the secretion or excretion of the tears is a cause. Firemen, puddlers, and others who work continually in a strong light; students, using their eyes excessively and often by poor light, and persons subject to any kind of eye-strain, may be afflicted with dry catarrh of the conjunctiva. The symptoms are itching and sensation as of a foreign body or heat in the eye. The distress increases toward evening, showing the indubitable presence of eye-strain. The upper lids feel heavy, and there may be blepharospasm in a mild degree. Upon examination, the lids are seen to be congested, there is a uniform redness, and all the accompanying signs of a catarrhal condition. At the sides and over the tarsus there are often nodules looking like raw flesh. There is no pathologic secretion.

The treatment consists in correcting any error in refraction or muscular trouble. To avoid the deleterious influences of some occupations, protective glasses may be ordered. If there is exposure to sunlight, smoked glasses should be prescribed. Astringent and *antiseptic applications* are advisable. Boric acid, gr. x to $\bar{3}$ j, is *the solution most commonly employed*; zinc sulphate and zinc

chlorid, gr. j to $\bar{3}$ j, are useful. Camphor water is often used as a base for eye-drops. Alum may be used in solution of gr. vj to $\bar{3}$ j. In case the catarrh is persistent, applications every second day of a two per cent. solution of silver nitrate are recommended. Touching the eyes with a pencil of alum is sometimes of use. Often, in old and refractory cases, a variation in the astringent employed is of ad-

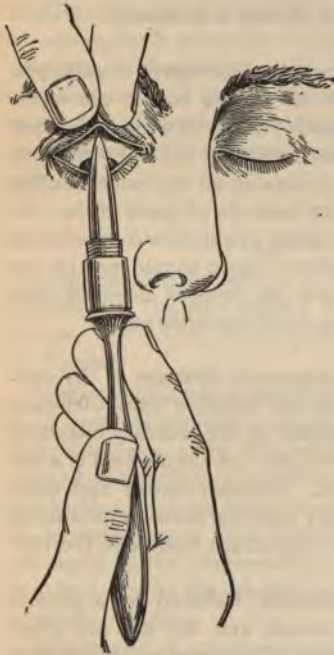

FIG. 64.
METHOD OF MAKING APPLICATIONS TO THE UPPER SULCUS.

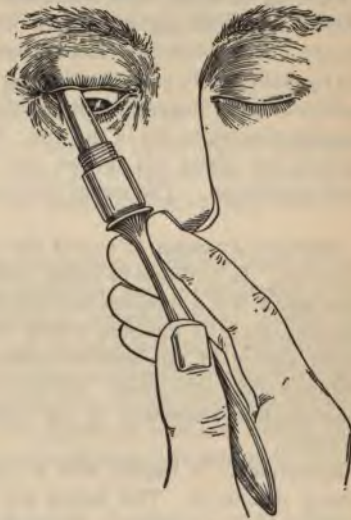

FIG. 65.

vantage. Irrigation with hot or cold lotions of plain water is always advisable; besides the pleasant local effect, absolute cleanliness is assured.

Figures 64 and 65 illustrate the simplest and best mode of applying the alum pencil, which also dispenses with the annoyance of everting the upper lid. The skin over the middle of the upper lid is grasped

between the thumb and forefinger of the left hand, pulling the lid upward and away from the globe. The patient is told to look downward, and with the right hand the pencil is inserted deep into the upper sulcus, especially in the direction of the canthi, where the greatest congestion is usually located. The advantage of this method over eversion of the lid lies in the fact that the remotest depths of the sulci can be reached. In applying the pencil to the lower sulcus, simple eversion of the lid by tension is all that is necessary.

HOW TO USE EYE-DROPS.—When ordering astringent or antiseptic lotions for the eye, we should instruct the patient how to use them. He should lie on his back without a pillow, and with a clean dropper several drops should be placed immediately in the eye; the lids should not be violently closed, thus squeezing all the lotion out, but the eyeballs gently rotated, diffusing the lotion in all parts of the conjunctival sac. Instead of wiping the lotion out, it should be allowed several minutes to dry in the eye. Surplus lotion should not be put back in the bottle, but thrown out, and the dropper cleansed after each instillation. The use of eye-cups is not recommended.

SIMPLE CATARRH is one of the commonest diseases of the conjunctiva. In addition to being due to the irritative causes already mentioned, it is a frequent accompaniment of the ordinary infectious diseases, such as measles, scarlet fever, etc. A simple cold is a frequent source of conjunctival catarrh. Tobacco smoke and other irritant vapors are causes. Finally, any bacterial invasion producing inflammation elsewhere in the body may cause trouble in the conjunctiva.

Symptoms.—It begins with a hyperemia, followed by a profuse watery discharge. The lashes are matted, and the lids are glued together in the morning. There is profuse lachrymation, called forth to remove the excessive secretion from the conjunctiva, and, as the capacity of the drainage-apparatus is overtaxed, epiphora results. Aside from the ordinary symptoms of conjunctival congestion, the patient is annoyed by the optic defects caused by flakes of mucus on the cornea. Photophobia is sometimes distressing. Again, the *symptoms* are worse in the evening. The patients complain that *they have a sensation as of sand in the eye, and they are inclined to prolong the irritation by rubbing.*

The course of the disease varies from one week to an indefinite period.

Treatment.—Ordinary measures with astringent and antiseptic washes will alleviate the symptoms; but when there is a hidden cause, the process continues. Occupation, habits, and continued eye-strain are causes which are often left uncombated. In such cases local treatment is of little avail. Anointing the lids with pure or medicated vaselin every evening should be insisted upon. Generally, the use of an astringent is advisable,—alum, tannic acid, silver nitrate, and zinc sulphate are those most used. No rule can be given for the strength and frequency of the applications. Each case needs a special treatment. In intractable cases the application of a 50 per cent. solution of boroglycerid in glycerin, once or twice daily, is often of great service.

PURULENT CONJUNCTIVITIS.

Purulent conjunctivitis is a term used to cover highly infectious processes of the membrane. It varies according to the mode of infection. The most serious cases are generally due to the gonococcus of Neisser.

SIMPLE BLENNORRHEA of the conjunctiva is distinguished by redness, swelling, profuse yellowish secretion, and involvement of the lids, skin, and even the neighboring lymph-glands. Crests are formed at the edges of the lids, and pseudomembranes on the internal surface. In the height of the inflammation the conjunctiva may be so swollen as to push between the lids, constituting what is called chemosis of the conjunctiva. The discharge is at first watery, then purulent, and in the subsidence of the disease it is similar to that of a simple catarrh.

GONORRHEAL CONJUNCTIVITIS.—This disease is due to infection by the gonococcus.

Symptoms.—For the first twenty-four hours it may present only the symptoms of a simple catarrh. The violence of the onset is dependent upon the stage of the inflammation from which the inoculation was made. Inoculation from an eye in the full stage of suppuration may cause violent symptoms in six hours. The conjunctiva becomes congested and the lids are edematous and swollen. As the disease progresses the signs of inflammation are more marked. There

is grayish infiltration of the conjunctiva, intense pain, and the lids become so swollen as to hide the eye, and project as boggy tumors from the face. Between the lashes drops of yellow pus ooze. Upon opening the eye pus gushes forth, and the examiner must be cautious that none of the contagious secretion falls upon his face. In fact, it is well to wear protective glasses in examining such patients. At this stage the bulbar conjunctiva is scarlet in color and so chemosed that the cornea may be completely hidden. The disease attains its height on the third or fourth day, and slowly subsides, the catarrh usually running a course of from four to six weeks. Indications of abatement of the process are diminution of discharge and signs of inflammation and the gradual return of the normal wrinkles of the eyelids as the swelling subsides. There are often severe constitutional symptoms. The temperature is elevated, and the pain may be agonizing.

Complications.—The most frequent complication is corneal ulceration, which is due in great part to the deprivation of vascular supply to the limbus from the constriction of the conjunctival vessels by the great chemosis of the conjunctiva. The ulcers may not perforate, but when they heal, they leave a disastrous scar in the cornea. Prolapse of the iris may follow perforation. If the perforation is small, it may heal with synechial attachments of the iris; if large, anterior staphyloma may occur. The whole cornea may slough and panophthalmitis result, leaving nothing but a sightless stump.

Diagnosis.—A history of gonorrhoea or discovery of the gonococcus in the secretions at the onset of the disease makes the diagnosis positive. At its height the disease will be plainly recognized.

Prognosis is always serious and is dependent entirely upon the amount and location of corneal involvement. Large peripheral leukomata are less dangerous to vision than small central ones.

Treatment.—The patient should be put to bed, and if one eye is sound, it should be protected with a Buller's bandage. This contrivance consists of a watch-glass held in place before the eye by a perforated adhesive bandage. It must cover and exclude the sound eye entirely, and must be impervious to the irrigations of the diseased eye. The attendants and patient must be cautioned against the infectious nature of the discharge, and all compresses must be *destroyed*. Iced compresses should be applied to the eye almost *continuously*. This treatment eases the pain, limits exudation,

and prevents violent swelling and conjunctival edema, so fatal to the cornea. If the cornea ulcerates early, cold must be discarded for hot compresses, wrung out in water from 115° to 120°. An atropin solution may be instilled unless the perforation is quite peripheral.

The next important part of treatment is thorough irrigation at short intervals. This is the fundamental principle in the therapeutics of all autoinoculable and purulent processes. Remove the self-multiplying cause, and assist nature to combat the original infection. Strong antiseptic applications are usually unnecessary. The infection soon gains access to tissues possibly beyond the reach of local antiseptics, and, moreover, such substances in germicidal strength have generally a devitalizing effect on the tissues, and this we wish to avoid. Let cleanliness be nature's assistant, and only when the curative process is delayed, should stimulating applications be used.

In view of its importance, it is unfortunate that thorough and repeated irrigation of the sulcus is seldom effected. To cleanse at intervals of a half-hour every portion of an infected conjunctiva in an active state of purulent inflammation is a difficult task. The lids are tense and swollen. The palpebral and bulbar conjunctival surfaces are, as it were, glued together, making the depths of the sulci almost inaccessible. The pain in the manipulation is intense. A child vigorously resists all efforts to open the lids, and even in the case of adults it is often quite impracticable under these circumstances. To be effectual, irrigation must be thorough, and in the active inflammatory stage it should be repeated at least every half-hour. What might be called the "golden rule" in these cases is: *Without careful irrigation, all other treatment is unreliable.*

In the irrigation of the eyes we have had little mechanical or instrumental assistance offered us. Some surgeons advise against the use of any hard substance in irrigation, as they fear injury to the cornea in manipulation. Of the few methods suggested, that of Kalt, with the irrigation-tube, seems to have produced the best results.

We have had made an instrument which seems to answer all the requirements of a satisfactory sulcus-syringe (Fig. 66). It is, in all essentials, simply a lid-retractor, such as every one uses in operations and in examining inflamed eyes, etc., but made hollow for the passage of a liquid to all parts of the sulcus. It is perforated at its edges and on both its bulbar and palpebral surfaces, to allow the passage of liquid through and about it. The small holes are depressed to

prevent occlusion by close contact with the conjunctiva, and both surfaces are grooved to allow a drainage flow from the sulcus. There are no ragged edges or protrusions to injure the eyes, and there is no danger of the fluid being squirted back into the operator's eyes. The retractor may be made of metal or hard rubber. It is best used with a fountain-syringe, the pressure being regulated by the height of the reservoir above the patient's head, the current controlled by a stop-cock, or by pressure on the tubing near the retractor. The instrument is also adapted for adjustment to a hypodermic syringe, having a thread the same size as an ordinary hypodermic needle.

With this retractor-syringe the eye may be thoroughly washed at the shortest intervals, as there is little pain in its introduction. Twenty minutes constitute the shortest interval ever required. At least a half-pint of water should be used at each irrigation, and during the




FIG. 66.—COMBINATION LID-RETRACTOR AND SULCUS-SYRINGE.

cleansing the retractor should be moved about slightly in the sulcus. The liquid should be drained over the side of the face into a basin, care being taken that it does not enter the ear, nose, or mouth. This is particularly necessary in infants. Any solution may be used, although sterile water, or possibly a weak boric acid solution or permanganate of potassium, will be found effective. The fluid should be used at body temperature, unless for special reason the application of heat or cold is desired, which may be readily applied in this manner. The solution, gently run through the syringe, also offers an excellent substitute for wet-packs and fomentations in certain cases of ocular inflammation.

In addition to the irrigation, the lids should be everted, if possible, and brushed three times a day with a copious 50 per cent. solution of *boroglycerid in glycerin*. This solution may often be flooded into

the conjunctival sac without everting the lids. This substance has given us better results than the better known silver preparations. Silver nitrate (gr. x to ʒj) and its substitutes (such as protargol and argonin) are widely recommended. Sometimes the chemotic conjunctiva should be freely incised. As the disease subsides into a simple catarrh, the ordinary antiseptic and astringent treatment is instituted. In cases of corneal opacities, frequent massage with a weak yellow oxid ointment (gr. j to ʒij) is recommended. An iridectomy is often resorted to for optical purposes. An artificial pupil downward may give serviceable vision, although the lower part of the cornea is not always clear. The treatment of the other complications is discussed under their separate headings. In the course of the disease the pain may be so intense as to necessitate hypodermic injections of morphin in the temple. Constitutional and hygienic treatment is often necessary. Pure air, cleanliness, light diet, free bowel-movements, etc., are demanded. The rigorous treatment prevents the possibility of much sleep.

CONJUNCTIVITIS OF THE NEW-BORN (OPHTHALMIA NEONATORUM). This disease is analogous to the gonorrhoeal conjunctivitis of adults, although the symptoms are less violent, and the consequences not so severe. It is usually due to the gonococcus in the secretions of the parturient tract, although severe cases have been caused by the secretions of nonspecific vaginitis.

Symptoms.—The inflammatory symptoms are similar to those of a mild case of gonorrhoeal conjunctivitis in the adult. They appear between the first and third days of life. Later appearance strongly indicates postnatal infection. In lying-in hospitals the disease may be transferred from one infant to another, unless the proper precautions are exercised.

The course of the disease is shorter than adult gonorrhoeal conjunctivitis. Both eyes are usually involved.

The diagnosis is easily made by the appearance of inflammation of the eyes in a newly born child. A history of a vaginal discharge in the mother or urethritis in the father is confirmative evidence. Bacteriologic examination makes the diagnosis positive.

The complications are chiefly corneal ulcers, although destruction of the eye may result. If the ulcers do not perforate, the prognosis as regards the scars becoming more or less transparent, is much better

than in the adult affection. Perforating ulcers cause adherent leukomas, which are always great hindrances to vision.

Treatment.—As both eyes are usually involved, it is not necessary to protect one; in fact, this would be most difficult; but at all times care should be taken to avoid transference of secretions or irrigations from one eye to its fellow, as there is not always the same virulence of infection in the two eyes.

The *prophylactic treatment* consists: (1) If possible, in removing the disease from the mother before labor; (2) thorough disinfection of the vagina before labor, with solutions of creolin, carbolic acid, boric acid, salicylic acid, mercuric chlorid, or other antiseptic; (3) thorough cleansing and disinfection of the child's eyes as soon as the head is born. These precautions should be carried out in all suspicious cases.

Credé's method should be employed in all cases in hospital or mid-wife service, and in suspected private cases. In fact, there is a law to this effect in many communities. It consists of dropping a few drops of a two per cent. solution of silver nitrate exactly on the cornea of a child born of a mother who is suspected of vaginal infection. Other solutions have been suggested, but have no advantages over this simple method. We think, however, as a prophylactic measure this strength is greater than necessary, and liable to cause inflammation. A one per cent. solution, together with cleanliness, etc., seems sufficient until decided symptoms appear.

The routine treatment is practically the same as that of gonorrheal conjunctivitis: cold applications, frequent and thorough irrigation, the application of boroglycerid, silver nitrate, etc. At the first sign of corneal complication, hot compresses should be employed and atropin instilled. Massage with weak yellow oxid ointment is indicated for the corneal opacities. The child must be well nourished and kept clean and warm. Early operation is indicated if the opacities are central and dense. The sooner an artificial pupil is established, the better for the child's mental development. Of course, operation should be deferred a reasonable number of months while waiting for the opacities to clear up. In treating these cases, the physician himself should inspect the cornea, and make the applications at least once a day. Nurses or family attendants often fail to open the lids *sufficiently* to cleanse the culdesac and to administer the local *treatment*.

DIPHTHERIC CONJUNCTIVITIS is an extremely disastrous disease, due to infection of the conjunctiva by the Klebs-Loeffler or similar bacillus. There is a painful, board-like swelling of the lids, and a scanty, seropurulent or serous discharge. The ordinary constitutional symptoms of diphtheria may accompany the affection. The treatment does not differ from that of other purulent affections of the conjunctiva, except in the relief of pain by atropin and the ordinary diphtheric measures. Administration of the antitoxin is highly recommended by some authors. Disease of the cornea is seldom avoided in this affection, and the prognosis is very grave. Fortunately, the disease is rare in this country.

CROUPOUS CONJUNCTIVITIS differs from true diphtheric conjunctivitis in that it is characterized by a soft, painless swelling of the lids, and a membranous exudation on the surface of the conjunctiva. It must be remembered that the secretions of conjunctivitis of the new-born may take on a membranous appearance. The treatment is virtually the same as for other purulent infections of the conjunctiva. Caustics are contra-indicated.

FOLLICULAR CONJUNCTIVITIS.

Symptoms.—Follicular conjunctivitis is an inflammation accompanied by the formation of follicles or nodules in the conjunctiva (Fig. 67). It is more infectious than simple catarrhal conjunctivitis, and is more prone to relapses, although no cicatrices remain after the follicles disappear. The disease may be acute or chronic. The follicles can not be seen until the congestion recedes, when they appear in rows, glistening through the overlying membrane. Accompanying pericorneal injection is a precursor of shallow ulcers at the corneal margin. From its infectious character, a special germ is supposed to be the cause. It is distinguished from trachoma by the small secretion, absence of cicatrices, and appearance in the lower culdesac only.

The disease may be acute or chronic. The follicles can not be seen until the congestion recedes, when they appear in rows, glistening through the overlying membrane. Accompanying pericorneal injection is a precursor of shallow ulcers at the corneal margin. From its infectious character, a special germ is supposed to be the cause. It is distinguished from trachoma by the small secretion, absence of cicatrices, and appearance in the lower culdesac only.

Treatment should be first directed to measures to prevent the asso-

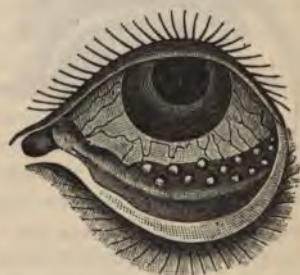

FIG. 67.—NODULES ON THE LOWER FORNIX IN FOLLICULAR CONJUNCTIVITIS.—(After Sichel.)

ciates of the patient from becoming affected. The secretion should be removed as it appears by sublimate solution. Applications of boroglycerid, blue stone, or alum may be of use. Smarting may be relieved by cold compresses. The conjunctiva may be cocainized and the follicles squeezed out with cilia forceps.

TRACHOMA, OR GRANULAR LIDS.

Definition.—A disease of the conjunctiva, characterized by the unrestricted formation of follicles, which, instead of being absorbed as in follicular conjunctivitis, produce permanent granular masses, spreading over the surface of the entire lid, and presenting, in extreme cases, the characteristic appearance of a bunch of grapes of a deep-red color (Fig. 68). The upper lid is generally first affected. Where the follicles are abundant, the conjunctiva is destroyed. Ulceration takes place, and the necrosed membrane is replaced by scar-tissue. The disease is chronic, and progresses many years, new nodules forming while others are ulcerating and cicatrizing. The bulbar conjunctiva is not usually involved.

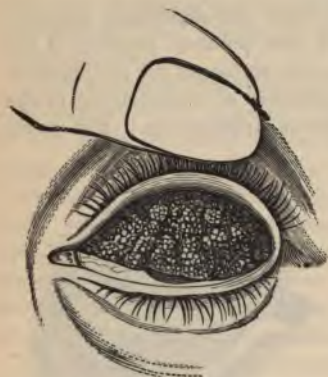

FIG. 68.—TRACHOMA (UPPER LID EVERTED).

Course.—The disease begins with conjunctivitis, followed by follicular formation and growth of vascular tissue over the cornea, due to friction of the roughened lid, causing keratitis and consequent corneal opacity. The upper third of the cornea is most affected, and there is a distinct line of demarcation between the healthy cornea and the vascular tissue, which never entirely disappears. This condition is called *pannus*, and will be fully considered under diseases of the cornea. The second stage of trachoma is ulceration of the follicles. The secretion, until now slight, becomes *mucopurulent*, and the follicles, instead of being distinct, have a *ragged appearance* and are ulcerated. The entire conjunctiva is

congested, and the lashes are matted together with the secretion. After some months the disease passes into the third stage—cicatrization. The granulations have now disappeared, there is little secretion, and the conjunctiva is no longer actively inflamed and rough, but is dry and dirty white, thickened, and rolled into fine folds. This atrophic condition is called parenchymatous xerosis. The entire lid is now shorter from above downward, so that the lids when closed gape to a slight degree, and are turned in. The lashes are sparse and irregular, and trichiasis results. Running parallel to the under surface of the upper lid and 2 mm. from it a thick scar is sometimes seen.

The subjective symptoms in the first stage are pain, itching and burning of the lids, lachrimation, photophobia, and asthenopia. Later on there is dimness of vision, which increases in the third stage. There are also the annoying symptoms caused by the inverted lashes.

Cause and Distribution.—Poorly nourished and scrofulous persons are most frequently affected. Unhygienic habits and contagion in crowded districts are marked factors in the production of the disease. Trachoma is rare in mountainous regions, and increases toward the lowlands. The peculiar susceptibility of some of the Continental emigrants is possibly due to their unsanitary habits, rather than to any inherent racial peculiarity of temperament. According to Burnett and others, negroes are particularly immune from trachoma.

There is unanimity of opinion as to infectiousness of trachoma, and, although there is an inclination to consider the disease as due to a special germ, the reports of bacteriologic investigation have not been harmonious.

Prognosis is unfavorable. The disease continues for many years, and there is rarely complete recovery. The dryness of the conjunctiva is very annoying, and by the irritation and exposure of the corneal epithelium, with consequent opacity, vision is affected. Entropion and trichiasis are disagreeable sequels.

Treatment.—The patient should be informed of the infectious nature of the disease, and warned not to wipe his eyes on public towels. To the strumous and poorly nourished, change of environment and constitutional treatment are of great value. The conjunctival sac should be washed several times a day with boric acid or a weak solution (1:8000) of mercuric chlorid. If the symptoms are acute, the temples should be leeches, cold applications instituted, and atropin instilled. As the inflammatory symptoms subside, a fifty per cent.

solution of boroglycerid in glycerin should be applied twice daily. It may be alternated with glycerol of tannin, or copper sulphate, or alum in pencil form. Long application of silver nitrate leaves distressing scars and discolors the conjunctiva, and is not advised. Those who derive good results from this salt use it with great care, and only after long experience. Boroglycerid is more efficacious and can be given to the patient to drop in the eye at home during the intervals of visits to the physician's office. There is diversity of opinion relative to the value of protargol in this affection. We have seen little good result from its use. Mercuric chlorid in solution of 1 : 250 may be brushed over the everted lids. Operations destroying much conjunctiva defeat their own purpose, as the previous destruction of this membrane by the disease is already the cause of many disagreeable complications. In cases in which the granulations are very profuse and have not yet ulcerated, the disastrous sequels may



FIG. 69.—KNAPP'S ROLLER-FORCEPS.

be averted by expression. A favorite method consists of squeezing the granulations with roller-forceps (Fig. 69), but we do not advise it as a routine practice. Tension may be relieved by splitting the external canthus and cutting the canthal ligament. Hyperemic and soft granules must be more carefully handled. Massage with iodoform ointment may be used, and is less painful to the patient, and often gives good results in a very short time. Pannus should be treated by massage, peritomy, or jequirity-inoculation (see under Diseases of the Cornea). Distortion of the lids must be corrected and corneal opacities treated. Constant instillations of glycerin or some bland oil are said to be palliative in xerosis.

TUBERCULAR CONJUNCTIVITIS resembles trachoma, but is, as a rule, confined to one eye. The ulcers are decidedly greater than in trachoma. The diagnosis may be definitely established by bacteriologic examination and by the symptoms of tuberculosis elsewhere. *The prognosis is unfavorable.* The local treatment is to effect

destruction of tissue involved. The general treatment is that of systemic tuberculosis.

VERNAL CONJUNCTIVITIS, OR SPRING CATARRH, is a conjunctival inflammation recurring each spring or summer and disappearing with the frost, characterized by a pericorneal epithelial hypertrophy. The affection is binocular, and occurs chiefly in the young. It is characterized by a swollen and injected limbus and the signs of general catarrhal inflammation. The conjunctiva is pale, and looks as if it were covered with a thin film of milk. The cornea itself is not involved. There may be localized hypertrophies on the conjunctiva of the upper lid. The disease disappears spontaneously, only to return in the majority of cases the next season. The average duration is about four years. In a few cases slight opacities are left on the cornea.

Treatment.—The refraction should be carefully examined, and any ametropia corrected. In some cases it is even advisable to put the ciliary muscles at rest for several weeks, by the daily instillation of atropin. A mild, soothing lotion should be prescribed, and protective glasses ordered.

PHLYCTENULAR CONJUNCTIVITIS.

Synonyms.—Lymphatic, scrofulous, or herpetic conjunctivitis.

Symptoms.—This disease is characterized by the eruption of temporary vesicles or pustules on the bulbar conjunctiva (Fig. 70). These blebs are called phlyctenules, and are grayish-red and flattened prominences, from one to four mm. in diameter, with deep-red surroundings. Sometimes only a single bleb is seen. When a number of these phlyctenules are present, there will arise signs of irritation, congestion, pain, photophobia, and even blepharospasm. The lid is swollen and red, the conjunctiva injected and velvety, and there is *mucopurulent discharge*. The vessels supplying the infected region

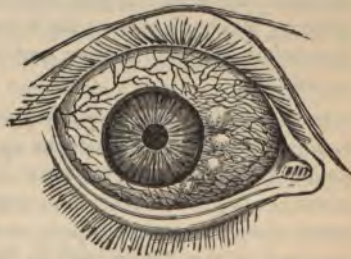

FIG. 70.—PHLYCTENULAR CONJUNCTIVITIS.

are swollen and become tortuous as they approach the phlyctenule. In the purulent form the disease soon reaches its height, remains severe for a few days, and then subsides. The milder varieties cause the patient slight inconvenience. Scrofulous children are particularly susceptible, and the disease is often seen in children with signs of eczema elsewhere on the body. It may follow the common infectious fevers. In debilitated children there is a tendency to relapse, and the disease may continue for years.

Unless the cornea becomes involved, the prognosis is good. Bacterial infection has been suggested as a cause.

Treatment.—The constitutional treatment consists of cleanliness, fresh air, good food, tonics, cod-liver oil, etc. Local treatment consists of the daily application of a mild Pagenstecher ointment, and irrigation with a mild antiseptic solution. Calomel may be dusted over the affected area, unless the child is taking some preparation of iodine. The applications should not be made in too rapid succession. Massage with a ten per cent. iodoform ointment, or with a weak salve of the yellow oxid, is often of value. A 1 : 1000 aqueous solution of pyoktanin has proved useful. Boroglycerid, fifty per cent., is a useful application. The more severe applications, such as silver nitrate and the zinc salts, were formerly used. Stimulating applications should be avoided if there are signs of a corneal ulcer.

PINGUECULA is a small, yellowish growth on the bulbar conjunctiva, close to the cornea and usually to the inner side. It has no vascular supply, and is pale when the rest of the conjunctiva is congested. Mechanical irritation is the probable cause. There is little discomfort, although it may lead to pterygium. No interference is necessary.

PTERYGIUM is a triangular patch of thickened conjunctiva, most common on the nasal side; the apex of the growth points toward the pupil, and the fan-shaped base radiates toward the canthus. As it continues to grow, it resembles a mass of flesh; and as years go on it partly atrophies, becomes pale, and appears tendinous. It is loosely attached at the limbus, and in this position a probe can be passed under its edges. On the cornea the growth is firmly adherent and must be torn or dissected away. If the pterygium grows over the cornea, it may drag the conjunctiva and caruncle with it to such a degree as to interfere with the movements of the eyeball, besides becoming

unsightly. This affection is frequently found in elderly persons who have endured exposure in years of outdoor occupation. It is common in sailors. One eye is usually affected, although the growth has been seen simultaneously in both eyes, and in rare instances has developed from the outer canthus.

Treatment.—If the growth has not extended upon the cornea and shows no sign of progression, it may be left undisturbed. A flat, stringy head indicates a cessation of growth, and excision need not be resorted to. A vascular head means active progression. The operation of removal is as follows: Grasp the neck of the pterygium with fixation forceps, making traction perpendicular to the surface; dissect up the head, and make two converging incisions into the body with a pair of scissors. The parts between these incisions are dissected away and the lozenge-shaped wound closed by a suture applied about the middle of the wound. Another method of removal is by *transplantation*. The growth is split longitudinally and is fixed in an upper and a lower conjunctival pocket with a suture. *Ligation* has also been recommended; a large part of the pterygium between the sclerocorneal margin and the base of the growth is strangulated by sutures in the manner shown in figure 71. It has been suggested that the whole trouble in pterygium lies in the apex, and curetment of the affected cornea or the application of the galvanocautery has produced good results. Under the old operations pterygium was liable to recur, and sometimes repeated operations caused limitation of the ocular movements. Electrolysis is the most recent treatment proposed.

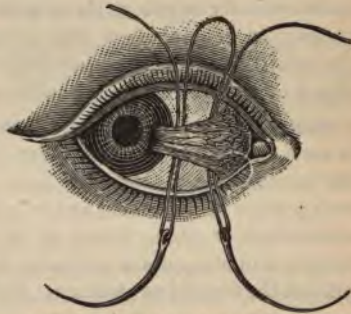

FIG. 71.—LIGATION OF PTERYGIUM.

INJURIES OF THE CONJUNCTIVA.

FOREIGN BODIES in the conjunctival sac are sometimes difficult to locate, and the lids should be everted and the bottom of the sulci explored. In case a foreign body resists removal, it must be remembered that it will cause disagreeable symptoms, and will eventually

have to be taken out; therefore, in refractory cases, it must be seized with a forceps and dragged out, even at the risk of laceration. Cocain may be used in the removal of a foreign body, and a mild antiseptic wash prescribed.

WOUNDS of the conjunctiva, if slight, need only an antiseptic wash, such as boric acid or a 1 : 5000 mercuric chlorid solution. Extensive wounds must be closed with a fine suture. Large granulations after wounds or operation may be cut off at the base with a pair of fine scissors.

SUBCONJUNCTIVAL HEMORRHAGES occur after traumatism, violent exertion, or severe fits of sneezing or coughing. They disappear spontaneously in two or three weeks. Subconjunctival hemorrhage, coming on several days after an injury, is indicative of fracture of the orbit. *Spontaneous hemorrhage* in the conjunctiva is a dangerous signal of an atheromatous condition elsewhere.

BURNS of the conjunctiva are usually on the bulbar portion, which is most exposed. The treatment consists in cleansing the eye, unless the burn has been caused by lime, when the parts should be washed with a piece of cotton soaked in oil. Acids and alkalies should be neutralized at once. Olive oil or liquid vaselin should be instilled. Cocain and atropin are advisable to relieve the pain, and may be applied in the form of an ointment: Atropin, 0.1; cocain, 0.2; vaselin, 10.0.

SYMBLEPHARON is an adhesion of the lid to the eyeball, thus restricting the movements of the eye (Fig. 72). It is cicatricial in

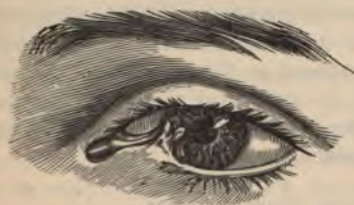

FIG. 72.—SYMBLEPHARON.

origin, following some injury, burn, or destructive inflammation of the conjunctiva. It should be prevented by keeping the injured or exposed areas from being in apposition during the healing process. Symblepharon is treated by dissecting up the constricting tissue and preventing the cut ends from uniting by transferring loos-

ened conjunctiva over one surface. In extensive cases the transplantation of new skin or mucous membrane is necessary to correct the deformity.

NEW GROWTHS.

TUMORS of the conjunctiva are lipoma, polypus, cysts, dermoids, sarcoma, and carcinoma. **Lipoma** should be turned out; **polypus**, excised down to the healthy tissue; and **cysts**, opened and their walls cauterized. If solely confined to the conjunctiva, **sarcoma** and **carcinoma** may be carefully excised, and the wound cauterized by the galvanocautery. In cases of deeper involvement, enucleation of the eye becomes imperative.

DISEASES OF THE CORNEA.

Anatomy.—The cornea is the transparent tunic covering the anterior fifth of the globe of the eye. It is circular in form, concavoconvex, and, by the way it is fitted into the beveled edge of the sclera, resembles a watch-crystal. When examined from its exterior surface, its vertical diameter is about one-sixteenth shorter than the transverse; on its interior surface its outline is perfectly circular. The cornea is one mm. thick at its apex. It is covered with the conjunctiva and is itself composed of three layers (Fig. 73). The anterior layer consists of epithelium, columnar in shape, supported by a homogeneous elastic structure called *Bowman's membrane*. The middle layer constitutes about 95 per cent. of the whole cornea, and consists of fine connective tissue and elastic fibrils, which are arranged in layers; between these layers is a series of communicating spaces, called *lacunas*. The lacunas, with their canals, constitute the lymph-system of the cornea, and through them the nutrient fluid circulates. In order that the cornea may be perfectly transparent, in health it is devoid of blood-vessels. The posterior layer consists of a glass-like, structureless basement tissue, called *Descemet's membrane*, which, in spite of its extreme thinness (.006 mm.), is very strong. On the surface of Descemet's membrane there is a single layer of flat endothelial cells, continuous with the anterior surface of the iris. The cornea is richly supplied with nonmedullated nerves, which extend to the uppermost layer of the corneal epithelium, and are sensitive indicators of irritation of the exposed surface.

INFLAMMATIONS OF THE CORNEA demand particular attention, as they are very likely to result in opacities, leaving irremediable

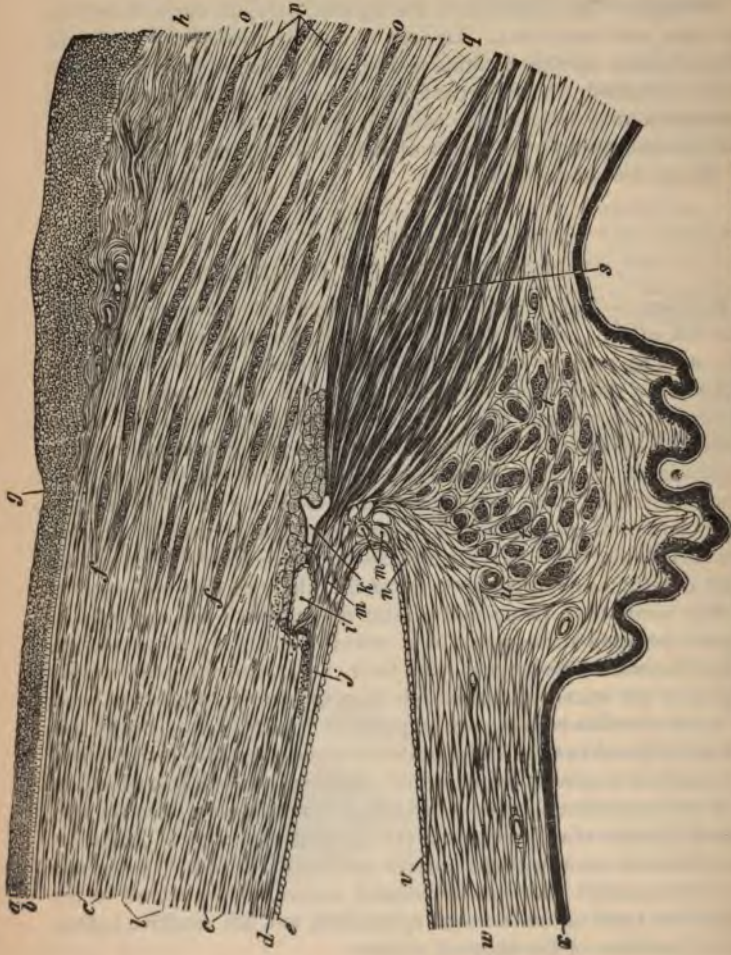


FIG. 73.—ANTERIOPOSTERIOR SECTION OF THE CORNEA WITH THE SCLEROTIC.
a. Anterior corneal epithelium. *b.* Bowman's lamina. *c.* Stroma. *d.* Descemet's membrane. *e.* Its epithelium.
f. Junction of cornea with sclerotic. *g.* Canal of Schlemm. *h.* Corneal lamellæ.
i. Canal of Schlemm. *j.* Limbus conjunctivæ. *k.* Iris. *l.* Iris. *m.* Iris. *n.* Iris.
o. Ciliary muscle. *p.* Ciliary muscle. *q.* Ciliary muscle. *r.* Uveal pigment.
s. Mesures in the tissue of the ligamentum pectinatum iridis. *t.* Mesures in the tissue of the ligamentum pectinatum iridis. *u.* Mesures in the tissue of the ligamentum pectinatum iridis. *v.* Mesures in the tissue of the ligamentum pectinatum iridis. *w.* Mesures in the tissue of the ligamentum pectinatum iridis. *x.* Mesures in the tissue of the ligamentum pectinatum iridis. *y.* Mesures in the tissue of the ligamentum pectinatum iridis. *z.* Mesures in the tissue of the ligamentum pectinatum iridis.

optic disturbances. Since the cornea is inelastic and nonvascular, the ordinary signs of inflammation are not present, and the diagnostic sign is cloudiness of the tissue, resulting from a collection of leukocytes that have passed into the cornea from the adjacent blood-vessels. In corneal inflammation there is generally swelling and inflammation of the lids and congestion of the conjunctiva. *Pericorneal injection* is due to congestion of the deep conjunctival vessels, arising from the ciliary arteries. Inflammations of the cornea may be divided into two classes, *superficial* and *deep*.

PANNUS.

Description.—Pannus is a vascular growth of connective tissue on the superficial layer of the cornea ; it may, however, extend and affect the deeper layers. It begins with an inflammation of the cornea, in which large areas become clouded and infiltrated with superficial blood-vessels. The newly formed and tortuous vessels are largest at the periphery, and are directed toward the center of the cornea. There may be only one vessel, or the vascular formation may be so luxuriant that a great part of the corneal surface is transformed into a fleshy-looking mass, having the appearance of raw beef. This condition is sometimes called *pannus crassus* or *pannus carnosus*.

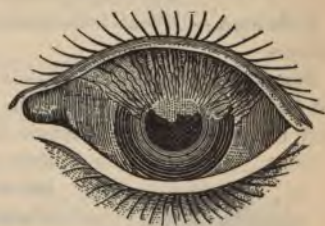

FIG. 74.—PANNUS IN TRACHOMA.—(After Sichel.)

The cause of pannus is generally the friction of roughened granular lids against the cornea, or there may be an extension of the trachomatous process into the cornea. The upper half is the part usually affected (Fig. 74). Prolonged irritation of the cornea by inverted lashes or entropion may cause pannus unassociated with ulcers. The eczematous variety of pannus is a sequence of a phlyctenular process.

The symptoms of pannus are pain, photophobia, lachrimation, swelling, conjunctival and ciliary injection, together with the characteristic vascular appearance.

The prognosis depends upon the extent of corneal infiltration and destruction of the epithelium. The important sequels are corneal opacities, and, rarely, conic cornea and corneal staphyloma.

The treatment should be directed to the cure of the granular lids, or to remedying the trichiasis or entropion. Should the pannus outlast the causes of the disease, massage with yellow ointment or the application of such preparations as boroglycerid and copper sulphate should be tried. Eserin, and iodoform or one of its substitutes, and constant bandaging of the eye are of value. The extreme measures are peritomy, which consists in removal of a ribbon of conjunctiva about two mm. wide, parallel with the edge of the cornea, thus severing and obliterating the superfluous vessels (unfortunately, the vessels repullulate); or the induction of an acute inflammation of the conjunctiva with an extract of jequirity seeds. For the relief of pain, atropin and hot-water applications are useful.

INTERSTITIAL OR PARENCHYMATOUS KERATITIS.

Definition.—Diffuse inflammation of the substantia propria of the cornea.

Symptoms and Diagnosis.—In this disease the deeper tissues of the cornea become infiltrated by lymph-cells, which slowly increase until the whole cornea becomes more or less opaque.



FIG. 75.—INTERSTITIAL KERATITIS.

Without a lens the cornea presents the appearance of a piece of ground glass (Fig. 75), but focal illumination shows that the parts are not uniformly affected, and sometimes unaffected portions may be seen between local opacities. Pericorneal injection is marked, but the conjunctival vessels may be but slightly affected. The epithelium may be partly destroyed. The iris may be affected sympathetically and posterior

synechias formed; in fact, the whole ciliary region and the choroid may be affected and the nutrition of the vitreous disturbed. In very severe cases blood-vessels form in the interstices of the cornea. This disease is the result of general infection, and, according to Horner, in at least 80 per cent. of cases both eyes are attacked eventually. The disease occurs chiefly in hereditary syphilis, and is associated with the other signs of this malady, such as Hutchinson's teeth, thickening of the periosteum, glandular swellings, middle-ear disease, etc. A syphilitic history may be obtained from the parents. The mother

may bear evidences of specific infection, and give a history of sickly children or recurring miscarriages. It is probable that some cases are of tuberculous origin. The chief subjective symptoms are dimness of vision and lachrimation, but there may be much pain or photophobia.

The prognosis is unfavorable, although complete loss of vision is seldom to be feared. The disease is of long duration, and restoration of the visual acuity is doubtful, especially if the patient is not very young.

The treatment is directed to the systemic condition, and consists in mercurials, iodids, cod-liver oil, and tonics, cleanliness, good food, and fresh air. The following is a good formula :

R.	Mercuric iodid,	gr. ij
	Potassium iodid,	ʒ ij
	Syrup of sarsaparilla,	q. s. ad ʒ iij.

A teaspoonful in water after meals.

The local treatment is by atropin, warm compresses, and protective glasses. When the disease has passed its climax, massage with yellow ointment or dusting with calomel are of advantage.

PUNCTATE KERATITIS is a disease of the cornea associated with affections of the iris, choroid, and vitreous. It is characterized by the formation of opaque dots, generally arranged in a triangular manner upon the posterior elastic lamina of the cornea, and hence is sometimes called *descemetitis*, which term, however, is usually restricted to serous iritis. It is also used to express an inflammatory affection of the cornea occurring in young syphilitic children, in which isolated white spots, surrounded by cloudy areas, appear on Descemet's membrane. There is a *superficial punctate keratitis* associated with severe conjunctivitis and catarrh of the respiratory tract.

PHLYCTENULAR KERATITIS.

Description.—Although there is no especial reason for separating this disease from phlyctenular conjunctivitis, it is usually also described under Diseases of the Cornea. It is particularly a disease of children of scrofulous diathesis or improper nourishment, or who show signs of eczematous affection in other portions of the body. Adults and healthy children are also affected. It is characterized

more phlyctenules, or small cysts, formed on the limbus of the conjunctiva, and extending upon the cornea (Fig. 76). These phlyctenules cause an opacity which may clear up or may be followed by the formation of a bundle of new vessels on the cornea. This leash of vessels may disappear, but the ulcer beneath them generally leaves an opacity.

Symptoms.—The chief symptoms are acute pain, photophobia, lacrimation, and the characteristic bundle of vessels, with a yellow crescent at the apex, its concavity toward the vessels. Every phlyctenule does not necessarily change to an ulcer, but may be dissolved under proper treatment. The photophobia may be so intense as to cause blepharospasm, because irritation of so highly nervous a tissue as the cornea gives rise to severe reflex symptoms. The blepharospasm may be so severe as to necessitate the administration of a general anesthetic before the cornea can be properly examined.



FIG. 76.—PHLYCTENULAR ULCER.

The treatment consists of good food, improved hygienic surroundings, and soothing local applications. Of the latter, atropin and warm compresses are advised. The eye may be douched with mercuric chlorid, 1 : 8000. If an ulcer exist, the general treatment as before described should be instituted. When the ulcer has healed, it should be dusted with iodoform or calomel, and massaged with yellow ointment.

We have found that to promote absorption of the vessels the instillation of eserin into the eye, followed by dusting fine iodoform over the cornea, and a constant application of a bandage, securing local heat, produce good results.

HERPES OF THE CORNEA is characterized by the formation of small blebs filled with a watery fluid. It may be the general accompaniment of herpes zoster or febrile herpes. The blebs should be treated with the gentlest measures, such as the instillation of atropin, disinfection, and a bandage. Should they form ulcers, they should be treated as such.

NEUROPARALYTIC KERATITIS is an ulcerative condition of the cornea, due to some disturbance of the corneal nerve-supply. The

prognosis and treatment of the disease depend upon the nervous lesion causing it.

BULLOUS KERATITIS is characterized by the formation on the cornea of large vesicles filled with a clear fluid. The vesicles break after a few days, and the symptoms of irritation subside. This condition has been seen associated with glaucoma, iritis, and inflammation of the uveal tract. The disease has been attributed to some affection of the corneal nerves, and to malarial fever. A peculiar chronic form is sometimes seen after corneal injury. It is called **recurrent traumatic keratitis**. It is said that the recurrent attacks are preceded by a peculiar aura, and that they may be aborted by large doses of quinin. The vesicles should be incised early, and local treatment instituted.

KERATITIS FROM LAGOPHTHALMOS is a condition in which there is ulceration of the cornea, due to exposure from incomplete closure of the lids. The chief causes are lack of sensation in the cornea from paralysis of the peripheral nerves, a condition in which the patient lies comatose for a long time, and possibly some paralysis of the lid-muscles. Protection by anointing with vaselin or a bland oil is indicated.

SUPPURATIVE KERATITIS.

Corneal ulcer is caused by an external wound leaving an opening for the entrance of a suppurative process, by intense conjunctival inflammation, or by some deep inflammatory process which leads to a destruction of the superficial layers and epithelium.

Diagnosis and Symptoms.—It is very important to immediately recognize any superficial loss of substance in the cornea. The ordinary optic aids, such as oblique focal illumination and high plus lenses, or the ophthalmoscope, are generally sufficient. In doubtful cases and in young children, a drop of fluorescein placed on the conjunctival sac, and immediately washed out, is a ready means of diagnosis. Any spot of the cornea denuded of its epithelium will be colored green. If an ulcer is present, we must determine whether it is due to external infection, from extension of some conjunctival disease, from nervous disease, or from some systemic affection, as the subsequent treatment depends much on the origin. However, if pain, photophobia, lacrimation, and attendant swelling of the lids and conjunc-

tiva, together with extensive and progressive destruction of tissue, are present, it is necessary to proceed immediately, regardless of the mode of origin, which may be left to a subsequent examination. An ulcer with a ragged edge and a grayish, uneven base, with general cloudiness around the circumference, and acute associate local disturbance and subjective symptoms, is probably in an active stage of inflammation. If the cloudiness is clearing up, the edge round, and the ulcer appears clear and smooth, and the patient's symptoms are subsiding, the healing process has probably begun. As the ulcer becomes filled up, the opacity becomes more dense; the younger the patient, the sooner the scar will clear up. Central ulcers result in most damage to vision.

The sequels of most importance are: *corneal opacity*; *staphyloma*, or hernia of the cornea, due to weakening of its structure by scar-formation, which condition sometimes includes a staphyloma of the iris as well as the cornea; *perforation*, followed by discharge of aqueous and prolapse of the iris, which may remain permanently adherent to the white corneal scar, a condition called *leukoma adherens*; atrophy of the eyeball, called *phthisis bulbi*, following extensive destruction of the cornea; and prolapse even of the lens and vitreous.

The prognosis varies with the age of the patient, location and extent of involvement, and the general systemic condition.

The treatment is, first, to put the eye at rest, which is best accomplished by a pressure-bandage and by atropin, which subdues pain and overcomes inflammation. If there is much congestion of the conjunctiva, leeches to the temple will give great relief and hasten subsidence of symptoms. Disinfection is best accomplished by a mercuric chlorid solution, 1 : 5000, or the ulcer may be dusted with iodoform. After dusting iodoform on the cornea, the upper lid should be drawn away from and down over the cornea, and held in position a few minutes, otherwise movement of the eye will brush all the powder off the cornea. If the ulcer progresses, stronger disinfection, preferably with mercuric chlorid, 1 : 1000, boroglycerid 50 per cent., or formalin 10 per cent., will be needed. Finally, if the ulcer resists all treatment and is progressive, the whole of the infected surface should be cauterized by the direct heat of the galvanocautery. Moist heat, applied in the shape of mild antiseptic compresses, will lessen the pain, increase the development of blood-vessels, and arouse a general reaction in the affected parts.

If perforation seems probable, it is best to hasten it by puncture with a needle or small cataract knife, as experience has shown that perforated ulcers heal quickly of themselves, and better drainage is established. After perforation the eye should be carefully washed, eserine instilled, a pressure-bandage applied, and the eye allowed to remain untouched for at least twenty-four hours. If the iris prolapses, it must be drawn from the wound and excised. When the ulcer shows signs of healing, daily massage with a weak Pagenstecher ointment is advisable. The membrane of Descemet is very elastic and sometimes, instead of perforating, it prolapses through the ulcer and prevents its healing, causing a **corneal fistula**. In such cases the edges of the ulcer should be stimulated or cauterized. The treatment of the sequels will be discussed separately. Constitutional treatment, particularly administration of tonics, should be inaugurated at the beginning of the disease, and any causal disease corrected. The patient should not be kept in an ill-ventilated, dark room.

ABSCESS OF THE CORNEA may run its course without ulceration, or it may result in the formation of an ulcer—usually the *ulcus serpens*. Abscesses in the superficial layers of the cornea are most prone to ulceration.

The chief causes of abscess are infection through an abrasion or distinct wound, or infection through the blood or lymph channels, as seen in some acute exanthematous diseases, such as measles, scarlet fever, small-pox, etc.

The appearance presented is that of a yellowish, circumscribed opacity near the middle of the cornea, and surrounded by a grayish zone. It is usually round or crescentic in shape. The surface over the abscess appears elevated and dull, and the whole cornea may lose its luster and appear as opalescent. There is usually much conjunctival and ciliary injection. The abscess is attended with severe pain, photophobia, blepharospasm, etc. Hypopyon, onyx, and iridic involvement are usually constant attendants. The common termination is ulceration through the superficial corneal layers; but occasionally the abscess spreads through the corneal stroma, and gradually becomes absorbed without undergoing ulceration.

The treatment consists of atropin, warm fomentations, iodoform, and a light bandage. If these measures do not check the process, resort must be had to the cautery. Hypopyon is relieved by para-

centesis, repeated if necessary. Tincture of cinchona comp. in full doses is recommended. Stimulating diet should be instituted.

SERPIGINOUS ULCER, OR ULCUS SERPENS, is a destructive inflammation of the cornea usually attacking debilitated and aged persons. Disease of the lacrimal passages predisposes to it. Its chief characteristic is its remarkable inclination to extend and destroy tissue. It most commonly results from some injury to the eye, often only a small scratch, through which some form of infecting germ is introduced. Infection may be derived from the article causing the injury,

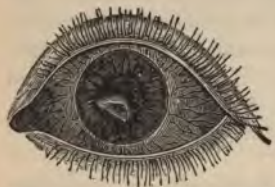

FIG. 77.—ACUTE SERPIGINOUS ULCER OF THE CORNEA.

from some purulent discharge about the eye or its appendages, or from some article used to wipe the eye. At the posterior part of the ulcer there is generally seen a grayish cloud, which may extend into the anterior chamber. This is caused by a collection of pus-cells, either in the lamellas of the cornea, called **onyx**, or in the anterior chamber, which render the aqueous opaque, and, settling in the bottom of the anterior chamber,

form what is called **hypopyon**. The disease begins as a round, yellowish abscess near the center of the cornea (Fig. 77), which breaks and forms an ulcer rapidly increasing in surface and depth. Serpiginous ulcer often follows severe infectious diseases, particularly small-pox.

The prognosis is unfavorable, as there is generally left an extensive opacity, and most likely anterior and posterior synechias.

The treatment is the same as for an ordinary severe ulcer or abscess. Occasionally Saemisch's operation at the base of the ulcer is required.

Rodent ulcer is a chronic inflammation, beginning on one margin of the cornea and slowly eating its way to the opposite margin, but rarely extending into the deeper layers. Its edges must be cauterized.

ANOMALOUS OPACITIES.—In this connection it is deemed advisable to mention peculiar acute opacities, evidently denutritional, which can not be called ulcers or abscesses. They develop rapidly as white spots without previous signs of corneal inflammation, and *sometimes* leave permanent opacities. This phenomenon has been *noticed after attacks of severe conjunctivitis and following chronic*

iritis. Such denutritional opacities are no more amenable to treatment than the ordinary forms following corneal ulceration. The free use of mercuric chlorid in cataract-extraction sometimes leaves corneal opacities, which may be permanent.

VARIETIES OF CORNEAL OPACITIES.—*Leukoma* is the densest corneal opacity, and appears as a white spot. *Macula* is less dense, and appears as a bluish-gray spot, and is only visible against a dark background. *Nebula* is a transparent and extremely delicate opacity, which may only be detected by optic aid, and is often overlooked in first examinations. The degree of visual disturbance is dependent on the position and nature of the opacity. A considerable opacity at the margin of the cornea may cause little or no trouble, while a nebula in the center of the cornea markedly reduces the visual acuity.

TREATMENT OF CORNEAL OPACITIES.—The results of the treatment of corneal opacity vary with the extent of the involvement and the age of the patient. Fortunately, there is a strong tendency toward clearing up in young patients. Absorption is favored by mild irritants and absorbents, such as finely-powdered calomel or iodoform dusted upon the cornea, and massage with yellow ointment or iodoform ointment, continued months and even years. By retain-



FIG. 78.—TATTOOING NEEDLE.

ing heat, a light bandage promotes absorption. The greatest degree of patience must be exercised to produce a beneficial result.

If the condition of the retina is believed to be favorable, and part of the cornea is clear, an optic iridectomy, forming an artificial pupil back of the transparent portion, will improve vision. As yet, the insertion of transparent corneal grafts has not been successful. Recently some progress in the clearing of corneal opacities has been made by a special use of the galvanic current. Tattooing the opacity with India ink is sometimes resorted to for cosmetic as well as optic reasons. The ink is gently inserted by several fine steel needles firmly fastened in a handle (Fig. 78).

ARCUS SENILIS is a grayish-white opacity, extending around the edge of the cornea about 1.5 mm. from the border. The outermost

rim of the cornea remains transparent. It is chiefly seen in aged and atheromatous persons. On account of its peripheral location, it causes no visual disturbance.

STAPHYLOMA OF THE CORNEA is a bulging forward of a corneal scar with an adherent iris. It is caused by the weakening of the corneal tissue, which gives way to the intraocular pressure, pushing the iris and even the lens forward. Secondary glaucoma is not an uncommon complication. The staphyloma may be partial or total (Fig. 79). The pain, loss of vision, and repulsive disfigurement associated with this affection render the patient a great sufferer.



FIG. 79.—COMPLETE STAPHYLOMA.

Treatment.—Unless the condition is only that of a simple prolapse of the iris, the treatment is of no avail. When possible, abscission of the staphylomatous projection, forming a

suitable stump for a glass eye, is to be preferred to enucleation, particularly in young children, in whom the presence of orbital contents is necessary for the symmetric growth of the face. If there are signs of infection or internal disease, enucleation is peremptorily demanded.

CONIC CORNEA, OR KERATOCONUS (Fig. 80), is a thinning and protrusion of the cornea in the form of a blunt cone, without alteration in the transparency. It is the result of progressive weakening of the corneal tissues. It occurs in young persons between ten and twenty years of age, without any evidence of inflammation. It eventually becomes stationary, and perforation never occurs. The pathology is obscure. It is readily diagnosed by the distorted image on the patient's cornea, the depth of the anterior chamber, and by the retinoscope and ophthalmoscope; in fact, it is only necessary to take a side view of the patient's eye.

Treatment is of little value, although a high minus spheric or a combination of minus spheric and minus cylindrical lenses may improve the vision. Hyperbolic glasses have been devised, but are little used. Trephining a fine piece of the apex of the cornea, touching it with a special galvanocautery point, and incision or exci-

sion with a knife have all been suggested, but have proved of little value.

TUMORS OF THE CORNEA are very rare, but the cornea may be attacked by new growths which arise at the conjunctival limbus.

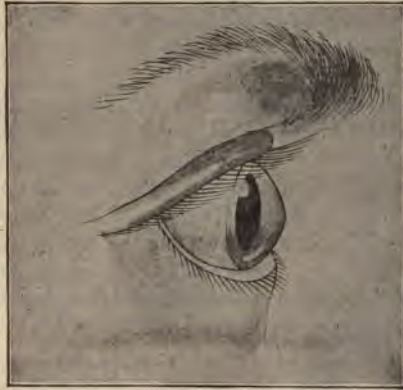

FIG. 80.—CONIC CORNEA.

The treatment of benign growths, such as dermoid cysts, is excision. Malignant processes demand enucleation of the eye.

INJURIES TO THE CORNEA.

FOREIGN BODIES IN THE CORNEA, if not removed, almost invariably cause cell-infiltration and destruction of the adjacent tissue, thus inviting infection. However, the subjective symptoms so well known to everybody are usually so severe as to demand immediate treatment. Although simple inspection may be sufficient, focal illumination and fluorescin, for the detection of the denuded area of epithelium, are sometimes necessary for locating abrasions. In every case it is safer to examine the eye by focal and oblique illumination.

Foreign bodies in or on the cornea can generally be removed without the use of cocaine, and without instrumental aid. A wisp of cotton is wound on itself or on a small stick; the patient is told to look down-

ward, and the cotton is pressed firmly against the cornea. The patient immediately rotates the eyeball upward, and the cornea is brushed against the fibers of cotton, which usually entangle the foreign body. We have found this simple method almost invariably successful, and we urge its trial before resorting to the spud or needle.

The removal of a foreign body from the cornea by instrument is a procedure that should be carried on with especial caution. If the substance is embedded, the cornea should first be cocainized and rendered aseptic.

Under focal illumination, a small curet, chisel, or spud will generally accomplish the removal. If, however, the foreign body is close to the anterior chamber, it may be lost in the iridic angle. In such a case a small keratome should be introduced into the anterior chamber and pressed against the posterior surface of the cornea, thus preventing penetration of the foreign body into the anterior chamber. The electric magnet is often of great value in removing pieces of iron and steel. A boric acid wash or iodoform ointment should be used for at least twenty-four hours after the use of an instrument in the cornea.

BURNS OF THE CORNEA are treated on the same principle as burns of the conjunctiva, already described. Ulceration, opacities, and symblepharon are the important sequels to be feared.

WOUNDS OF THE CORNEA are always dangerous, not only from the destruction of corneal tissue and subsequent opaque cicatrix, but they are also often attended by sudden escape of the aqueous and prolapse of the iris. Results of infection through a corneal wound vary from the formation of an ulcer to the destruction of the whole eyeball.

The **treatment** is the application of a simple aseptic bandage. The eye should be kept clean, and if there is much irritation, atropin should be used. Should the iris become prolapsed, an effort must be made to replace it and retain it in position by eserin, complete rest, and a bandage. If this treatment is not successful, the iris should be drawn out and excised. Very large prolapses should not be excised, as they will recur, and much iris tissue will be needlessly lost. In such cases no operative interference is indicated until the wound closes. The cornea and iris are cleansed, an attempt made to partially reduce the prolapse, atropin instilled, a pressure bandage applied, and the patient placed on his back.

OPERATIONS ON THE CORNEA.

PARACENTESIS OF THE CORNEA is an operation performed for the purpose of emptying the anterior chamber of aqueous, and thus relieving any increased intraocular tension, or for evacuating hypopyon. It is best done with a paracentesis needle, a bent keratome, or a slender Graefe knife. The eye is thoroughly cleansed, and the point of an aseptic knife is *perpendicularly* introduced at the lower outer border of the cornea. If it is introduced at an angle, there is danger of splitting the layers of the cornea, and not directly perforating it. After perforation of the cornea, the blade of the knife is turned horizontally, and a corneal wound of about two mm. in length made. The knife is then slowly withdrawn, allowing the aqueous to escape slowly. Depression of the lower edge of the wound by a curet will aid in the evacuation of hypopyon.

SAEMISCH'S OPERATION is performed for the relief of corneal abscess or serpiginous ulcer. It consists in introducing a Graefe knife through healthy corneal tissue at the margin of the involved area, carrying it into the anterior chamber, and making a counterpuncture in healthy tissue at the other side of the abscess. The cutting-edge is then drawn forward, and the abscess bisected. Any pus may be removed by irrigation or by a scoop. The wound must not be allowed to close completely so long as the disease is active.

TRANSPLANTATION of cornea consists in removing, with a fine trephine, a piece of a rabbit's cornea, and transplanting it over the denuded area. It is of doubtful value in any case.

ABSCISSION OF STAPHYLOMA OF CORNEA AND SCLERA.—**CRITCHETT'S OPERATION** is the simplest and most effective. Five threaded needles are inserted, equidistant and parallel with $\infty\infty$.

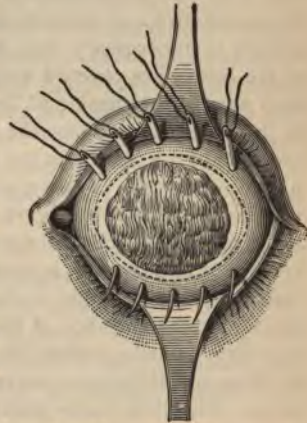


FIG. 81.—NEEDLES IN POSITION BEFORE EXCISION OF STAPHYLOMA.

another, through the base of the staphyloma (Fig. 81); the involved tissues are then excised with a knife or scissors, and the needles drawn through and the sutures tied. This leaves a very desirable stump upon which to place an artificial eye. This operation is to be preferred to enucleation of the eye in children, as the stump favors symmetric growth of the face.

DISEASES OF THE SCLERA.

Anatomy.—The sclera forms the external tunic of the posterior four-fifths of the eyeball. It is a dense, fibrous membrane, thicker behind than in front. Since the surface of the sclera is partially protected by the conjunctiva and partially by the capsule of Tenon, an epithelial surface is unnecessary, and both the internal and external surfaces of the sclera are covered with endothelium, which facilitates movement against the capsule of Tenon on one side and the middle tunic on the other. Anteriorly, the sclera presents a beveled edge for the reception of the cornea, in the same way that a watch-glass is received in a grooved case. The anterior surface is covered by a thin, tendinous layer, the *tunica albuginea*, which is derived from an expansion of the tendons of the recti muscles, and which, by reason of its brilliant white appearance, is commonly called "the white of the eye." Posteriorly, the sclerotic is continuous with the sheath of the optic nerve. At the entrance of the optic nerve the sclerotic forms a thin, cribriform lamella, called the *lamina cribrosa*, which is pierced by the filaments of the optic nerve and the central artery and vein of the retina. The sclera is also pierced, about twelve mm. anteriorly, by the posterior ciliary vessels and nerves, and still more anteriorly by the venæ vorticosæ, which empty into the ophthalmic vein. Close to the limbus, the anterior ciliary vessels and nerves enter the sclera. The fibers of the sclera contain numerous lymph-channels communicating with those of the cornea and of the internal and external structures.

SCLERITIS OR EPISCLERITIS.

Inflammations of the sclera are usually secondary to those of the cornea, ciliary body, and choroid; in fact, all four of these structures may be involved in anterior sclerochoroiditis. Idiopathic disease of the sclera is not common, and is never diffuse.

Episcleritis is a localized inflammation of the scleral tissue characterized by a purplish injection of the ciliary, deep pericorneal, and conjunctival vessels.

Symptoms and Diagnosis.—If the conjunctival vessels are kept empty by gentle pressure, the bluish scleral vessels are seen more clearly. There is considerable pain on pressure and some local swelling. Carefully examined, a flat nodule made up of minute vesicles is seen lying about three mm. from the edge of the cornea. There are often adjacent slate-gray blotches, which are very diagnostic. The disease is intimately connected with rheumatic disorders, and with syphilis and tuberculosis. The diagnosis is easy, and depends upon the characteristic local condition and rheumatic, gouty, or syphilitic history. There may be confusion with phlyctenular disease. A phlyctenule is not covered with a network of vessels, may ulcerate, and is of short duration. The course of the disease is protracted, sometimes one nodule after another being formed until a large portion of the sclera is occupied by blotches. Relapses are frequent, and are closely connected with general rheumatic paroxysms. The pain is more or less severe, and for the time the eye is practically useless for near-work.

Treatment is general. Salicylates and the ordinary rheumatic treatment should be instituted; or if syphilis or tuberculosis are defined, their respective treatments should be inaugurated. Ordinarily, local treatment should be avoided, but in chronic cases massage with yellow ointment may be tried. For the relief of the pain, moist heat and pressure are advised. If the choroid is involved, atropin is indicated.

ANTERIOR AND POSTERIOR STAPHYLOMA.

STAPHYLOMA, or, more properly speaking, ectasia, of the sclera is the name given to change in the shape of the eyeball due to stretching of its outer coat. The weakest portions of the sclera are in the region of the optic nerve, and where it is perforated by the venæ vorticosæ.

ANTERIOR STAPHYLOMA is an outward bulging of the sclera in the ciliary region (Fig. 82). It is caused by prolonged, increased intraocular tension, and scleral disease. The protruding sclera is thin, and the black uveal pigment is seen through it. The protrusion may

be of small size, or may include the entire anterior half of the globe, involving the ciliary body, lens, iris, and cornea. If the pressure is due to some intraocular growth, such as sarcoma of the choroid, palpation with a fine sound will reveal a firm, unyielding body beneath the sclera, the underlying portion of the ciliary body being involved

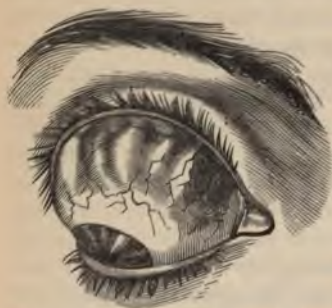

FIG. 82.—STAPHYLOMA OF SCLERA.

in the extension. If the bulging is of small extent, the condition causing the increase in tension which produces the ectasia should be treated. If the major portion of the ciliary region is involved, abscission or enucleation may be necessary.

POSTERIOR STAPHYLOMA is a nontraumatic scleral bulging at the posterior portion of the globe. It is closely associated with high degrees of myopia, and is the result of a posterior sclerochoroiditis,

and is further mentioned under diseases of the choroid and myopia.

HYDROPTHALMOS is a congenital condition in which the whole sclera yields to increased ocular pressure and there is more or less uniform enlargement of the eyeball. It is due either to intrauterine iridokeratitis, or congenital deficiency or closure of the drainage canals about the iridic angle. Early iridectomy and the long-continued use of eserine are advised.

WOUNDS OF THE SCLERA generally involve the iris, choroid, and vitreous, and therefore will be discussed under penetrating wounds of the eyeball. If the sclera alone is involved, healing is very prompt, and there are no disagreeable sequels.

The treatment consists of disinfection, closure of the wound, and a bandage. If there is considerable gaping, a conjunctival or scleral suture may be necessary.

DISEASES OF THE IRIS AND CILIARY BODY.

Anatomy.—The iris is a circular, contractile membrane of elastic and nonstriped muscular fibers, which forms a septum between the anterior and posterior chambers of the eye (Figs. 83 and 84). It is pierced somewhat toward the nasal side of its center by a circular opening called the *pupil*. It is suspended from the cornea by the *ligamentum pectinatum iridis*, and hangs in the aqueous humor, slightly in front of the lens and ciliary processes, and about 2.5 mm. behind the cornea. The anterior surface is lined by flat epithelium continuous with Descemet's membrane. The posterior surface of the iris is lined with a deep purple pigment, which is called *uvea*, from its resemblance to a ripe grape. The iris is composed of two layers, an anterior or muscular, consisting of radiating fibers, which converge from the circumference toward the center and dilate the pupil. Some authorities consider this layer fibroelastic rather than muscular. The circular layer surrounds the pupil like a sphincter, and contracts the pupil.

The *vascular supply* is from two sets of anastomosing vessels, one of which is located in the ciliary or peripheral portion, and the other surrounding the pupillary margin. The arteries are branches of the long and anterior ciliary arteries forming the *circuli iridis major* and *minor*. They are very numerous, and are provided with extraordinarily thick walls, so that they can maintain their lumen when stretched.

The iris is plentifully supplied with *nerves*, arising from branches of the oculomotor, trifacial, and sympathetic. The sphincter pupillæ is supplied by the oculomotor, and the dilator iridis is supplied by the sympathetic. The trifacial supplies common sensation.

The *spaces of Fontana* are small cavernous spaces in the intervals between the fibers of the ligamentum pectinatum iridis, which communicate with a somewhat larger space in the substance of the sclera close to the corneal junction, called the *canal of Schlemm*, or *sinus circularis iridis*. This latter canal has been described by some as a lymph-canal, by others as a venous sinus. The pigment of the iris is situated in the stroma of the membrane, and to it the color of the eyes is due. In light blue or gray eyes there is little pigment; in *albinos* it is absent.

The ciliary body comprises the ciliary processes and the ciliary muscle.

The ciliary muscle (Fig. 83) is a grayish, semitransparent band of unstriped muscular fibers, about $\frac{1}{8}$ of an inch broad, thickest in front.

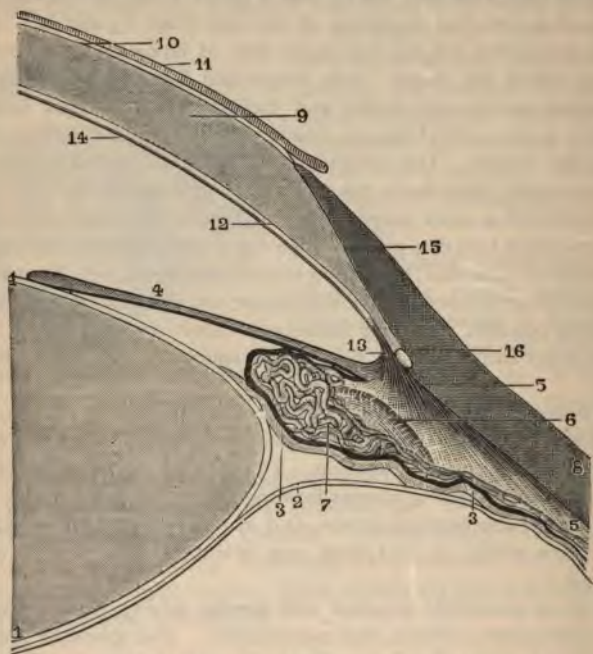


FIG. 83.—THE CILIARY MUSCLE AND ADJACENT STRUCTURES.

- 1, 1. Crystalline lens. 2. Hyaloid membrane. 3, 3. Zone of Zinn. 4. Iris. 5. 5. Radiating portion of ciliary muscle. 6. Section of circular portion. 7. Venous plexus of a ciliary process. 8. Sclerotic. 9. Middle layer of cornea. 10. Anterior hyaline layer of the cornea. 11. Epithelial covering of this layer. 12. Posterior hyaline layer of the cornea, or membrane of Descemet. 13. Fibers in which this layer terminates, or ligamentum pectinatum. 14. Epithelial covering of posterior hyaline layer. 15. Junction of sclerotic and cornea. 16. Section of canal of Schlemm.

It consists of radiating and circular fibers, the former the more numerous, arising from the junction of the cornea and sclera, to pass backward to the choroid, opposite the ciliary processes; the latter are internal, and pursue a circular course around the insertion of the iris.

The circular fibers are sometimes called the *ring-muscle of Müller*, and were formerly described as the ciliary ligament; they are remarkably developed in hyperopia and hyperopic astigmatism.

The ciliary processes (Fig. 84) are from 60 to 70 folds formed by reduplications of the choroid at its anterior margin. They are arranged in a circle, and form a sort of plaited frill behind the iris, around the margin of the lens. They consist of large and small processes, irregularly alternating, the former being about $\frac{1}{10}$ of an inch long.

The *zone of Zinn* is the name given to the pigmented indentations made by the ciliary processes in the hyaloid membrane. Its synonyms are the zonule or suspensory ligament of the lens.

INFLAMMATIONS OF THE IRIS.

HYPEREMIA OF THE IRIS is due to congestion of the iridic vessels preceding iritis or accompanying some inflammation of the adjacent tissues. It is recognized by the contraction and discoloration of the pupil, and the sluggish reaction to atropin. If the hyperemia becomes so intense as to produce an exudate, there is a genuine inflammation called iritis.

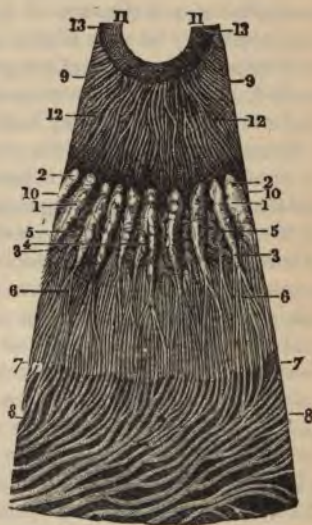

FIG. 84.—SECTION OF CILIARY BODY AND IRIS.

- 1, 1. Ciliary processes. 2, 2. Their base or rounded extremity. 3, 3. Their apex. 4. A process with bifurcated extremity. 5, 5. Reticulated folds, or ciliary process of the second order. 6, 6. Venules that emanate from these. 7, 7. Ora serrata of choroid. 8, 8. Veins of choroid. 9. Section of iris. 10, 10. Circumference of iris. 11, 11. Small ring of iris. 12, 12. Large ring of iris.

PLASTIC IRITIS.

Definition.—An inflammation of the iris in which a scant, fibrinous exudate is deposited on the anterior or posterior surface of the iris, the pigment-layer at the edge of the pupil thereby becoming adherent

in places to the capsule of the lens. This binding down of the iris to the lens is the cause of the immobile pupil.

Symptoms.—The patient complains of intense pain radiating over the forehead and face, and which is not proportionate to the severity of the disease. The pain is worse at night. There is lachrymation, photophobia, and dimness of vision. In some cases the subjective symptoms may be very slight. The objective symptoms are pericorneal injection, haziness of the pupil, loss of luster in the iris, and contracted, distorted, or unsymmetric pupil. Hyperemia of the optic nerve is said to accompany iritis.

Course and Sequels.—An uncomplicated iritis running its course in from two to four weeks is an exception. Permanent adhesions, or synechias, of the iris, by organized exudate between it and the surface of the capsule of the lens, are often left behind, and render relapses of iritis likely. The whole pupil may become blocked with organized exudate, and thus produce loss of vision in the eye affected. If there are many severe recurrences of attacks of iritis, circular adhesions may form between the lens and iris, and destroy communication between the anterior and posterior chambers. In such a case the iris bulges forward from the tension of the aqueous which collects in the posterior chamber, causing the condition known as "ballooned iris," or "umbrella iris." Unless an artificial pupil be formed at once by iridectomy, reestablishing the communication between the chambers, the whole eye will be destroyed.

Causes.—What is called *idiopathic iritis* is generally the result of some general systemic dyscrasia, although one eye only is often affected. Syphilis is the most common cause. Other causes are tuberculosis, rheumatism, gout, diabetes, nephritis, and the severe infectious fevers. Often the only explanation of the origin is exposure to cold, or "catching cold" in the eye. Secondary iritis follows inflammation of the adjacent tissues; even a conjunctivitis may lead to iritis. Traumatism, with or without infection, or a foreign body in the iris are causes of the inflammation.

Treatment.—The most important element in the treatment is to prevent or overcome adhesions of the iris. If possible, a history of an injury or clinical manifestations of some systemic condition known to cause iritis should be elicited. It is especially important to institute *immediately general treatment* in syphilis, rheumatism, and gout. The *iodids, salicylates, salol, and mercurials* are useful. The diet

should be chiefly of milk and broth during the acute stage. The pupil should be immediately dilated by atropin, and if it yields to the drug and is perfectly circular, a rapid improvement may be expected. Caution must be used in the administration of atropin to persons past forty-five, or in cases showing increased tension of the eyeball, or in which there is idiosyncrasy to the drug. If the pupil resists dilatation, the atropin solution should be heated, or a drop of five per cent. solution of cocain every three or four minutes four or five times, and then another application of atropin, should be tried. If the iris is still bound down, six or eight leeches, or a mechanical leech, should be applied to the temple, and mercurial inunctions begun, using a hot bath and profuse diaphoresis before each inunction. Atropin must be kept up throughout the treatment. If it causes much conjunctivitis, scopolamin may be substituted. The pain is best relieved by local depletion with leeches, or artificial scarification over the temple, or hot, moist compresses to the eye for fifteen minutes every two hours. Antipyrin, morphin, or other analgesic may be administered. Profuse diaphoresis, with a Dover's powder, hot drink, foot-bath, and blankets, is of great value, and may be repeated several times. If all other means fail, puncture of the cornea will relieve the tension. Iridectomy is not indicated in the inflammatory stage except when there is a circular synechia obliterating communication between the anterior and posterior chambers. If there are enough adhesions left to warrant belief that there will be future relapses, iridectomy should be performed after the inflammation has subsided. This is a prophylactic measure of great importance. Smoked glasses should be worn all through the disease. Alcoholic beverages should be interdicted.

SEROUS IRITIS.

Definition.—A chronic inflammation in which an inflammatory product, poor in cells, settles in the anterior chamber, causing a haziness of the aqueous, and deposits on the posterior surface of the cornea (Fig. 85), on account of which the disease is sometimes called *desce-metitis*.

Symptoms and Diagnosis.—The chief objective signs are the deposits in the aqueous and on the back of the cornea, the haziness of the aqueous, the increase in the depth of the anterior chamber, and *the signs of acute iritis* in a milder degree. Pain and other subjec-

tive symptoms are inconsiderable, and the pupil may be dilated. There is often a rise of tension, due to the chemic and physical changes in the aqueous, causing simulation of glaucoma (see table, pages 162 and 163).

The important sequels are striated opacities on the back of the cornea, which never quite clear up, posterior synechia, and, if the ciliary body is affected, vitreous opacities, and possibly opacities in the lens.

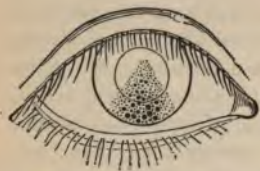

FIG. 85.—SEROUS IRITIS.
DESCEMETITIS.

Causes.—Serous iritis occurs in debilitated and anemic young persons, and has been ascribed to syphilis and other general dyscrasias. It is commonly bilateral, which fact points to a systemic cause. It may occur after cataract operations.

Treatment.—The patient's general health should be attended to, and good food and hygienic measures instituted. To keep the pupil dilated and break up adhesions, atropin twice a day is necessary. To hasten absorption of the inflammatory products, heat, diaphoresis, and the iodids are useful. The depressed physical condition of the patient generally forbids any rigorous mercurial treatment. The deposits may be mechanically removed by releasing the aqueous by repeated paracenteses. If there is much rise of intraocular tension, atropin must be suspended and eserine substituted. Repeated paracenteses will here prove of great value. Iridectomy may be indicated in the worst cases.

SUPPURATIVE IRITIS.

Definition.—A condition in which the inflammatory product is purulent, and saturates the tissues of the iris and overflows into the anterior chamber forming a *hypopyon*, which is more fluid than the hypopyon following inflammation of the cornea.

Symptoms.—In this condition the iris is highly hyperemic, and is swollen and discolored yellow by the pus in its matrix. The chief symptoms are: The marked changes in the iris; the swollen pupillary border of the iris, which often occludes the pupil; the fluid *hypopyon*, which changes position, in distinction to the stationary fibrinous *clot of pus in corneal disease*; and history of infection, chiefly *through a wound*. In this day of aseptic precautions, suppurative

iritis after operation is very rare. Diabetes is said to be a systemic cause. If the disease is due to infection through a wound or following an operation, there is great danger of general involvement of the eye, and such cases should be regarded as very dangerous. What have seemed idiopathic cases, have often yielded readily to treatment and left no sequels.

Treatment is that of simple iritis, and should be energetically pursued—rapid mercurial inunctions, atropin, and paracenteses, after the height of the inflammation has been passed. For idiopathic or diabetic cases, the salicylates have been used to great advantage.

IRITIS NODOSA is an inflammation in which small nodes or tubercles are seen on the iris. Nodules are sometimes noticed on the iris in both simple and suppurative iritis, but the name is usually applied to conditions in which small gummata or tubercles are found on the iris.

Gumma of the iris is a local expression of tertiary syphilis, and generally yields to antisiphilitic treatment. There is usually seen near the pupillary edge of the iris a yellowish mass, about the size of a split pea, surrounded by a brownish-red base. A history of syphilis is generally obtainable.

Tubercles of the iris usually occur in groups, are some distance from the edge of the iris, and are grayish or pale yellow in color. The adjacent lymph-glands are swollen, and there is a history of tuberculosis. Tubercular iritis usually attacks young persons, while gummata are mostly seen in advanced life. Gummata may disappear under the iodids and mercurials, or may leave the iris atrophic or immobile. In tubercular iritis the prognosis is bad. In severe cases the eye must be enucleated. Excision of the tubercles is useless.

CYSTS, ranging in size from that of the head of a pin to that of a small pea, may form on any part of the iris. They may be single or multiple, and are generally the result of traumatism. They should be completely removed by an iridectomy.

MALIGNANT TUMORS have been noticed in the iris, and are usually sarcomatous. Rapid growth of any iridic tumor suggests malignancy, and removal, together with the neighboring tissue, by a large *iridectomy is demanded*.

INJURIES TO THE IRIS.

PENETRATING WOUNDS OF THE IRIS are recognized by focal and oblique illumination; there appears a rent, through which the fundus-reflex shines, provided, of course, the media are still clear.

IRIDODIALYSIS is a condition in which the iris is torn away from the ligamentum pectinatum and ciliary body. It is usually the result of a severe blow. It is attended by *hyphemia*, or hemorrhage into the anterior chamber. The blood in the chamber will absorb, but no treatment will restore the detached iris. In cases of hyphemia a cautious prognosis should be given, for when the blood in the anterior chamber becomes absorbed, more serious choroidal and retinal hemorrhages may be found. Paralysis of the iris, or *iridoplegia*, may be a result of traumatism.

FOREIGN BODIES in the iris, as a rule, cause inflammation, although there are instances in which aseptic particles have remained for years without causing any difficulty. As the aqueous soon becomes clouded, removal should be attempted at once. This is effected by corneal section and removal of the substance with a fine pair of forceps. If the foreign body is a particle of iron or steel, the magnet may remove it. If this fails, the fold of iris in which the foreign body is included should be seized and excised.

CONGENITAL MALFORMATIONS.

ANIRIDIA, or absence of the iris, is rarely seen, and is usually bilateral.

COLOBOMA is the most frequent congenital defect of the iris. It is an aperture in the iris, generally beneath the pupil, and, unless very extensive, causes little visual disturbance. It is sometimes associated with coloboma of choroid or lens.

POLYCORIA is a multiplicity of pupils.

ANOMALIES OF COLOR of the iris are often seen, and have no significance. Sometimes the pupils are of different colors, or one pupil may be of several different colors.

In ALBINISM there is a lack of pigment in the iris, in consequence

of which there is intense photophobia, nystagmus, ametropia, and lessened visual acuity.

PERSISTENT PUPILLARY MEMBRANE is a remnant of a vascular connective-tissue layer that, in the embryo, enveloped the lens before the iris was formed. In this condition very fine fibers, springing from the anterior surface of the iris, pass over the pupil to be attached to the anterior surface of the lens. There is usually no visual disturbance.

CHANGES IN THE MOTILITY OF THE PUPIL.

MYDRIASIS, or extreme dilatation of the pupil, occurs under the effects of drugs possessing a mydriatic action, such as atropin, homatropin, hyoscyamin, etc.; in glaucoma; in optic nerve atrophy; in diseases of the orbit; after fright; in neurasthenia; after irritation of the cervical sympathetic, as by an aneurysmal tumor; and sometimes in idiots. Permanent mydriasis has occurred after the instillations of a mydriatic have been suspended. Mydriasis of distinctly cerebral origin is caused either by irritation due to some lesion in the brain or cervical portion of the spinal cord, or by paralysis of the oculomotor center, due to hemorrhage, thrombosis, tumor, or abscess of the brain.

The treatment of mydriasis consists in remedying the cause, if possible; locally, pilocarpin or eserin is indicated, and the galvanic current is sometimes of use. Exercise of the eyes with convex lenses upon near objects may be of value.

MIOSIS, or permanent contraction of the pupil, occurs under drugs possessing miotic action, such as eserin, pilocarpin, etc.; in paralysis of the cervical portion of the spinal cord, particularly in locomotor ataxia; in parietic dementia; in cerebral syphilis; and in bulbar palsy, with progressive muscular atrophy. Persons who continually use their eyes on fine objects, such as watchmakers and engravers, sometimes suffer from miosis. In opium poisoning the pupil is reduced to the size of a pin-point, dilating just before death. Nicotin and alcohol in poisonous quantities may produce miosis. As contraction of the pupil may result from irritating cerebral lesions similar to those causing dilatation, it is important to have some means of differential diagnosis. Berthold mentions that miosis occurs in a sudden attack of paralysis due to embolism, and mydriasis in an attack due to

hemorrhage. The treatment is directed to the cause. Atropin may be used locally.

ANISOCORIA, or **INEQUALITY** in size of the pupils, may occur in perfect health. In fact, it is much more common than text-books indicate. It is sometimes seen in eyes of widely dissimilar refraction, diseases of the brain and nervous systems, and in insanity. It is not uncommon in tabes, disseminated sclerosis, and parietic dementia.

WERNICKE'S SIGN, OR **HEMIOPIC PUPILLARY INACTION**, is mentioned in the discussion of hemianopsia. Light is carefully thrown on the blind side of the retina; if there is reflex contraction, the lesion is behind the pupillary centers; if there is no reflex obtained, the lesion is at or in front of the pupillary centers.

THE ARGYLL ROBERTSON PUPIL is a name given to a reflex pupillary rigidity producing loss of reaction to light-stimulation, although the action to accommodation and convergence may still be present. It is a diagnostic sign of value in locomotor ataxia, but has been noticed in general paralysis of the insane, in cerebral syphilis, and is the result of poisoning by bisulphid of carbon.

THE ORBICULARIS PUPILLARY REACTION refers to contraction of the pupil when a forcible effort is made to close the lids.

HIPPUS is the name given to the oscillations occurring after contraction to light. It is exaggerated in hysteria, disseminated sclerosis, epilepsy, and in the early stages of acute meningitis.

IRIDODONESIS is a tremulous condition of the iris, due to lack of a normal support of the lens. It is seen in conditions in which the lens is dislocated posteriorly, in atrophy of the vitreous, in overripe cataract, and after cataract extraction.

OPERATIONS ON THE IRIS.

IRIDECTOMY is the excision of a portion of the iris. It is performed in glaucoma, in cataract extraction, for the removal of foreign bodies and growths, in complete synechias, and for optic purposes. Having first secured a lid-speculum in position, a fold of conjunctiva, near *the cornea and opposite* the place where the incision is to be made, *is seized by fixation forceps*. A keratome is entered through the

cornea at the scleral border, the point being kept nearly perpendicular to the sclera until it has reached the anterior chamber, when the handle is depressed so as to bring the blade parallel to the iris (Fig. 86). The blade is then pushed forward until it has made a wound

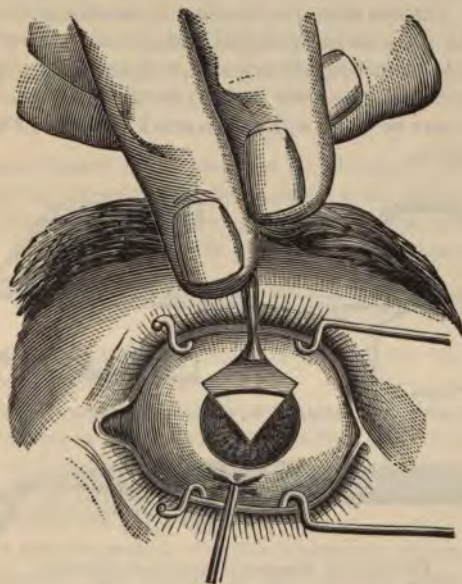


FIG. 86.—INCISION WITH KERATOME IN IRIDECTOMY.



FIG. 87.—IRIS FORCEPS, CURVED.

sufficiently large for the purpose of the operation; still depressing the handle, the blade is withdrawn slowly, and iris forceps (Fig. 87) are thrust through the wound closed, and opened in the anterior chamber to seize the iris. The iris is then drawn out of the wound, and as much of it as desired is excised by fine

scissors (Fig. 88) held firmly against the eyeball and parallel to the wound. The stump of the iris is then carefully returned to the anterior chamber, no portion of it being allowed to become incarcerated in the corneal incision. The delicate McClure iris-scissors are the best for cutting the iris, but they are rather expensive, and not always obtainable. The eye should be thoroughly cocainized, and the operation should be done under antiseptic precautions; after the operation the eye should be thoroughly irrigated, a light bandage applied, and the eye kept closed until the corneal incision has become united. The incision may be made with the Graefe knife instead of the lance-shaped keratome.



FIG. 88.—IRIS SCISSORS, STRAIGHT, CURVED, ANGULAR.



FIG. 89.—DE WEAVER'S IRIDOTOMY SCISSORS.

IRIDOTOMY is performed when the pupil for any reason is occluded by a thickened and opaque capsule, or with exudations from the iris. One mode of operation is with a needle-knife, having a double cutting-edge, with its shank so constructed as to completely fill the corneal wound, thus preventing any escape of aqueous. This knife is thrust through the cornea midway between its center and circumference, and the occluding membrane is divided at right angles with the line of greatest tension. When the iris is to be incised so as to make an artificial pupil, a lance-knife is used instead of a needle-knife, and introduced in the same way as before, and withdrawn half way, allowing some of the aqueous to escape, thus carrying the iris forward. The knife is thrust through the iris and then withdrawn. De Wecker's scissors for iridotomy (Fig. 89) are entered closed, and

opened in the anterior chamber, one blade passed through the cut in the iris, and the blades brought together through the iris, thus elongating the incision.

IRIDOCYSTECTOMY is preferable to iridotomy. An incision is made with a Beer's knife through cornea, iris, and the thickened or adherent lens-capsule. Next a Tyrrell hook, or one branch of a pair of iris forceps, is passed into the opening in the iris. The edge of the iris (and capsule) is drawn out of the corneal wound and cut off close to the cornea.

IRIDODESIS consists of drawing the pupil into a new shape and position, and is accomplished by making a small incision in the cornea and drawing a part of the iris, including some of the pupillary border, into it, and fixing it with a ligature. This operation is now almost obsolete.

CYCLITIS.

Definition.—Inflammation of the ciliary body; the iris and choroid are often simultaneously involved.

Varieties.—The *serous*, which is comparatively benign, and develops like a serous iritis; the *plastic*, which is a worse form and produces a total posterior synechia; and the *suppurative*, which is distinguished from the others by the presence of a purulent exudate in the chambers of the eye.

Symptoms and Diagnosis.—Cyclitis is always a serious and often a dangerous disease, and should be differentiated from a relatively benign iritis. Pain, photophobia, lacrimation, and visual disturbance are signs common to both. The characteristic signs of cyclitis are extreme sensitiveness to pressure in the ciliary region; cloudiness in the anterior portion of the vitreous; and the noticeable changes in the intraocular tension, which is increased at first and diminished later. The aqueous is also turbid, and may contain pus of the suppurative variety.

Causes.—Generally some injury to the ciliary body or adjacent tissues. Foreign bodies in the eye are almost certain to destroy the eye by a plastic cyclitis. It is likely that there is more or less cyclitis in most cases of iritis—that is, iridocyclitis is more frequent than simple iritis or cyclitis. Cyclitis may be due to inflammation of the tissues in continuity with the ciliary body, or to symp

ophthalmia. Idiopathic cases are said to result from syphilis, tuberculosis, rheumatism, and other systemic disorders.

Treatment is virtually the same as that for iritis, although atropin must be used with caution, as it is often very poorly borne. Plastic and purulent cyclitis must be treated rigorously with mercurial inunctions. For the reduction of tension, the local use of eserin, diaphoretics, and paracentesis are indicated. In purulent cyclitis, especially after operations, antiseptic douches are indicated. On account of the uncertain prognosis, the possibility of relapses, disorganization of the vitreous, and sympathetic ophthalmia, the patient must be carefully watched, and expectant treatment continued after the symptoms have subsided.

PARALYSIS AND SPASM OF THE CILIARY MUSCLE.

Paralysis of the ciliary muscle is recognized by destruction or diminution of the normal range of accommodation that usually corresponds to the age of the patient. The causes may be peripheral, as by atropin; or central, due to disturbance of the oculomotor nucleus. General intoxication by the poisons of infectious diseases, and conditions producing exhaustion or debility, may result in paralysis of the ciliary muscle. Diphtheria is a common cause. The iris may or may not be involved in the paralysis. In this condition objects seem minimized—*micropsia*. The treatment is directed toward the cause. Locally, miotics, convex glasses, and electricity may be of value.

Spasm of the ciliary muscle is a condition in which the range of accommodation is shortened, causing an emmetrope or hyperope to have myopic symptoms. In this condition objects appear enlarged—*macropsia*. The causes are the miotics, strain on the accommodation, and severe disease of the spinal cord. The treatment is directed toward the cause. Mydriatics give temporary relief. This condition is discussed in the section on *Ametropia*.

DISEASES OF THE CHOROID.

Anatomy.—The choroid is the vascular and pigmentary tunic of the eyeball, investing the posterior five-sixths of the globe, extending as far forward as the cornea, and developing the ciliary processes from its inner surface anteriorly. It is pierced behind by the

optic nerve. Externally it is connected by a fine cellular web (*membrana fusca*) with the inner surface of the sclerotic. Internally it lies in contact with the basal membrane of the pigment-coat of the retina, as far forward as the ora serrata. The choroid is divided into two layers: an external, containing the larger vessels and the most pigment, and an internal. The *external layer* consists in part of the larger branches of the short ciliary arteries, which run forward between the veins before they bend down to terminate in the capillaries; but is principally formed by converging veins called *venæ vorticosæ*. The *internal layer* consists of an exceedingly fine capillary plexus, formed by the short ciliary vessels, and is known as the *tunica ruyschiana*. On the inner surface of this tunic is a very thin homogeneous membrane called *lamina vitrea* that separates it from the pigmentary layer of the retina. The pigment of the choroid consists of hexagonal cells, filled with dark-brown granules, and is scattered throughout both layers in sufficient quantity to absorb the light.

CHOROIDITIS.

Causes.—Inflammation of the choroid results from general diseases, such as syphilis, tuberculosis, scrofula, chlorosis, rheumatism, and gout. Senile choroiditis is probably preceded by choroidal apoplexy. Suppurative choroiditis is due to traumatism with infection; to metastatic infarction, in pyemia and endocarditis; and to severe infectious fevers. High myopia, by causing extreme stretching of the choroid, often gives rise to a local or diffuse inflammation. Choroiditis may be an accompaniment of inflammation of the iris and ciliary body.

Varieties.—For convenience, choroiditis may be divided into the exudative and suppurative varieties, although many subdivisions, such as *disseminated*, *syphilitic*, *areolar*, *central*, *guttate*, etc., have been studied pathologically.

EXUDATIVE CHOROIDITIS is distinguished by the impairment of vision due to the simultaneous involvement of the retina, and the changes noticed by the ophthalmoscope. The disease runs its course without pain and without external symptoms, and the patient is only aware of his trouble through the impairment of vision. It must be remembered that there is no definite relation between the amount of visual disturbance and the changes noted in the fundus.

Alteration in the field of vision, the appearance of scotomas, metamorphopsia, night-blindness, flickering spots, and progressive lessening of the visual acuity, are the most important subjective symptoms. The ophthalmoscope shows the presence of numerous dispersed patches in the fundus, thickly strewn near the equator, gradually diminishing toward the macula and optic disc, these being generally free from disease. If fresh, the patches are round, sharply defined, much smaller than the disc, and yellowish-red, lighter in color than the fundus. In addition, there are yellowish-white streaks along the

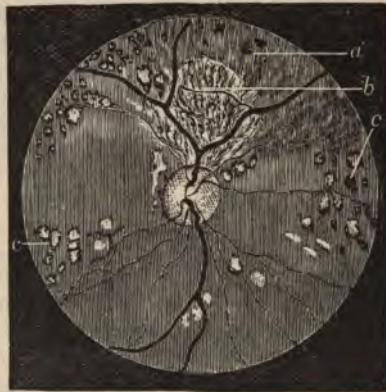

FIG. 90.—ATROPHY AFTER SYPHILITIC CHOROIDITIS, SHOWING VARIOUS DEGREES OF WASTING.

a. Atrophy of pigment epithelium. *b.* Atrophy of epithelium and choriocapillaris,—the large vessels exposed. *c, c.* Spots of complete atrophy, many with pigment accumulation.

vessels. As the disease advances, the patches become larger and coalesce into irregularly-shaped figures, showing the white sclerotic beneath, surrounded by hypertrophied pigment epithelium of the retina. In the majority of cases permanent white patches are left, either due to exposure of the sclera or to reflection from cicatrices (Fig. 90). The optic disc is generally slightly red and cloudy. The term disseminated choroiditis is often applied to cases in which the spots in the fundus are numerous and diffuse. *Areolar choroiditis consists of black patches and small pigment-blotches, gradually changing to whitish blotches with black edges.* It is confined to the

posterior pole of the eye, and endangers central vision. The central variety is located directly at the macula. Sometimes retinal vessels can be traced over spots of choroidal atrophy, showing that the choroid is the primary seat of the lesion. The vitreous is generally clear, and good ophthalmoscopic images are obtained.

SYPHILITIC CHOROIDITIS is diagnosed by syphilitic history and speedy reaction to mercurial inunctions; the most characteristic signs are night-blindness and circumscribed scotomas in the field of vision. Vitreous opacities are also said to be more numerous in this variety.

SUPPURATIVE CHOROIDITIS begins with hemorrhage into the retina and choroid, which is soon followed by purulent infiltration of the whole interior of the eye. Externally, the lids and conjunctiva are red and swollen, and are covered with a purulent secretion; the cornea is hazy, and there may be hypopyon; the iris is inflamed, the pupil appears yellowish, and the eyeball is hard. The patient suffers intense pain, has acute febrile symptoms, and is blind in the affected eye. Viewed by the ophthalmoscope, the golden reflex, due to the exudative material thrown out between the choroid and the retina, confirms the diagnosis, although in children it may be mistaken for glioma of the retina. The inflammation may subside, but it is rare for any visual perception to be preserved. In the malignant form panophthalmitis ensues, and the whole eye becomes an abscess-cavity, and is lost. The infection is often metastatic.

MYOPIC CHOROIDITIS is due to the ectasia or staphyloma of the sclera at the posterior pole, and is usually present in high degrees of myopia, and always in progressive myopia. The increased "myopic crescent," producing an enlarged blind spot, and the ordinary symptoms of myopia associated with the atrophic changes of the choroid, furnish a ready means of diagnosis.

ANTERIOR SCLEROCHOROIDITIS involves the anterior part of the choroid, inaccessible to the ophthalmoscope. It is differentiated from episcleritis, which is a benign local disease, while the former attacks the cornea, iris, and anterior portion of the vitreous, finally causing anterior ectasia of the sclera.

Prognosis of choroiditis is, on the whole, unfavorable. In the exudative variety and in high myopia, we can hope to retain only part of the vision left. In case of large ectasia there is constant danger

of increase in inflammation and glaucomatous symptoms. If anterior ectasia is produced, blindness follows through flatness and opacity of the cornea, increased tension, and distortion of the eyeball. In suppurative choroiditis the eye may be preserved, but vision is inevitably lost.

Treatment of choroiditis must be directed against any discoverable cause. In all acute cases, whether syphilitic or not, in which the patient is in fairly good health, mercurial inunctions should be begun. In debilitated cases, constitutional and tonic treatment should be instituted, diaphoresis provoked, potassium iodid administered, and rest, with smoked glasses, ordered. Confinement in a dark room is unnecessary. In subacute or chronic cases, administration of the following is advised :

Mercuric chlorid, gr. ij.
 Extract of belladonna, gr. iv.
 Make 40 pills.
 Take one pill three times a day.

In the suppurative variety we can do no more than to quiet pain by narcotics, or by the local use of atropin and hot compresses. If the eye is a virtual abscess, it should be incised or enucleated under the strictest antiseptic precautions. In the anterior variety, tension must be carefully watched, and if excessive, may be relieved by corneal puncture or iridectomy. The treatment of progressive and high myopia is discussed under Myopia.

TUBERCULOSIS OF THE CHOROID is of two forms, the first manifesting itself in small, whitish-yellow spots, that are minute tubercles, near the posterior pole of the eye; many are too small to be visible by the ophthalmoscope. The second form is a spheroid tubercle causing detachment of the retina, and possibly inflammation of the eye. It is to be distinguished from sarcoma of the choroid, but in both cases enucleation is preëmporarily demanded.

SARCOMA OF THE CHOROID develops slowly at first, but later on involves the surrounding tissue with great rapidity. In the first stage the only subjective symptom is disturbance of vision, the eye becoming more myopic, and distortion of images ensuing. The sarcoma is usually at the posterior pole. Viewed by the ophthalmoscope, *as a rule nothing but* retinal detachment is distinctly elicited.

In the second stage, severe pain caused by increased tension is noticed, and total blindness ensues. The media become so cloudy that no reflex is obtainable. After this the growth penetrates the sclera, the whole eye becomes a malignant mass, and even if metastasis has not occurred, the patient may die of exhaustion. The disease is unilateral, and should be distinguished from glaucoma, in which there is no retinal detachment; and from simple retinal and choroidal detachment, in which there is no increase in tension. It is generally followed by sarcoma of the liver. The more fibrous the tumor, the less the liability to metastasis. As soon as the disease is recognized, the eye should be enucleated and the orbit thoroughly cleaned out, as death will speedily ensue if the disease is allowed to continue.

RUPTURE OF THE CHOROID (Fig. 91) is due to injury of the eye, and, as a rule, can not be recognized until the vitreous becomes transparent, after which a recent rupture appears as a yellowish, blood-specked stripe, which finally becomes white and is bordered with a black pigment. The extent of visual disturbance depends essentially upon the portion of the choroid involved. Peripheral rents have little influence on vision. The ruptures are generally near the optic nerve and parallel to its circumference. The treatment consists of atropin and rest.

DETACHMENT OF THE CHOROID is recognized with the ophthalmoscope as a round or oval, brown, and smooth tumor near the equator of the eye, that does not have the trembling movements accompanying movement of the eye, as is seen in detachment of the retina. Choroidal detachments may reunite. Loss of vitreous during cataract operation or an effusion between the choroid and sclerotic have been causes. The treatment is absolute rest.

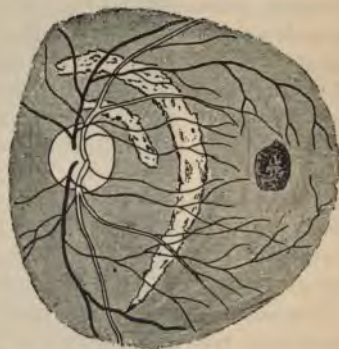

FIG. 91.—TWO RUPTURES IN THE CHOROID.—(After Knapp.)
The retinal vessels pass unbroken across the rupture. The dark spot to the right is a hemorrhage.

COLOBOMA OF THE CHOROID appears as a large white or bluish, glistening area, usually below the disc, and several times its diameter. Retinal blood-vessels pass across it. It is simply a congenital deficiency in the choroid that allows the sclerotic to show through, and often causes but little visual disturbance. It may be associated with coloboma of the iris or other anomalies of the eyeball.

DISEASES OF THE RETINA.

Anatomy.—The retina is the chief and essential peripheral organ of vision, and constitutes the third or internal coat of the eyeball. It is made up of the end-organs, or expansion of the optic nerve within the globe of the eye. It is composed of three main layers: the inner, of fibers and nerve-cells, the granular middle layer, and an internal layer composed of rods, cones, and pigment. Microscopically it is divided into ten layers, from without inward, as follows: (1) Pigment cells; (2) rods and cones; (3) external limiting membrane; (4) external granular layer; (5) outer molecular layer; (6) internal granular layer; (7) internal molecular layer; (8) a ganglionic layer; (9) nerve-fibers; (10) internal limiting membrane; the exact construction of the retina is diagrammatically shown in figure 92.

The *rods and cones* are the essential sight-elements. The retina is about 0.25 mm. in thickness, and covers the under surface of the choroid from the optic nerve entrance to the dentated anterior margin of the retina, called the *ora serrata*, a few millimeters back of the ciliary body. The most sensitive portion of the retina is a yellowish spot, about 0.5 mm. in diameter, lying to the temporal side of the optic disc, which, from its color, is called the *macula lutea*. In the center of the macula is a reddish dot called the *fovea centralis*, at which point all the layers of the retina, with the exception of the cones, are absent. The *vascular supply* of the retina is from the central artery and vein, which, passing through the *porus opticus* of the *lamina cribrosa*, divide over the optic disc, vertically into large and horizontally into small vessels, which are distributed in the fiber-layer of the retina, anastomosing at the entrance of the optic nerve with the *short ciliary vessels*, and anteriorly at the *ora serrata* with the *choroidal vessels*.

HYPEREMIA OF THE RETINA is detected by an increase in the size of the retinal vessels, particularly noticeable over the disc, which appears pinkish in contrast. It is caused by stasis or irritation. In



FIG. 92.—VERTICAL SECTION OF THE RETINA.

1, 1. Layer of rods and cones. 2. Rods. 3. Cones. 4, 4. Membrana limitans externa. 5, 5. Outer and inner granular layers. 6. Outer granular layer. 7. Intergranular layer. 8. Inner granular layer. 9. Layer of gray matter. 10. Granular portion of this layer. 11. Cellular portion. 12, 12. Fibrous layer. 13. Membrana limitans interna. 14, 14. Radiating fibers inserted into this membrane.

stasis-hyperemia the thickness of the veins in comparison with the arteries is noticed. Irritation-hyperemia usually accompanies inflammation of some other portion of the eye, or it may

strain. It is quite common in persons with some uncorrected refractive error or muscular imbalance, who use their eyes to excess.

Treatment should be directed to correction of any ametropia or muscular trouble, and the eye should be put at rest and shielded with protective glasses. If the hyperemia is supposed to be a local expression of cerebral congestion, the treatment for the latter affection should be instituted.

RETINAL HEMORRHAGE.

Causes.—Retinal hemorrhage is seldom an independent affection, but is usually associated with some disease or injury of the retina; or it may be the result of some condition provocative of hemorrhage in any other organ, such as atheroma of the arteries, hypertrophy of the left ventricle, scorbutus, hemorrhagic purpura, nephritis, diabetes, pernicious anemia, etc. In such conditions the immediate cause may be muscular strain, violent coughing, or sudden change in the intraocular tension after operation. Hemorrhage following occlusion of the retinal vessels will be mentioned later.

Diagnosis with the ophthalmoscope is easy if the media are clear and if the remaining portion of the retina and disc is unaffected. In such a case a fresh clot appears as a bluish-red blotch on a white background; or, if the clot is old, a brownish-red blotch is seen; or the only remnants of the hemorrhage may be a spot of yellowish-white degeneration, perhaps associated with pigment deposits. The hemorrhage is flame-shaped when in the internal layers, rounded when in the external layers, and massive when between the retina and hyaloid membrane of the vitreous (*subhyaloid*). If other blotches are seen in the retina and the whole fundus is hazy, the condition is called hemorrhagic retinitis.

Prognosis depends on the cause and recurrence of hemorrhages; unfortunately, the prognosis of affections causing retinal hemorrhage is usually bad. The amount of visual disturbance depends on the location and size of the clot. Hemorrhage in the macula is serious. Multiple hemorrhages may cause a glaucomatous condition, producing blindness.

Treatment must be directed to the general causative condition. Patients should be put to bed and the eyes bandaged. Congestion may be relieved by leeches or dry cups to the temples. Mercurials and iodids, together with diaphoresis, may promote absorption.

RETINITIS.

General Remarks.—It is probable that idiopathic retinitis never occurs. Inflammation of the retina is generally due to some disease of the general system, such as syphilis, renal disease, diabetes, leukemia, etc. In cases of prolonged exposure or excessive use of the retina, the resultant affection is more in the nature of a functional trouble than a true inflammation. Retinitis may be due to an extension of inflammation from the neighboring structures, principally the ciliary body, choroid, and optic nerve. Panophthalmitis produces an immediate suppuration of the retina.

The subjective symptoms of retinitis are usually dimness of vision, scotomas, metamorphopsia, etc. The objective symptoms elicited by the ophthalmoscope are sometimes quite characteristic of the causal trouble, although differential diagnosis is at times very difficult. However, the condition discovered is often a valuable indicator in substantiating systemic evidence of the general disease, and is an important factor in prognosis.

ALBUMINURIC RETINITIS becomes almost always bilateral, although a number of unilateral cases are recorded. The light-sense, color-sense, and visual field are usually undisturbed. Dimness of vision progresses slowly, and sometimes it is difficult for the patients to count fingers. This affection often accompanies the nephritis of pregnancy. Uremia, coincident with renal disease, may cause complete blindness, but this can not be attributed to retinitis, but rather to a transient effect upon the cuneus lobe of the uremic poison.

Ophthalmoscopic changes (Fig. 93) differ in the various stages, although they are most marked in advanced renal disease. The changes in the fundus are generally confined to the posterior pole and region adjoining. Hyperemia is at first noticed, but in the advanced disease white spots or patches are seen about the papilla, and later fine white dots are noticed grouped about the macula in the shape of a star with the fovea in the center. Finally, hemorrhages and fatty degeneration, with paleness of the disc and contraction of the vessels, may occur just before death. In some cases, instead of white spots there may be numerous wide-spread hemorrhages, or, again, only congestion and simple redness of disc.

Prognosis.—The exact relation between retinitis and the coinc

renal disease is not definitely established. However, it may usually be said that a definite case of albuminuric retinitis will have fatal issue within two or three years, although the visual disturbance may not increase, and may even improve in fatal, chronic cases. We have, however, seen cases in which the patients have lived from five to ten years after typic albuminuric retinitis had been established. In interstitial nephritis particularly, retinitis is a serious sign. After recovery

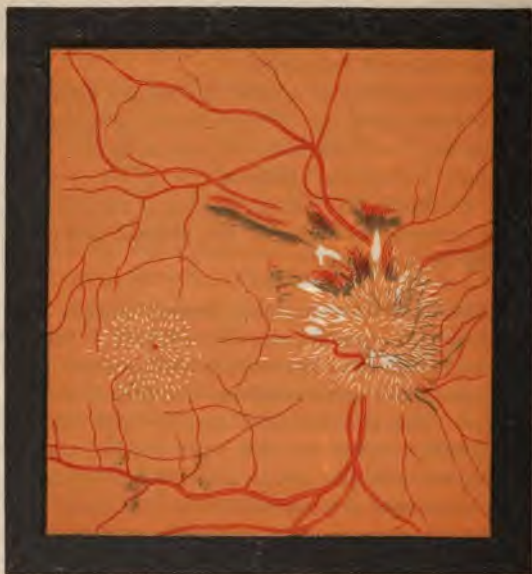

FIG. 93.—ALBUMINURIC PAPILORETINITIS.—(After Liebreich.)

from acute nephritis an associate retinitis may clear up and the vision become normal. The prognosis of both life and vision is better in the albuminuric retinitis of pregnancy, and in cases in which only one eye becomes involved.

Treatment must be that of the original disease. In hemorrhagic cases, rest, bandaging of the eyes, and possibly the instillation of atropin, in weak solution (gr. j to $\bar{3}$ j), are advisable. The appear-

ance of albuminuric retinitis in pregnancy is regarded by many as an indication for the induction of abortion.

DIABETIC RETINITIS is often indistinguishable from albuminuric retinitis by the ophthalmoscope alone. The diagnosis can only be made by the test for glycosuria. The prognosis is possibly not so bad as in the foregoing disease, and dietary and hygienic treatment may establish a cure.

SYPHILITIC RETINITIS is a diffuse instead of a local inflammation, as in the preceding diseases, and may be unilateral or bilateral. A general cloudiness, most apparent at the optic disc, and gradually shading off into the periphery of the fundus, is noticed. White lines may be observed along the course of the blood-vessels. There are numerous dust-like opacities in the vitreous. Hemorrhages are less frequent than in the preceding forms. The treatment is purely constitutional.

LEUKEMIC RETINITIS is characterized by the pale-yellow appearance of the fundus, always bilateral. There is a marked tendency toward hemorrhages; sometimes circular white clots and prominent blood-bordered spots are seen at the periphery of the retina. Diagnosis should be substantiated by microscopic examination of the blood. The treatment is that of leukemia.

RETINITIS OF PERNICIOUS ANEMIA presents an edematous condition of the retina, diffuse retinitis, with distended veins and pallid blood. The disc appears dirty greenish-white, against a yellowish eye-ground.

RETINITIS PIGMENTOSA.

Definition.—A pigmentary degeneration of the retina sometimes found in descendants of consanguineous marriages, or of syphilitic parents. It occurs commonly in members of the same family.

Symptoms and Diagnosis.—The chief subjective symptoms are *night-blindness*, due to the reduced sensitiveness of the retina; *concentric contraction* of the field of vision, often coupled with nystagmus, causing the patient great inconvenience from inability to find his way, although his central vision may be acute. The constant *bowing of the head* in walking is a characteristic sign. T

fundus has a very characteristic appearance (Fig. 94). The disc is yellowish and its edge is somewhat obscured, and the vessels are narrowed, accompanied by fine bands, and fade off into the periphery. Dark streaks of pigmentation, beginning at the periphery, trail over the fundus, and gradually progress toward the macula. In appearance these have been compared to the Haversian bone-canals.

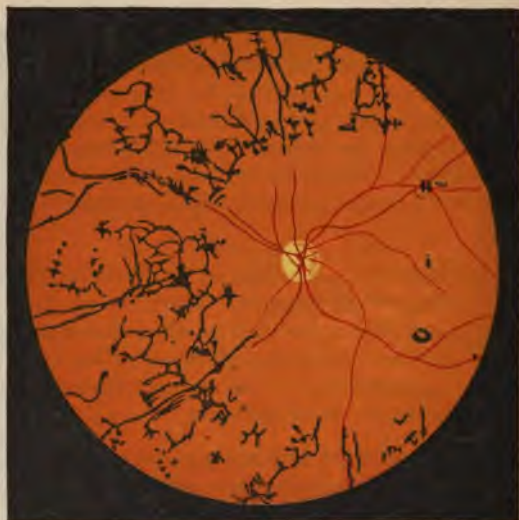

FIG. 94.—RETINITIS PIGMENTOSA.—(After Liebreich.)
The papilla is atrophic, the vessels constricted.

Cases of retinitis pigmentosa without the distinctive pigmentation are occasionally found. There is evidence of pigment-atrophy at the periphery, slightly subnormal night-vision, narrowed color-fields, etc.

Treatment is useless. All that can be done is to keep the patient in good health and spirits, and surround him with hygienic conditions inductive to the arrest of any degenerative process.

THROMBOSIS AND EMBOLISM OF THE RETINAL VESSELS.

Symptoms and Diagnosis.—Embolism of the central artery of the retina is rare. Both the ophthalmic and central retinal arteries branch at right angles from their parent stems, and an embolus is easily swept by them. The characteristic subjective symptom is sudden blindness in one eye, probably after some slight exertion. There may be temporary improvement during the succeeding weeks, but the prognosis is very unfavorable. The differential diagnosis between thrombosis and embolism with the ophthalmoscope is sometimes difficult. Hemorrhages are more numerous in thrombosis, and there is intense swelling of the nerve and retina. There is pallor of the disc and retina in embolism, and marked diminution in the size of the vessels. The veins become tortuous and very irregular. The central portion of the retina becomes hazy and grayish, the macula standing out in sharp contrast by its maintenance of the normal red color, the classic "cherry red spot," supposed to be due to the non-existence of the nerve-fiber layer at the fovea, allowing the choroidal vessels to show through. Finally, atrophy of the disc and retina ensue, and the vessels become obliterated and replaced by white streaks. Involvement of only a branch of the central artery is followed by an anemic and degenerated sector-like area supplied by the affected artery. The diagnosis should be confirmed by the discovery of some systemic source of embolus or thrombus, such as endocarditis, or other organic heart-affection, phlebitis, pyemia, etc.

Treatment is of little avail; but sometimes in very recent cases it may be possible to remove the embolus by massage of the eyeball, or by reduction of the internal tension, as by sclerotomy. General treatment is, of course, indicated.

DETACHMENT OF THE RETINA.

Causes.—The most common cause is disease of the choroid consequent upon myopia of high degree. Chronic inflammation of the eyeball or of the retina alone, fluid effusions or hemorrhage between the retina and choroid, injuries, new growths, diseases of the vitreous, removal or dislocation of the lens, and parasites, are other causes. *Any condition in which the intraocular tension is suddenly lowered—*

as, for instance, by the rapid escape of vitreous after a corneal section—predisposes to retinal detachment.

Symptoms and Diagnosis.—The premonitory signs are flickerings and the appearance of dazzling sparks before the eyes, and attacks of momentary blindness. The detachment takes place suddenly, and the field of vision is obscured by what seems to be a dark cloud before the eyes. The detachment is only partial at first, and the retina is still nourished by its own vessels, its functions being impaired rather than destroyed. Naturally, the refractive condition of the eyes is more hyperopic, but as the detached portion of the retina constitutes irregular folds which constantly move with every movement of the eye, metamorphopsia and other anomalous visual disturbances are present. By the ophthalmoscope there is absence of the red reflex in the region



FIG. 95.—OPHTHALMOSCOPIC APPEARANCE OF DETACHED RETINA (ERECT IMAGE).—(After de Wecker and Jaeger.)

of the detachment. In advanced cases a bluish-gray curtain is seen floating freely in the vitreous, and may even be seen by the naked eye (Fig. 95). The picture may be confused by vitreous opacities, which frequently accompany this condition.

Prognosis is dependent on the cause. If caused by intraocular tumor, the case may be considered hopeless. If due to pronounced myopia, one eye is usually attacked after the other, and blindness is unavoidable. In the other conditions the progress of the detachment may

possibly be arrested, but we can hardly hope for improvement, although instances of alleged reattachment without treatment have been reported.

Treatment consists of prolonged rest in bed, with protection of the eyes from light by a pressure-bandage. Antiphlogistic measures should be adopted; diaphoresis with the salicylates, or by hypodermic injection of pilocarpin, may prove of benefit.

The operative treatments that have recently been recommended are puncture through the sclerotic, allowing escape of the subretinal fluid, injection of an artificial vitreous in front of the prolapsed retina, or injection of a few drops of iodine in the vitreous. The real value of these measures is doubtful.

GLIOMA OF THE RETINA.

Definition.—A malignant tumor, soft and highly vascular, developing in the retinal connective tissue, which, in common with the cerebral connective tissue, is sometimes designated *neuroglia*.

Symptoms.—It occurs chiefly in children from one to four. On account of the youth of the patient and the absence of pain, the early subjective symptom—visual disturbance—escapes unnoticed. The child may be totally blind for some time without the parents' knowledge, attention to the eye first being called by the bright shimmer in the pupil, the so-called "cat's eye." In the first stage of the disease the ophthalmoscopic examination shows a yellowish prominence surrounded by small nodules, toward which dilated retinal vessels converge. In the second stage there is probably increased tension, and the growth begins to push its way forward, carrying the retina, lens, and iris with it. The cornea and the aqueous may become opaque, and the conjunctival vessels intensely congested. Internal inflammation progressively increases, and the tumor may escape through a perforation in the cornea or penetrate the sclera, and appear as a spongy, bleeding mass between the lids. The final stage is extension along the optic nerve, or metastasis to the neighboring structures.

Diagnosis is easy after the second stage is reached. In their early stages, suppurative choroiditis or hyalitis may produce symptoms so closely resembling glioma that they have been called pseudoglioma. However, in choroiditis inflammation precedes the blindness, and the eye is soft. If there is doubt as to the diagnosis, the case should be treated as glioma, to prevent an error which may prove fatal.

Prognosis.—Unfortunately, it is usual for the child to be brought for treatment after the disease has progressed sufficiently to cause the "cat's eye" or other prominent objective symptoms, and it may be too late even to save the child's life. There is absolutely no hope of preserving the affected eye.

Treatment.—Not only should the affected eye be immediately enucleated, but the optic nerve should be divided as far back as possible, and if there is the slightest sign of invasion of the orbital tissues, they must be removed and the orbit cauterized.

INJURIES TO THE RETINA.

Ordinarily, injuries of the retina are coincident with injuries to other parts of the eye, and the treatment is general rather than special.

DAZZLING from exposure to intense light may result in partial or complete loss of sight. Such cases often follow the observance of an eclipse of the sun. In severe cases a central blind spot is produced, and the ophthalmoscope shows an opaque grayish spot in the macula, probably due to a definite chemic change of the substance of the retina. In such cases a permanent central scotoma remains, in spite of treatment by rest in a dark room, leeches, electricity, strychnin, etc.

OPAQUE OR MEDULLATED NERVE-FIBERS are sometimes discovered by the ophthalmoscope. They are seen as white, striated blotches with fringed edges, along the direction of the principal vessels, and together present a flame-like shape. When they can not be directly traced to the disc, they may be confounded with pathologic changes. In the vast majority of cases they cause no visual disturbance. The condition is due to the retention of the opaque medullary sheath of the fibers, or "white substance of Schwann," after they leave the lamina cribrosa to expand into the retina.

DISEASES OF THE OPTIC NERVE.

Anatomy.—The fibers of the optic nerves arise in two bands, called the *optic tracts*, from the corpora geniculata, corpora quadrigemina, and ophthalmic ganglion, which in turn are connected by radiating fibers with the center in the occipitoangular region of the cortex (Fig. 96). Each optic tract winds obliquely across the corresponding crus cerebra, and converges forward to meet its fellow, forming at their intersection the *optic commissure* or *chiasm*, which is composed of six sets of fibers—viz., a set crossing from the right side of the brain to the left eye; a second set, pursuing the same course from the opposite side—*decussating fibers*; a third set, anterior, connecting the *two retinas*—*interretinal fibers*; a fourth and a fifth set, lateral, connecting the hemisphere of one side with the retina of the same side—*cerebroretinal*; and a sixth set, posterior, connecting one optic tract

with the other—*intercerebral*. The optic nerves diverge from the chiasm to pass through the optic foramen in each sphenoid bone.

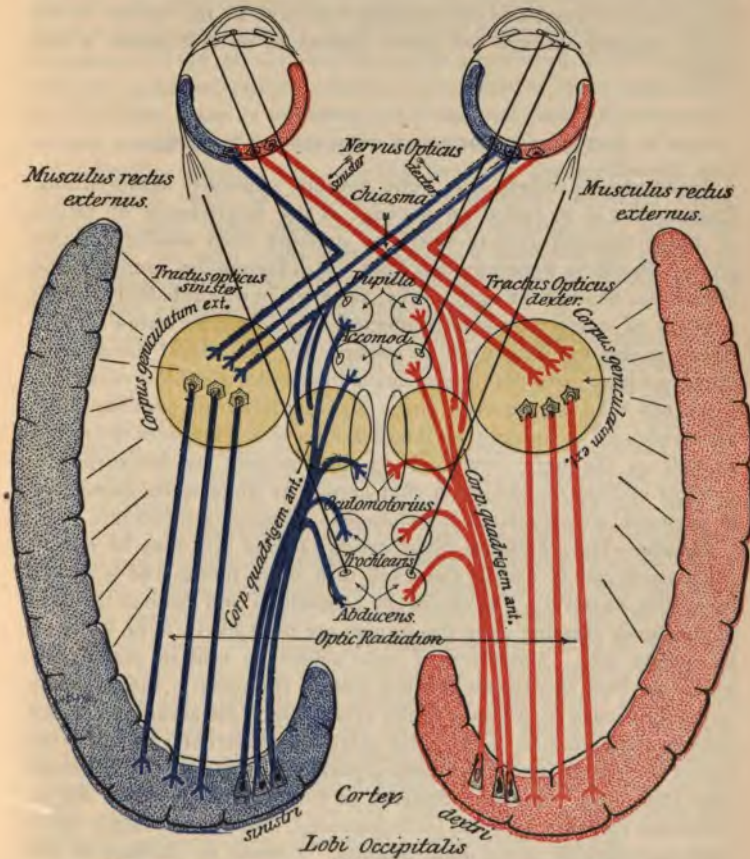


FIG. 96.—SCHEME OF THE OPTIC TRACTS.—(After von Monakow.)

The nerve is covered by prolongations of membranes of the brain as far as the lamina cribrosa, at which point the dura mater fuses with the sclera, the other membranes are disconnected, the me

covering of the nerve-fibers ceases, and the axis-cylinders pass through to form the nerve-fiber layer of the retina. The ophthalmic artery and vein pierce the nerve obliquely about 18 mm. posterior to the lamina cribrosa, and are continued forward in the center of the nerve, passing through the *porus opticus* to be distributed to the retina.

INFLAMMATION OF THE OPTIC NERVE.

Synonyms.—Choked disc, optic neuritis, papillitis, neuroretinitis. **Choked disc** is so called on account of the interference of return of blood through retinal veins, by pressure from swelling at this point. **Papillitis** generally describes an inflammation limited to the intraocular head of the optic nerve, although in all probability, in the majority of cases, the nerve is affected throughout its entire length. There is less swelling than in choked disc, the visual disturbance appears earlier, and the disease leads to atrophy and blindness more frequently than does choked disc. **Neuroretinitis** and **papilloretinitis** are terms used to describe an inflammation which involves the retina as well as the optic nerve. It is characterized by hemorrhages, patches of fatty degeneration that appear as white spots, deposition of pigment, etc., similar to the changes in albuminuric retinitis.

Causes.—The condition often called choked disc may be due to traumatism, but is usually the result of a brain tumor, and is almost invariably bilateral. Tumors of the cerebellum and those at the base of the brain pressing upon the sinuses are most likely to be followed by choked disc. Some form of optic neuritis is said to accompany ninety per cent. of all cases of brain tumor. If unilateral, the disease is probably caused by a tumor in the orbit. Other intracranial diseases causing inflammation of the optic nerve are: tubercular basilar meningitis of children, epidemic cerebrospinal meningitis—in fact, meningitis from other infectious diseases or from any suppurative origin. Infectious diseases, syphilis, lead poisoning, and other systemic affections may directly cause optic neuritis. Tumors or diseases of the orbit may have the same effect. Traumatism and inflammation of surrounding tissues are also causes.

Pathologic Anatomy.—Cerebral tumors interfere with the circulation and distribution of subarachnoid fluid in the lymph-spaces. The sheath of the optic nerve becomes much swollen and pyriform.

It is supposed that the bacilli of the causative meningitis act directly upon the nerve-head.

The line of distinction between retinitis and neuroretinitis is so slight that we can probably associate closely the causes of the former with those of the latter; however, in albuminuric neuroretinitis, the greatest changes are in the retina rather than in the nerve-head, and the urinary tests are quite indicative. Cases of inflammation of the optic nerve in which the cause is unknown are sometimes seen. Occasionally, several members of a family, the males particularly, and of apparently healthy parents, are attacked between the eighteenth and twenty-fourth years by a bilateral optic neuritis. In other cases, "catching cold," suppression of the menses, lactation, etc., are given as causes. In such cases there must be a suspicion that there was latent inflammation which became prominent under the conditions mentioned, and was not directly due to them.

Symptoms and Diagnosis.—The systemic condition is often simultaneously affected. The principal ocular symptom is impairment of vision, gradually passing into total blindness. In the early stages of choked disc vision is not markedly impaired. Particularly typical are *diminution of central visual acuity, unsymmetric contraction of the visual field, and impaired color-sense.* The ophthalmoscopic appearance of choked disc is a swelling and opacity in the disc and its immediate neighborhood (Fig. 97). That the papilla is larger than normal and projects into the vitreous may be proved by the *parallax* test. The papilla, while undergoing inflammation, has what has been called a *woolly* appearance, together with swelling and congestion. The small vessels of the disc are dilated, so that many of them are visible, unless masked by excessive edema. There may be numerous capillary hemorrhages in the nerve-head. The retinal arteries are diminished in size, and veins are swollen and tortuous. The edges of the disc are lost, and a striated flame-like or grayish haziness spreads over the disc into the adjoining retina, nearly equal on all sides. In severe forms there are diffuse retinal hemorrhages and perhaps macular changes resembling albuminuric retinitis.

In addition to the presence of choked disc, the discovery of hemianopsia and use of Wernicke's sign will aid in the diagnosis of cerebral growth.

In the *interstitial* or *descending neuritis* the disc is not swollen as in choked disc; it is dull and edematous looking. Vision is usually

more and sooner affected, owing to the greater length of nerve structure involved.

Prognosis.—The course is usually chronic, finally ending in optic nerve atrophy. Naturally, the prognosis is affected by the cause. Cerebral tumors are usually fatal in a short time. The various forms of meningitis are always serious. Restoration of vision is doubtful; there is little hope of regaining lost visual power. However, cures with restoration of normal visual acuity, and cures of amblyopia of every degree, have been reported.

Treatment is naturally directed to the cause. If the cerebral tumor

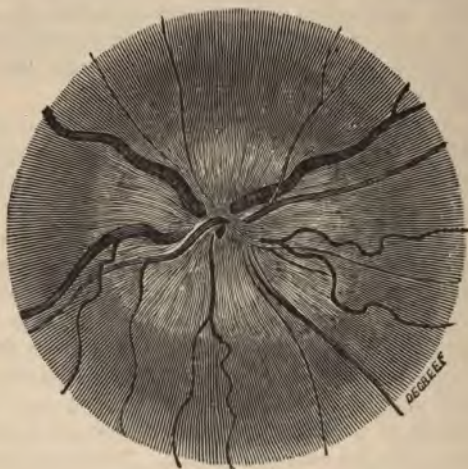

FIG. 97.—OPTIC NEURITIS.

can be located, surgical interference may be of value. A syphilitic gumma will yield to mercury and potassium iodid. If no cause is discernible, diaphoresis, the mercurials and iodids, and tonics may be tried. Blood-letting from the temporal region has been reported of value. Possibly mild cases recover spontaneously. If there is reason to suspect that the neuritis is orbital in origin, systemic treatment will prove of little value; and in well-defined malignant orbital disease immediate enucleation is imperative.

RETROBULBAR OPTIC NEURITIS.

Definition.—Inflammation of the optic nerve beyond the eyeball, in which the disc is not involved at first, papillitis arising in the advanced stage.

Causes.—Acute retrobulbar neuritis is caused by exposure to cold, acute infectious diseases, sudden cessation of the menses, and any condition which leads to a sudden exudation into the sheath of the optic nerve. The most common cause of the chronic form is excessive use of tobacco and alcohol; although lead-poisoning, syphilis, quinin, and other toxic agents may produce it. As a rule, both tobacco and alcohol are simultaneously used to excess, and act conjointly. The disease is often called *tobacco* or *alcohol amblyopia*, or *toxic* or *intoxication amblyopia*, although many authors distinguish between intoxication amblyopia and retrobulbar neuritis from other causes. It has recently been suggested that the central amblyopia is due to primary rather than to secondary macular disease—that is, that the disease starts in the macula and ascends the central fibers of the optic nerve.

Symptoms.—In the acute disease, total blindness results in a few days, and there is often pain in the eye, increased by movement or pressure. The ophthalmoscope reveals a papillitis of moderate severity. In the more common chronic disease, the chief symptom is slowly diminishing central vision. The patient complains that he sees indistinctly, especially in bright light, and his vision improves at sundown. This is explained by the dilatation of the pupil as daylight fades, and consequent stimulation of the unaffected perimacular region by the increased illumination. Examination with the perimeter shows a central scotoma, at first for color, and finally for light. At the onset, the field of vision remains nearly normal, and only begins to be obliterated when fixation becomes impossible, and nystagmus results. With the ophthalmoscope there is first seen slight hyperemia of the disc, and later a grayish-white discoloration of the temporal halves of the papillas. The outlines are obscured, the veins are enlarged, and the arteries diminished in size.

Prognosis may be considered favorable if the disease has not progressed to atrophy, and if the patient can be made to stop drinking and smoking; but relapses are likely to occur whenever the abstinence is suspended.

Treatment.—In the acute form, general blood-letting, active diaphoresis, and other antiphlogistic measures are indicated. In chronic cases, abstinence from tobacco and alcohol must be enforced, and strychnin administered in increasing doses. If syphilitic, the disease yields to the mercurials and iodids. Any other discoverable cause should be treated according to the indications.

ATROPHY OF THE OPTIC NERVE.

Causes.—The vast majority of cases are postneuritic—that is, following some inflammation of the optic nerve. Most cases are due to some disease of the brain or spinal cord, especially of syphilitic

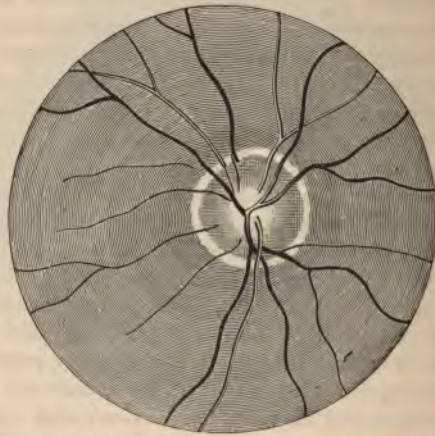


FIG. 98.—OPTIC ATROPHY WITH EXCAVATION OF DISC.

origin. Of the cerebral diseases might be mentioned disseminated sclerosis, progressive paralysis, and general paralysis; of the diseases of the spinal cord, locomotor ataxia is a prominent cause. Mechanical pressure from tumors, traumatism, embolus in the central artery, cutting off the blood-supply, and the toxic agents, causing retrobulbar neuritis, lead to optic atrophy. Blindness, or amblyopia following severe hemorrhages, is supposed to be due to atrophy of the optic nerve. *Sexual abuse, catching cold, physical and mental excesses, have all been set down as causes.*

Symptoms and Diagnosis.—The patient notices an early disturbance of vision, consisting of diminution in the central acuity, concentric contraction of the visual field, both for white and colors, and irregular scotomas. There is no pain, and seldom photophobia. Of the colors, green is first lost, and blue last; light-sense is longest retained. The ophthalmoscopic appearances vary with the cause. If the atrophy is subsequent to papillitis, the disc is increased in size, and there is more or less obliteration of its outline and distention of the veins. In simple atrophy, instead of the rosy healthy hue of the normal disc, the papilla may be grayish-blue, or quite white. The outlines have a striking sharpness, which gives the shining disc its characteristic appearance (Fig. 98). The disc appears sunken and excavated, and allows the network of the lamina cribrosa to be seen through the spaces left open by the disappearance of the nerve-fibers. The vessels diminish in size, and the capillaries of the papilla are no longer visible.

Prognosis is serious. The probability of retaining the vision yet left is small, and the result is usually total blindness.

Treatment should be directed to the cause; constant, increasing doses of strychnin should be given, orally or hypodermically, and the continuous electric current should be applied until it is found to be of no avail. Good results have recently been reported from the combined use of mercuric chlorid and nitroglycerin.

DISEASES OF THE LENS.

Anatomy.—The crystalline lens consists of a biconvex, transparent body inclosed in an equally transparent homogeneous capsule. It varies from eight to ten mm. in diameter, and is from three to four mm. thick from pole to pole. Its posterior surface rests against the vitreous, and its anterior surface against the posterior surface of the iris. The capsule is thickest at the anterior pole (0.016 mm.). The lens is enveloped at its periphery by the suspensory ligament and behind by the hyaloid membrane. The substance of the lens is arranged in concentric layers, composed of minute fibrils somewhat hexagonal on horizontal section, which dove-tail into one another. The external layers are soft, the next firmer, and the central form a *hardened nucleus*. Between the layers and among the ⁶¹

oil-like material called the *liquor Morgagni*, which permits change of form of the lens without friction. The anterior capsule is a tough, elastic membrane, lined on its posterior surface by hexagonal cells whose function, it is said, is to nourish the lens proper.

The *zone of Zinn* is the *suspensory ligament of the lens*, and serves to retain the lens in place. It is a transparent, fibrous, perforated membrane, stretched between the ciliary processes and the lens. Between the folds of this ligament is the *canal of Petit*, encircling the equator and containing a fluid supposed to assist the nutrition of the lens.

CATARACT.

Definition.—A pathologic change in the lens or its capsule diminishing its transparency.

Causes.—Traumatic cataract, due to injury of the capsule or lens needs no explanation, as it is not supposed that the subsequent cicatricial tissue will be transparent. If the lens or capsule is not directly injured by trauma, but is dislocated or its surrounding media disturbed, it becomes opaque through altered nutrition, due to the suspension of the exchange of fluid between the lens-structure and the surrounding media. Any chemic alteration in the fluid constituents of the body in general may be participated in by the aqueous, vitreous, and suspensory ligament, and may endanger the lens, as, for instance, cataract due to diabetes. Inflammations of the uveal tract, myopia, retinitis pigmentosa, detachment of the retina, and glaucoma are causes of cataract. Rickets is an almost constant accompaniment of lamellar cataract. The gouty diathesis is mentioned as a predisposing cause. Heredity is sometimes an etiologic factor. Glass-blowers and other workers in great heat and glare are particularly susceptible to cataract. Certain toxic agents, such as naphthalin and ergot, may cause cataract. There is no satisfactory explanation of senile cataract. Old age predisposes to cataract, but whether by weakened nutrition, sclerosis, atheroma of the arteries, or the undue strain on the accommodation in presbyopia, we are unable to say. It has been suggested that as the lens grows by proliferation of the epithelial cells lining the anterior capsule, these cells become more compressed and harder at the nucleus, the oldest part of the lens, and when the normal increase of the nucleus at the expense of the cortical substance ceases, the first step is taken toward cataract.

formation. It is the opinion of the authors that the disturbances in nutrition, directly and indirectly brought about by prolonged eye-strain due to uncorrected ametropia, are not only possible, but general causes of cataract.

Varieties and Nomenclature.—Opacities in the capsule are called **capsular cataract**; opacities in the lens-substance are called **lenticular cataract**, and may be **cortical** or **nuclear**, or, if both cortex and nucleus are involved, we speak of **complete cataract**. **Complicated cataract** is one in connection with other eye-diseases. If the diseased lens is adherent to any of the neighboring structures, the condition is known as **cataracta accreta**. A **polar cataract** is a cataract confined to one pole of the lens. In **pyramidal cataract** the opacity is at the anterior pole, and is conoid, the apex extending forward. **Recurrent capsular** or **secondary cataract** is a cataract of the capsule appearing after extraction of the lens. **Diabetic cataract** is associated with diabetes. Probably the most convenient division of cataract is into **senile**, **juvenile**, **traumatic**, and **stationary**, and this classification with its subdivisions will be used later. An important distinction of cataracts refers to their maturity or ripeness, whence they are classed as **ripe**, **unripe**, and **overripe** (Morgagnian).

Symptoms and Diagnosis.—Cataract does not cause pain. The symptoms are disturbance of vision and reduction of visual acuity, which vary according to the kind of cataract and its stage of maturity. Opacities on the pole or on the axis between the two poles may escape the patient's notice, if they are small, dense, and sharply defined; whereas, opacities including the entire pupillary area cause great disturbance of vision. Opacities at the periphery, when covered by the iris, as a rule produce no obstruction to sight; but when the pupil is sufficiently dilated, as in a dim light, these opacities become evident, hence such patients see better in a bright light with a contracted pupil. Patients with an opacity in the pupillary area with the periphery remaining clear see better with a dilated pupil—*e. g.*, under a mydriatic or in a dim light. Even a completely opaque lens does not destroy vision. If the retina and opaque nerve are healthy, the patient should be able to tell the direction from which light is projected, and should recognize an ordinary candle-flame in a dark room at six meters. With normal light-perception, a pupil of a cataract eye should contract distinctly if light is suddenly thrown

Objective Examination.—If the anterior polar region

pupil appears grayish-white instead of normal black. It must not be supposed that every grayish discoloration of the pupil is caused by cataract; indeed, in old persons some diffused light is always reflected from even a transparent lens, giving the pupil a grayish color. The general plan in the diagnosis of cataract is to use both oblique illumination and the ophthalmoscopic mirror. With the first, opacities appear grayish against a black background, and with the second, black against a red background (Figs. 99 and 100). If the cataract is almost complete, the whole pupillary area is grayish under oblique or direct illumination and black under the transmitted light of the

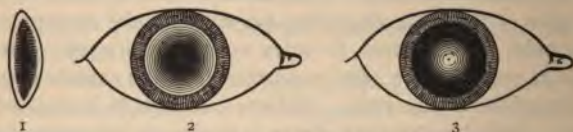


FIG. 99.—NUCLEAR CATARACT.

1. Section of lens; central position of opacity.
2. Appearance by ophthalmoscope.
3. Appearance by oblique illumination.

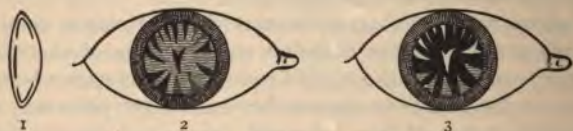


FIG. 100.—CORTICAL CATARACT.

1. Section of lens; opacities beneath the capsule.
2. Opacities as seen by the ophthalmoscope.
3. Opacities as seen by oblique illumination.

ophthalmoscopic mirror. When a distinct area in the lens appears *gray or white by focal illumination* and *black to light thrown through it by the ophthalmoscope*, we are justified in assuming an opacity. The entire lens can be examined only by complete dilatation of the pupil, and even then the peripheral edges may be hidden.

Cataract is most common in old persons, next in infants, and rarest in middle age.

SENILE CATARACT develops usually between the fiftieth and seventieth year, and may be cortical, nuclear, or mixed in origin. It generally shows a hard, unclouded, and transparent nucleus, and a soft,

clouded cortex. One eye is generally affected at a time. Early symptoms are multiple vision in one eye, caused by opaque sectors in the cortex of the lens, and shortsightedness due to a change in the refractive index or expansion of the lens. Incipient cataract causes the presbyope annoyance; he complains that his glasses do not fit, and that dark shadows are seen before his eyes. As the opacities increase, the visual acuity diminishes, and the lens swells from absorption of water in the cortex, causing the anterior chamber to become shallower. After a longer or shorter time the cortex becomes opaque, the swelling disappears, and the anterior chamber is again of normal depth. By this time the visual acuity is reduced to counting fingers and perception of a candle across the room. The cataract is now considered *mature*, or *ripe*.

The test for maturity of a cataract is what is known as the *iris-shadow*. By throwing a strong light obliquely into the pupil, the margin of the pupil is made to throw a shadow upon the opacity. If the lens is completely opaque, the white light reflected from it and the dark brown of the pupillary margin of the iris lie immediately against each other; if, on the contrary, the external cortical layer of the lens is still clear, there will be seen, between the white shadow of the opaque pupillary portion of the lens and the pigmented edge of the iris, a dark ring, which will be wider the less the lens is opaque. The treatment for mature senile cataract is extraction.

An *overripe* cataract becomes smaller and more dense, due either to a diminution in the aqueous constituents, or to the cortex becoming a yellowish, mushy mass of fluid, with a brown nucleus floating in it. This latter condition is known as the **Morgagnian cataract**, and causes the greatest disturbance of vision and difficulty of extraction.

JUVENILE CATARACT may be congenital in all stages of its growth. As the nucleus is not yet hard, it participates in the general cataractous change in the lens. Any part of the lens, even the nucleus, may be strewn with punctate opacities. Juvenile cataracts become atrophied, liquefied, or calcified. In the atrophic soft cataract there is found within the capsule a mushy degenerative mass; and in the fluid cataract the same constituents are found floating in the liquid. In calcified cataract the whole lens is changed to a lumpy mass, looking like *gypsum*. In some cases the contents of a soft cataract may be absorbed, leaving only the membranous or capsular cataract. The

age of the patient, the bluish-white color, and general appearance indicate a soft cataract.

STATIONARY CATARACT includes any condition in which there is a fixed and permanent opacity throughout life, showing no gradual progression as in the foregoing varieties. There are several kinds of cataract that are stationary, and they will be considered separately.

Zonular or Lamellar Cataract.—This is the most common form of stationary cataract. It appears nearly always in both eyes, and may be congenital, or may be developed during the early years of life, not being noticed until the child is sent to school. It appears as a delicate, gray, homogeneous opacity, restricted to a zone lying between the nucleus and the cortex, and is supposed to be produced by a temporary interruption of nutrition during formation of the lens. If light is thrown by the ophthalmoscope directly into the pupil, a dark, circular opacity, brownish-red in the middle, is seen. The cortex is not always clear, but may contain dots and spokes and what are known as *saddle opacities*. Unless the pupil be dilated, the cataractous shell may not be discovered, and the patient be considered a myope. Discission is almost always the operative measure employed in this condition.

Posterior polar cataract is characterized by a white, glistening, round opacity, situated on the posterior pole of the lens or its capsule, and is supposed to be the result of some disease of the fetal hyaloid artery. It is usually complicated with disease of the retina or choroid. An artificial pupil may produce relief in these cases, but, failing in this, discission is the final step.

Pyramidal cataract (anterior capsular or polar cataract) is rarely congenital, but is acquired in childhood after a perforating ulcer of the cornea and escape of the vitreous, which allows the lens to come in contact with the inflamed cornea. After the aqueous reforms, the lens recedes, leaving a small, roundish, glittering opacity protruding into the anterior chamber like the apex of a cone. Contrary to the general idea, the opaque mass is inside the capsule, which is uninjured, save for the absence of its epithelium.

Congenital nuclear or central cataract is recognized by a white, circular, and sharply outlined opacity in the center of the pupil. Vision may be good, as the patient looks through the side of the opaque nucleus.

TRAUMATIC CATARACT results from a rupture of the capsule by a contusion of the eyeball, by penetration from a foreign body, or from injury to the lens itself. The lens-fibers coming in contact with the aqueous become cloudy and swollen, and if the wound is of any extent, as is usually the case, the entire lens participates in the morbid process. The contents of the capsule gradually protrude into the anterior chamber and are absorbed. Iritis is a frequent accompaniment, and if there is much swelling of the lens, glaucoma may be produced. The younger the patient, the quicker the absorption and the less inclination to increased tension. The slightest touch in an operation may give rise to a traumatic cataract, and in elderly persons a small aseptic foreign body may cause cataract so slowly that the patient forgets about the injury long before there is marked visual disturbance. The treatment in young subjects is to wait for absorption, while in elderly persons extraction is indicated after the subsidence of inflammatory signs. Marked increase of intraocular tension calls for early iridectomy and extraction. The general procedures for associate traumatic and inflammatory conditions—such as cold, leeching, antiseptic douching, and atropin—are necessary.

TREATMENT OF CATARACT.

General Remarks.—The treatment of unripe cataract must be the use of proper reading glasses, protecting the eyes from irritation of any kind, and the maintenance of the general health of the patient. In considering what cataracts may be operated on, we must first determine whether any retinal, choroidal, or nerve-disease coexists, which may be discovered by examining the light-sensation or field of vision.

Stationary cataract, in which the visual acuity is sufficient for the patient's occupation, or in which an artificial pupil will suffice, should not be operated on. If one eye is unaffected and healthy, it is not advisable to operate, for, even under the most successful conditions, we can not expect perfect binocular vision, on account of the great optic disparity between the eyes.

Ripe and overripe cataracts are best treated by operation. Unripe cataracts should be waited for, or, if absolutely necessary, should be artificially ripened by intracapsular irrigation (McKeown), or by Förster's method, which consists in performing an iridectomy or a

paracentesis of the cornea, allowing the escape of aqueous, and irritating the lens by massaging the cornea against it with a strabismus hook or spatula and extracting after reaction has ceased. Bettmann's method consists in "direct trituration" of the lens with a spatula introduced into the anterior chamber after iridectomy. All these operations are attended with more or less danger. In fact, many operators believe it is safer to extract an unripe cataract than to resort to artificial ripening.

The health of the patient and the state of the eye should be considered before proceeding with any operation. General debility and any inflammatory disease of the eye or appendages are contraindications.

Preparation for Operations.—A gentle purgative should be given the day before the operation. The head should be washed with soap and hot water, and an antiseptic bandage placed over the eye to be operated on. This bandage is removed at the operation, the head enveloped in a cloth wet with sublimate solution, the vicinity of the eye thoroughly scrubbed with a strong sublimate solution, and the eye doused with a mild antiseptic solution. Anesthesia is produced by instilling several drops of a four per cent. solution of cocain in the eye five times, at intervals of two or three minutes. All instruments, sponges, and dressings used should be thoroughly sterilized before the operation.

Choice of Operation.—*Discission* is applicable to the soft cataracts and lamellar cataracts in childhood. The reaction and increase of tension in adult eyes after discission is so great as to be dangerous, although discission has been successfully used before extraction of the lenses of highly myopic eyes. However, in this case an early iridectomy and extraction is performed.

Extraction without iridectomy is a beautiful operation, and often gives ideal results. Many reliable operators advise it, but it should never be performed by a novice; only by an expert upon selected and trained patients. The tendency to prolapse of the iris and secondary capsular cataract is greater than in the combined operation.

Extraction with iridectomy is the safest of all cataract extractions. It is absolutely demanded in complicated or difficult cases. The so-called "mutilation" of the iris is slight, and the cosmetic disadvantage is hardly noticeable, and is much more than offset by the safety

and good results. Prolapse of the iris is infrequent. With careful irrigation of the anterior chamber, the chances of secondary cataract are greatly reduced.

Discission is the operation most used in lamellar cataract and in all soft cataracts without hard nuclei. The necessary instruments are

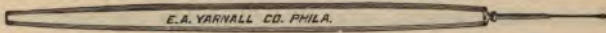


FIG. 101.—NEEDLE FOR SOFT CATARACT.

a lid-speculum, fixation forceps, and a discission-knife needle (Fig. 101), or Bowman's stop needle. The pupil should be dilated to the utmost. The needle is entered perpendicularly to the under and outer side of the center of the cornea (Fig. 102). The capsule is pierced near its anterior pole, and is divided up and down by a vertical sweep of the handle, taking care not to penetrate deeply into the lens. If neces-

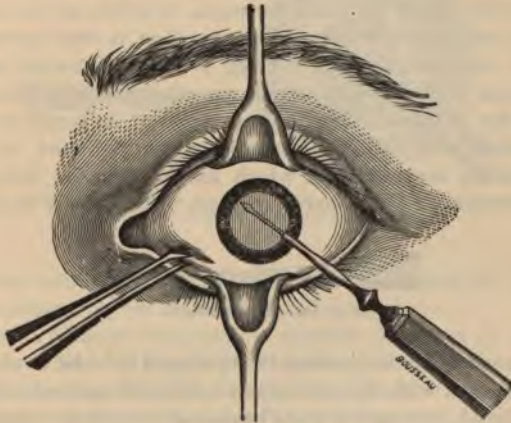


FIG. 102.—DISCISSION.

sary, the vertical incision in the capsule may be enlarged transversely; the needle is then withdrawn in the same direction as it was entered, avoiding, as much as possible, escape of the aqueous. While the lens is undergoing absorption, the pupil must be kept dilated with atropin. If the swelling is too intense and iritis ensues, the swollen

mass should be let out by simple linear extraction. If absorption is obstructed, simple release of the aqueous by paracentesis and repeated dissections are necessary. Inflammatory symptoms are met in the usual way.

Extraction with Iridectomy.—The lids are fixed by a lid-speculum or by the fingers of an assistant, and the conjunctiva is firmly held with fixation forceps, at a point centrally below the margin of the cornea. A Graefe knife (Fig. 103) is entered at the corneal margin, just above its horizontal diameter, and is passed through the anterior chamber in front of the pupil, making counterpuncture at a



FIG. 103.—VON GRAEFE'S CATARACT KNIFE.

point exactly opposite. With the cutting-edge upward, the knife is gently moved to and fro, until the upper two-fifths of the cornea is opened at the scleral border. The operation is then momentarily suspended, and the patient is directed to look downward and keep the eye quiet while iris-forceps are introduced closed through the center of the incision. The iris is grasped at its pupillary border, slowly withdrawn, and the portion to be removed is excised by iris-scissors, the blades of which are held in the plane of the vertical meridian. The anterior capsule of the lens is then opened




FIG. 104.—CYSTOTOME.

by a cystotome (Fig. 104), which is introduced into the wound to the edge of the iris, with its cutting-point directed upward; it is then partly revolved, turning the point backward toward the capsule, over which it is drawn in a horizontal and vertical direction, or around the circumference of the pupil; another quarter revolution of the handle is made, and the instrument is withdrawn with its point downward.

The delivery of the lens is then effected by gentle pressure and massage with a lens-spoon until it is extruded through the corneal incision (Fig. 105). Counterpressure may be made with one spoon on the inferior portion of the cornea, while another spoon presses on

the sclera above the incision. The anterior chamber is freed from blood, and the remaining cortical fragments are expelled by stroking the cornea with a spoon or by the gentle injection of sterilized water or a weak antiseptic solution. Care must be taken that the iris is not engaged in the wound, and if it can not be successfully pushed back into the anterior chamber, it should be excised.

If the vitreous presents at the corneal wound before the lens is delivered, the speculum must be withdrawn, and the lens removed by means of a wire loop, a spoon, or a special lens-extractor. In cases in which, for any reason, prolapse of the vitreous is anticipated, the Kalt suture is sometimes employed. A fine suture is introduced into the substance of the cornea, not penetrating it, below the line of expected section, and brought out and carried over into the tissues

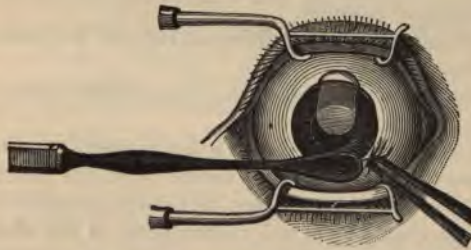


FIG. 105.—EXTRACTION OF THE LENS.

beyond the limbus. After extraction, this suture may be tightened. The Kalt suture has not found general favor.

Extraction without iridectomy is suitable for cases in which the operator is skilled by long experience, and in which a smooth and complete delivery of the lens may be anticipated in a healthy, calm, and intelligent patient. A Graefe knife is introduced near the horizontal diameter of the cornea at its junction with the sclera, and a flap made by transfixation as before, including about five-twelfths of the corneoscleral margin. The capsule is divided as in the preceding operation, or rather more extensively if a Knapp knife, especially designed for this purpose, is used. The lens is expelled by slow, steady, continuous pressure with a spoon on the lower part of the cornea. The rest of the operation and the complications are treated

as in extraction with iridectomy. Eserin (gr. j to $\frac{3}{4}$ j) is dropped into the eye and the eye bandaged.

Accidents During Extraction.—The *corneal section* may be made too small. In such case it should be enlarged by a knife or scissors. *Hemorrhage into the anterior chamber* may interfere with the operation. Irrigation and massage of cornea with a scoop will dispel the blood. *Prolapse of the vitreous* before delivery of the lens is a serious accident, as the lens falls back into the vitreous chamber, and may be lost unless immediately extracted by a loop, scoop, or other similar instrument. Loss of vitreous after extraction is not serious, but is an indication for immediate suspension of further manipulation.

Complications in the Process of Healing.—*Pain* may be severe, and continued beyond three or four hours. It should be met with hypodermic injections of morphia.

The *anterior chamber* is sometimes not restored for a week or more. This need cause no alarm.

Corneal opacities usually soon pass away, unless caused by strong mercuric chlorid solutions.

Suppuration of the wound is rare when antiseptic precautions are used. Its onset is made known by severe continued pain and by pus in the eye. It usually occurs between the twelfth and thirty-sixth hours. It should be combated by actual cauterization of the whole corneal wound and mercuric chlorid irrigations. It is a very serious complication.

Iritis is due to traumatism during the operation, irritation from remaining cortical substance, and rarely infection. It does not appear for several days after the operation, and is ushered in by pain and the objective symptoms of plastic iritis. It is treated by atropin, hot compresses, leeching, and salicylate of soda or the iodids internally. The disastrous results are generally due to organized exudate in the pupil, obscuring vision.

Cystoid cicatrix is usually seen at the extremities of the corneal section. It does not appear for several weeks after the operation. If the iris capsule is included in the cicatrix, the eye is exposed to the danger of sudden attacks of iridocyclitis or iridochoroiditis.

Extraction of the lens in an unruptured capsule is an ideal operation, but is only applicable when the capsule is tough and the suspensory ligament weak, or when there is a fluid between the vitreous and

lens. Instead of lacerating the capsule with a cystotome, a spoon is passed behind the upper edge of the lens, and gentle pressure is exerted on the lower third of the cornea. If the lens is not expelled, the spoon is passed still deeper behind to the posterior pole, and the lens slipped out by pressing it lightly against the inner surface of the cornea.

Descriptions of other operations for the extraction of cataract are considered unnecessary in a work of this nature. Suction is only applicable to fluid cataracts without a nucleus, and is not recommended. Suction by the mouth is a forbidden procedure in these days of asepsis and antisepsis.

After-treatment consists in removing all shreds from the corneal wound, cleansing the eye, and after simple extraction instilling a drop of eserine to prevent prolapse of the iris. If there is much cortical substance still in the wound, it may be removed by gentle massage of the cornea, or by careful irrigation of the anterior chamber with a special syringe. Lippincott has devised a most convenient apparatus for this purpose. The eyelids are closed with adhesive strips. A light absorbent bandage, consisting of a little absorbent cotton and thin material, like tarlatan, is applied over both eyes, not to exert pressure, but simply to keep the eyes closed, at rest, and moderately warm. The dressings may be protected by a pasteboard shield. The patient is kept quiet in bed, and, unless there are active signs of infection, the bandage is not opened until about forty-eight hours after the operation. If there are no signs of inflammation then, the eye is cleansed twice daily, and at the end of a week the bandages may be omitted altogether, and dark glasses should be worn to protect the eye from strong light. After removing the bandage, atropine may be instilled daily, to keep the ciliary muscle and iris completely at rest. Strong convex lenses may be ordered after several weeks, and the patient allowed to begin the use of the eyes. Under ordinary circumstances the correcting lens for distance is about + S. 10, and about + S. 13 or 14 for reading. Some astigmatism is usually present, and should be corrected; this, however, gradually diminishes, and a reexamination of the refraction is soon necessary. Any inflammation secondary to cataract operations should be treated on the general principles heretofore discussed.

sule of the lens, with or without any remaining lens-substance, cataract-debris, or inflammatory exudate. The treatment of an opaque capsule in a pupillary space consists of discission by a needle or a Graefe's knife (capsulotomy), or, if the capsule is tough, by dilaceration with two needles (Fig. 106). Care should be taken not to exert too much pressure and dragging on the ciliary body. Some operators divide the capsule with a pair of fine scissors-forceps, and others extract the capsule through an opening in the cornea near the scleral margin (capsulectomy). Small hooks are also used for tearing

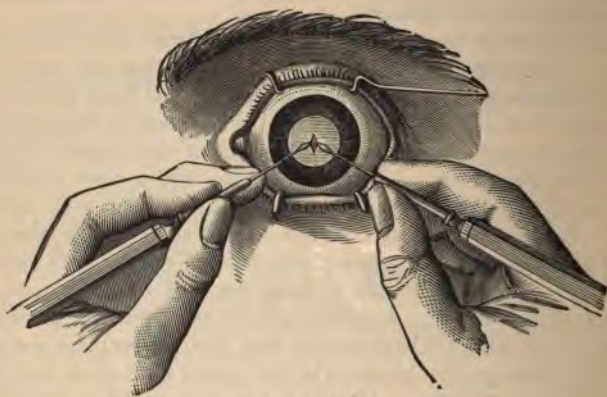


FIG. 105.—CAPSULAR DILACERATION.

an opening in an opaque capsule, or drawing it out of the corneal wound.

INJURIES TO THE LENS causing opacity are seldom limited to this locality, but generally involve the adjacent tissues. Simple cases should be treated like cases of discission, and may subsequently require an appropriate operation. The younger the patient, the better the prognosis. The lens may be dislocated completely, in which form the suspensory ligament is torn through and the lens is crowded out of position, and may even escape through the conjunctival wound, or it may be simply subluxated. A lens displaced from its natural bed sooner or later becomes opaque. For further discussion on this subject the reader is referred to the section on Traumatic Cata-

ract. A foreign body in the lens causes cataract, and the cataractous lens should be removed before it becomes overripe, else the foreign body may be released and become lost in the vitreous chamber.

THE CONGENITAL ANOMALIES OF THE LENS.—Dislocation is generally associated with some congenital anomaly of the vitreous or choroid. In this form the lens may retain its transparency for many years, and can be seen to move with change of head, and is visible under transillumination. There is sometimes congenital coloboma of the lens, generally peripheral, corresponding to coloboma of the iris and choroid. **Aphakia**, or absence of the lens, is sometimes congenital, but exists, of course, in persons upon whom discission or extraction has been performed. It is diagnosed by the deep anterior chamber, the trembling iris, high degree of hyperopia, and the loss of accommodation. There is also the absence of the small inverted image of a candle held close to the eye. The treatment consists in prescribing correcting bifocal glasses for reading and distance.

DISEASES OF THE VITREOUS.

Anatomy and Physiology.—The *corpus vitreum* forms the principal bulk of the globe of the eye. It consists of 98.6 per cent. of water. The remainder is composed of transparent fibers extending in all directions. Between these fibers are the compartments in which the nearly pure water or *vitreous humor* is contained. The vitreous is pierced in an irregular sagittal direction by the *central canal* about two mm. in diameter. In the embryonic state the *hyaloid artery* traverses this canal, and sometimes persists after birth. The vitreous is contained in a delicate membrane called the *hyaloid membrane*.

HYALITIS, or inflammation of the vitreous, is not an independent disease, but is generally associated with inflammation of the uveal tract, particularly the ciliary body, which causes disturbances of nutrition. It is characterized by change in consistency and partial disorganization. Opacities are seen in the form of threads, clouds, or separate flocculi, which cause subjective visual disturbance, and, provided the media are sufficiently clear, are detected by the *ophthalmoscope*. The treatment is constitutional, and under all cir-

stances should be directed to the cause. It consists chiefly of mercurials and iodids, and leeches to the temple.

MUSCÆ VOLITANTES, OR MYIODESOPSIA—Microscopic vitreous opacities formed at the periphery are of normal occurrence, and are found floating in the vitreous and can be readily seen in one's own eye, particularly if the observer be myopic. In certain conditions of ametropia these opacities become numerous and annoying and assume different shapes, such as strings of beads, flakes, etc. They generally disappear when the ametropia is corrected. By many observers muscæ are considered intraocular evidence of waste-tissue accumulation, and diet, exercise, and eliminatives, such as sodium phosphate, are prescribed. Many patients complain of muscæ during attacks of "biliousness." As soon as opacities are rendered visible by the ophthalmoscope, they are termed *vitreous opacities* and are always the sign or sequence of disease of the choroid, ciliary body or retina, intraocular hemorrhage, etc. The treatment should be directed to the cause. Mild aperients, diaphoretics, the mercurials and iodids, etc., may be administered. The eye should be used as little as possible at night. Vitreous opacities only reduce visual acuity when they intercept the rays of light proceeding to the macular region.

SYNCHYSIS is a name given to fluidity of the vitreous. It is generally due to chronic inflammation of the choroid or the ciliary body, and in itself brings about no special disturbance. Fluidity of the vitreous is significant in cataract operation, as we may expect considerable loss of vitreous under such circumstances.

SYNCHYSIS SCINTILLANS is the name given to an accumulation of cholesterin, tyrosin, and other crystals dispersed in the vitreous, constituting an ophthalmoscopic picture which has been compared to a shower of sparks in fireworks. It may be dependent upon choroiditis. The disease appears in advanced age, without sign of choroidal disease. Treatment is useless, and the condition is a contraindication to operation.

PERSISTENT HYALOID ARTERY is a rare anomaly, and consists of a fine, fibrous cord with its anterior end either attached to the posterior surface of the lens or protruding from the fundus into the vitreous. It may easily be seen with the ophthalmoscope.

GLAUCOMA.

Definition.—Glaucoma is a disease in many respects not thoroughly understood, but characterized by the essential sign of increase of intraocular tension. However, every case of simple increase in intraocular tension is not glaucoma, and in some cases of *simple glaucoma* no increase of tension exists.

Causes.—The direct cause is increase of the contents within the eye; either from *hypersecretion*, due to disturbances of the nervous mechanism controlling secretion, or to *retention* of the intraocular fluids by obstruction or obliteration of the drainage-passages at the periphery of the anterior chamber. Conditions causing changes in the composition of the aqueous also interfere with filtration—as, for instance, serous iritis and cyclitis. There is so much discussion and difference of opinion among equally erudite oculists about the cause of glaucoma that an exposition of the numerous theories is not advisable in an elementary work.

Among the predisposing causes are mentioned old age (with normal diminution of the circumlenticular space), gout, rheumatism, nephritis, certain cardiac diseases—in fact, any condition leading to circulatory and vascular changes. The general tendency to waste-tissue accumulation—the so-called uric-acid diathesis—is a fundamental cause in these cases. It is the opinion of the authors that long-continued eye-strain, from uncorrected or improperly corrected ametropia, is a potent factor in the etiology of many cases of glaucoma.

Pathologic Changes.—If there is a rapid rise in tension, the lens is pressed forward, a fact proved by the shallowness of the anterior chamber, and the suspensory ligament is stretched beyond the power of the ciliary muscle to relax it, as is shown in the lessening in the range of accommodation. There are marked circulatory changes in the eye. Pulsation is noticed in the retinal arteries, and the retinal veins are tortuous and swollen from the increased pressure. As the *venæ vorticosæ* are also squeezed by the intraocular pressure, an excess of blood is discharged through the anterior ciliary veins, which, in consequence, become dilated and tortuous. The cornea becomes cloudy from pressure, and even the aqueous and vitreous participate in this change. From pressure on the ciliary nerves neuralgia is produced, and paralysis of the sphincter pupillæ

anesthesia of the cornea result. By increase in the vitreous the intraocular pressure is raised. The most important diagnostic change is the excavation or cupping of the disc and atrophy of the nerve-fibers (Fig. 107). The final result of intraocular tension is active inflammation and swelling of both the internal and external coats of the eye. Naturally, vision is very much reduced.

Subjective Symptoms.—The patient complains of dimness of vision, diminution of the visual field, and pain about the eye, the intensity of which varies with the acuteness of the attack and the inflammatory symptoms accompanying. The appearance of colored rings or halos about any source of light, so often noticed in glaucoma, is a phenomenon due to the corneal disturbance, and is not confined especially to glaucoma.

Objective Symptoms.—The tension of the affected eyeball is abnormally high. If the rise in tension has been abrupt, the cornea is hazy and less sensitive to the touch than usual. The pupil is sluggish and often widely dilated, and has a greenish hue; the anterior chamber is shallow. In the inflammatory form there is considerable superficial and deep pericorneal injection.

With the ophthalmoscope the most characteristic symptom is excavation or cupping of the optic disc (Fig. 108), which is to be distinguished from the physiologic cupping



FIG. 107.—VERTICAL SECTION OF GLAUCOMATOUS EXCAVATION.

in extending the whole surface of the disc, and in having abrupt or overhanging sides; and from atrophic excavation of the disc, by the depth and peculiar "broken-off" appearance at the edge of the disc, so that no continuity can be discovered between the arteries at the bottom of the cup and the vessels on the edges of the disc. Pulsation of the retinal arteries is noticed, particularly where the artery bends over the edge of the cup; it may be made more distinct by slight pressure on the eyeball. The degree of cupping may be estimated by the parallax test or by comparison of the refractions of the edge and bottom of the cup.

Diagnosis.—In inflammatory glaucoma, on hasty inspection, the disease may be confounded with keratitis, iritis, cyclitis, etc. In such cases it is well to discard the injection, and rely on the dilated pupil and shallow anterior chamber, the increase of tension, the visual disturbance, the peculiar ciliary neuralgia, and the characteristic cupping of the disc.

For the differential diagnosis between acute glaucoma and the

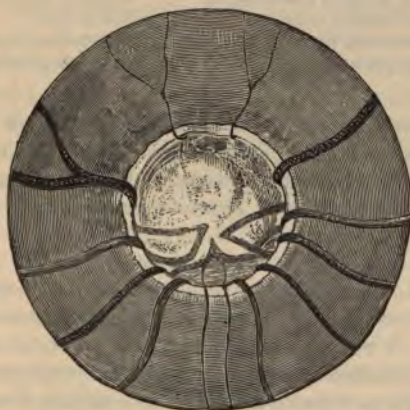

FIG. 108.—OPHTHALMOSCOPIC VIEW OF GLAUCOMATOUS EXCAVATION.

ordinary inflammatory conditions of the eye, the student is referred to the valuable table on pages 162 and 163.

In the noninflammatory types of glaucoma and optic atrophy the contrasted symptoms of the following table (Randall) are usually found; but it must not be forgotten that they may be wholly absent, or obscured if present.

TABULATION OF SYMPTOMS.

<i>Noninflammatory Glaucoma.</i>	<i>Optic Nerve Atrophy.</i>
Tension increased.	Normal.
Cornea hazy and anesthetic.	Normal.
Anterior chamber shallow or obliterated.	Normal.
Iris atrophic and discolored.	Normal.
Pupil dilated and sluggish or fixed.	Small or dilated (Robertson).
Reflex yellowish-green, "glaucomous."	Normal.

TABULATION OF SYMPTOMS.—(Continued.)

<i>Noninflammatory Glaucoma.</i>	<i>Optic Nerve Atrophy.</i>
Perforating vessels dilated and tortuous.	Normal.
Sometimes history of pain with obscurations.	Painless loss of vision.
Unilateral character usual at first.	Bilateral generally.
Limitation of field usually to nasal side.	Concentric limitation.
Color-fields commensurate to form-fields.	Disproportionate loss.
Rainbow vision about lights.	No halos.
Knee-jerks unaffected.	Often lowered or lost.
Optic disc cupped, margins overhanging.	Dished, margins shelving.
Halo of choroidal atrophy usual.	Halo rarer.
Nerve-tissue greenish in shadow.	Nerve bluish-gray.
Arteries and veins pulsating.	Arterial pulsation rare.

Glaucoma usually attacks persons past fifty, although even children may be affected. Ametropic eyes are most often affected. Both eyes are generally attacked, although the second eye may not be diseased until many years after. Prompt treatment and careful prophylactic measures are important factors in delaying or preventing a recurrence.

Varieties.—Acute inflammatory glaucoma is characterized by its abrupt onset, the signs of intense inflammation, marked pain, and dilated pupil. It may result in a few hours in total and incurable blindness, the condition known as *glaucoma fulminans*; or it may progress through successive attacks to a condition of stony hardness and total blindness called *glaucoma absolutum*; or the inflammation may not subside, leaving what is known as a **chronic inflammatory glaucoma**. The general rule is a gradual subsidence of the disease with a permanent increase in tension. **Simple glaucoma**, or **simple chronic glaucoma**, is free from inflammatory symptoms, and is of slow development. Often the cupping of the disc is the only sign; and when the media are opaque, the disease is easily overlooked, or mistaken for amblyopia, optic atrophy, retinitis, etc., and blindness results. The visual field contracts first on the nasal half. **Infantile glaucoma**, or **hydrophthalmos**, is a condition in which there is more or less uniform distention of the whole sclera as well as excavation of the nerve-head. The eyeball is unnaturally large, the tension is raised, the disc gradually excavated, the cornea hazy, but the anterior chamber is deep. **Malignant glaucoma** is a term applied to a sudden, and destructive outburst of the disease occurring sometimes shortly after the performance of an iridectomy.

Secondary glaucoma is due to an increase in tension from inflammatory changes about the iridic angle consequent upon diseases of the iris, lens, retina, choroid in high myopia, or intraocular tumors. **Hemorrhagic glaucoma** is dependent on hemorrhage from the internal ocular coats for the increased tension.

Prognosis.—Unless treated, glaucoma is almost certain to result, sooner or later, in complete and incurable blindness. It is of utmost importance to make an early and absolute diagnosis of this condition, especially in the simple variety, in order to prevent a fatal termination. Strange to say, glaucoma has been repeatedly mistaken for iritis, notwithstanding the dilatation of the pupil in the former disease and contraction in the latter; and to the great injury of the patient, atropin has been repeatedly instilled, soon aggravating the condition to blindness. Generally speaking, if promptly and properly treated, the prognosis of acute glaucoma is favorable; it is doubtful in simple and infantile glaucoma, and unfavorable in the other varieties.

Treatment consists in three methods: (1) **Miotics**, as eserine and pilocarpin, to contract the pupil. (2) **Operation** by paracentesis, iridectomy, sclerotomy, and incision of the ligamentum pectinatum. (3) **Massage**.

Miotics are the first resort, and often cut short single attacks of glaucoma, and they are also valuable before and after operation. Pilocarpin and eserine are commonly employed, and are long continued. **Paracentesis** relieves tension only for a short time. **Iridectomy** is of extreme value, and has some remarkable curative influence both in dissipating the increased tension and relieving the visual disturbances, and even eventually curing the process. It should be broad and done upward, for cosmetic reasons and to prevent subsequent dazzling. The earlier the iridectomy, the better the result. Restoration of vision can not be expected if there is much excavation and atrophy of the nerve-head.

Sclerotomy has been advocated in cases of simple glaucoma in which the visual disturbance depends on the changes of the optic nerve, and in infantile and hemorrhagic glaucoma. A Graefe's cataract knife is introduced into the anterior chamber at a point corresponding to the puncture in cataract extraction, but one mm. removed from the corneal margin. The counterpuncture is made at a point corresponding to this at the other side of the anterior chamber. With

a sawing motion of the knife, the section is enlarged upward until only a bridge of tissue, about three mm. broad above, remains undivided. The knife is then slowly withdrawn from the eye, care being taken that the aqueous humor is slowly evacuated through the lips of the wound. A drop of eserin is applied and the eye bandaged. Prolapse of the iris must be treated on general principles. Incision of the ligamentum pectinatum is performed by cutting through the filtration angle, or spaces of Fontana, with the point of the knife as it is withdrawn in sclerotomy. The good effects of sclerotomy have not been definitely established.

Massage of the eyeball, systematically pursued, at first by the physician and afterward by the patient, is of undoubted value. The result of massage is almost instantaneous; immediately the eyeball grows softer, but the effect is not lasting. However, five minutes' massage, exerting considerable pressure, practised several times daily, is an important aid in the treatment of glaucoma. Alternate firm palpations with two fingers upon the portions of the eyeball that can be reached by rotation of the eye to all sides, and through both lids, is perhaps a better method of effecting massage than by rubbing. Simple vaselin, a very weak yellow ointment, or a salve containing eserin and cocain, may be used in conjunction with massage.

The proper correcting lenses, both for distance and for near, should be applied in cases in which vision is still serviceable.

DISEASES OF THE ORBIT.

Anatomy.—The orbits are situated on each side of the central facial line, between the forehead and face. They are formed by the following bones: the frontal, ethmoid, sphenoid, lacrimal, superior maxillary, palate, and malar. The first three are common to both orbits (Fig. 109).

The general shape of the orbits is that of irregular, rounded, quadrangular pyramids, the apices extending inward and forming an angle at their imagined point of junction of about 40° . The average width of the orbit in adult males is 40.5 mm.; the height, 35 mm. The dimensions in the female are slightly smaller.

The orbit is in connection with the neighboring sinuses and the cranial cavity by nine foramens, fissures, and canals—viz., the optic,

the sphenoid, sphenomaxillary, supraorbital, infraorbital, anterior ethmoid, posterior ethmoid, malar, and lacrimal. The orbit is lined with periosteum and contains a cushion of fat, upon which rests the eyeball and its immediate appendages.

PERIOSTITIS is an inflammation of the periosteal lining of the orbit, particularly prevalent in scrofulous and syphilitic patients. The inflammation may be so extensive as to involve the frontal sinuses

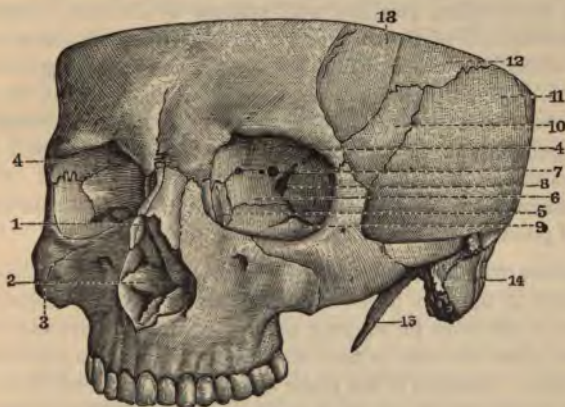


FIG. 109.—THE ORBITS.

1. Anterior orifice of nasal fossas. 2. Anterior extremity of inferior turbinated bone.
3. Malar bone. 4. Orbital cavity. 5. Lacrimal fossa, at base of which may be seen the line of union of the ascending process of the superior maxilla with the os unguis.
6. Os planum, forming with this bone the internal wall of the orbit.
7. Optic foramen. 8. Sphenoid fissure. 9. Sphenomaxillary fissure, continuous posteriorly with the preceding.
10. Upper portion of the great wing of the sphenoid. 11. Squamous portion of temporal. 12. Anteroinferior angle of parietal.
13. Part of frontal which contributes to form the temporal fossa. 14. Mastoid process. 15. Styloid process.

and produce necrosis of the underlying bones. A blow or a fall is usually the exciting cause. The symptoms are dull pain, swelling and edema of the skin surrounding the orbital edge, and, if necrosis has taken place, a fistula discharging foul pus and bony debris. Cicatrization of the fistula may lead to ectropion. The eyeball is rarely involved.

Treatment consists of leeches to the temple, cold compresses, and, if the patient is syphilitic, the administration of mercurials and iodid-

If the disease reaches a suppurative stage, antiseptic poultices, incision, and drainage are indicated.

ORBITAL CELLULITIS, or inflammation of the connective tissue of the orbit, is due to periostitis or to any suppurative or inflammatory process in the vicinity of the eye; even inflammations about the roots of the teeth may cause it. Erysipelas, anthrax, and pyemia may result in metastatic orbital abscess; and, finally, infection after injury to the orbit or its contents is a cause. The symptoms are pain, fever, general prostration, swelling and redness of the lids, edema and increased tension of the conjunctiva and lids, exophthalmos, fixation of the eyeball in a straight or deviating position, causing visual disturbance, and, after the pus escapes, a discharge from the orbit. In unfavorable cases panophthalmitis may ensue. Metastatic abscesses generally lead to death. Extension into the cranium is always to be feared.

Treatment consists in prompt incision, preferably at a spot showing signs of pointing, drainage, and antiseptic irrigation.

INJURIES TO THE ORBIT may cause fracture of the bony wall or laceration of the soft parts. Foreign bodies may be received and retained in the orbit for varying periods of time. They may escape into the nasal cavities or they may cause orbital inflammation, and even death. Luxation of the globe is generally produced by a wedge-shaped foreign body crowding between the eyeball and the orbit. Formerly, what was called "gouging" was resorted to by contestants in brutal fights, the object being to dislocate the eyeball from its socket with the point of the thumb. The danger is blindness from laceration or overstretching of the optic nerve.

Fracture of the orbit may be detected by palpation. If the neighboring sinuses are opened, there will be much emphysema about the lids, made worse by blowing the nose. There is late appearance (two or three days) of extravasation and ecchymosis of the lids. If the optic foramen is involved, there is, sooner or later, blindness from pressure or injury of the optic nerve. When fracture of the orbit produces enough hemorrhage to cause exophthalmos, the prognosis is bad.

Treatment.—After orbital injuries the affected parts should be *thoroughly disinfected*, and foreign bodies removed. The proximity of the brain to the orbit renders the prognosis doubtful in extensive

fractures or infected wounds. Rest and cooling compresses are indicated. In luxation, vision may be lost through stretching of the optic nerve, but may return after reposition of the eyeball and retention with a pressure-bandage. If the lids are closed tightly behind the globe, preventing replacement, the external canthus should be divided at once. The longer the eyeball is dislocated, the worse the effect upon vision.

TUMORS OF THE ORBIT cause exophthalmos in the direction of pressure. The other symptoms are disturbance of motility and vision and pain, all of which vary according to the size and malignancy of the tumor. The chief tumors are osteoma and encephalocele of the orbital wall; tumors of the optic nerve; and cysts, sarcomas, and vascular tumors, arising in the neighboring cellular tissue. A genuine orbital sarcoma is extremely rare, and carcinomas never originate in the orbit proper. All orbital tumors of any considerable size or malignancy should be removed after enucleation of the eye. There is little hope of treatment of encephalocele.

EXOPHTHALMOS is protrusion of one or both eyeballs. If one eyeball alone bulges forward, there is likely to be a local cause, such as abscess, injury, aneurysm, or other tumor, and it should be treated accordingly. Protrusion of both eyeballs is probably the result of some circulatory disturbance, such as exophthalmic goiter (Basedow's or Graves' disease); injury to the internal carotid within the cavernous sinus (pulsating exophthalmos); or of some condition causing thrombosis of the ophthalmic vein. In such cases local treatment is of no avail. In exophthalmic goiter the significant symptoms are exophthalmos; absence of the normal, simultaneous drooping of the upper eyelid as the eye is turned downward (von Graefe's sign); greatly increased rapidity of the heart's action; and tumefaction of the thyroid gland.

ENOPHTHALMOS is a term applied to retraction of the eye within the orbit. It depends upon the absorption of the orbital fat, decrease in the contents of the orbital vessels, or great loss of fluid from the body after intense purging. Traumatism involving the walls of the orbit may produce enophthalmos on the side affected. Senile enophthalmos is bilateral, and is due to the gradual absorption of orbital fat in old persons. The same condition results in emaciation after *fasting or disease*.

INJURIES TO THE EYEBALL.

PUNCTURED AND INCISED WOUNDS about the sclerocorneal margin are especially dangerous on account of involvement of the ciliary body; chronic cyclitis, and even sympathetic inflammation of the other eye, resulting. Wounds of the sclera are accompanied by prolapse of the choroid and retina and loss of vitreous. Detachment of the retina is a serious sequel. Injury to the lens or its capsule results in traumatic cataract. Corneal opacity is liable to follow a corneal wound, and the opacity will be greater if the iris prolapses.

One of the great sources of danger in penetrating wounds of the eyeball is the liability to infection, which is augmented by the impossibility of disinfection on account of the depth and narrowness of the traumatic canal.

Treatment consists in thorough disinfection of the eyeball and appendages with a 1:5000 mercuric chlorid solution, closure of the wound with a conjunctival suture, sprinkling with finely powdered iodoform or one of its substitutes, and an antiseptic bandage. Prolapse of the iris should be combated by restitution, abscission, atropin, or eserin. If the lens is injured, atropin and iced compresses are indicated and the ordinary treatment of traumatic cataract instituted. Injury of the lens through the pupil offers the best prognosis. In case the retina is completely prolapsed and much vitreous is lost, causing blindness, immediate enucleation may be necessary.

CONTUSED WOUNDS OF THE EYEBALL are the result of blows from the fists or a blunt instrument. "Black eye" usually results. There may occur hemorrhage into the anterior chamber, and sometimes when this clears up, vision is lost by a coincident retinal hemorrhage. The iris may be torn from its attachment (iridodialysis), or the lens may be dislocated. In severe cases the globe is ruptured at the weakest point in the sclera, opposite the point of impact, about two to five mm. from the cornea. In such case the vitreous escapes and the iris may be prolapsed in the rent. The ciliary body and the retina are very susceptible to serious injury. A curious result of rupture of the eyeball is seen in those cases in which, by an accidental blow, a cataractous lens has been removed and vision thereby restored. The prognosis of ruptured eyeball is always serious, and many injured eyes become atrophied.

Treatment consists in careful disinfection, the application of ice, eserine or atropine, a bandage, and rest in bed. A bruised iris must be carefully excised. The various complications should be treated as they arise. If there is an extensive rupture of the sclera, conjunctival and scleral sutures may be necessary to prevent complete prolapse of the vitreous. Nothing can be done for iridodialysis, except iridectomy. A dislocated lens must sooner or later be removed. Hemorrhage into the anterior chamber and subconjunctival hemorrhages will usually absorb without treatment.

FOREIGN BODIES IN THE EYEBALL.

It is always important after injury to the eyeball to determine whether or not a foreign body remains within the eye. If it can be seen by the naked eye, focal illumination, or the ophthalmoscope, the diagnosis is easy. In other cases in which the media become quickly opaque, or the body lies concealed in the sclerocorneal covering, or is near the ciliary body, it may escape detection. In these cases the patient's general and local condition and the nature of the injury must be carefully considered. If there is no point of exit, and there is absolute history of entrance of a foreign body, we must believe that it remains in the eye. The surest way of locating a foreign body is by the Röntgen rays.

Prognosis depends on the location of the foreign body, its chemical nature, and whether or not it was aseptic. Aseptic and chemically unirritating substances, however, have produced alarming inflammations in the ciliary region. Infection from a foreign body in the eye may result in panophthalmitis and speedy destruction of the globe. But there have been cases in which small aseptic foreign bodies have remained for years in different parts of the interior of the eye, even in the sensitive ciliary body. According to reliable statistics, the loss of the eye from foreign bodies in the anterior chamber is virtually nil; in the lens, thirty per cent.; and in the vitreous, seventy-one per cent.

It must be remembered that a foreign body remaining absolutely quiet within the eye is at all times dangerous, both to the affected eye and to its fellow.

Treatment.—Foreign bodies should always be removed from the anterior chamber. A lens with a foreign body in it must

later be extracted. If the foreign body is in the vitreous, the treatment depends on its nature. In such case, if the foreign body is of iron and can be located, it should be removed through a scleral incision by the electromagnet. Aseptic substances, such as copper, wood, stone, or glass, may be permitted to lie quiescent and be treated expectantly. At the first sign of inflammation they should be removed by a pair of fine forceps through a scleral incision. If the symptoms are indicative of much ciliary involvement, enucleation should be performed or active sympathetic inflammation may quickly set up and destroy the uninjured eye. Of all operations, removal of a foreign body from the eye should be performed under the strictest aseptic precautions.

A good rule in cases of foreign body in the eye seen soon after the accident is to secure the patient's assent to the application of the magnet, under anesthesia, and in case of failure of extraction, to submit to immediate enucleation. However, if there is evidence of intense ciliary inflammation in the injured eye or signs of sympathetic inflammation in its fellow, it is not safe to lose time in attempting extraction; the injured eye should be removed at once.

PARASITES IN THE EYE are usually the cysticercus, the larva of the tape-worm, which may also be found in any part of the body. Liebreich gives a good ophthalmoscopic image of a living cysticercus in the vitreous. Thread-worms have been found in an opaque lens and in the vitreous. It is possible that remnants of the persistent hyaloid artery have been mistaken for worms in the vitreous.

SYMPATHETIC OPHTHALMIA.

Definition.—An inflammation of the ciliary body, iris, or choroid, or a combination of any or all of these in one eye, due to injury in the other eye.

Cause.—The usual cause is an injury to the ciliary body, or incarceration of the ciliary body and iris in a scleral wound. A foreign body in one eye, causing cyclitis, is often followed by sympathetic inflammation in its fellow. The manner in which sympathetic inflammation is produced is not clearly understood. Mackenzie supposed that sympathetic inflammation passed from the retina of the injured eye, through the chiasm, to the retina of the other eye. Deutschmann

suggested that germs travel along the optic sheath through the chiasm into the sheath of the opposite nerve, and thence into the eye. Bacteriologic infection of the sympathetically affected eye can rarely be proved. A more recent nervous theory is that the path of irritation is from the first eye through the ciliary nerve to the ciliary ganglion, through the sympathetic root of the latter to the carotid plexus of the same side, then through the circle of Willis to the carotid plexus of the other side, and then in a centrifugal direction to the ciliary ganglion and the ciliary nerves of the second side. The time of outbreak of the secondary attack after the original lesion varies from four to eight weeks, but cases have been reported from two weeks to forty years afterward.

Symptoms and Diagnosis.—The premonitory symptoms are those of sympathetic irritation—asthenopia, photophobia, lacrimation, reduced accommodation, cloudy vision, and a mild pericorneal injection. The aqueous may be moderately opaque and the disc slightly reddened. As the stage of true sympathetic inflammation ensues, we notice signs of inflammation corresponding to exacerbations of inflammation in the exciting eye. The ciliary region becomes extremely tender; cyclitis, iritis, or some form of keratitis become visible. The pain and cloudiness increase, and the visual acuity steadily diminishes. Synechias may form, and the intraocular tension becomes at first increased, and afterward diminished, as atrophy begins. It is the rule, after varying improvement and relapse, to find an adherent iris, cataractous lens, or atrophied globe from deficiency in vitreous, causing retinal prolapses and incurable blindness, despite all treatment. However, it is possible to retain some indistinct vision in favorable cases, but the process is always prone to relapse, and the inevitable result follows.

Treatment is preventive, and must interrupt the nervous connection between the eye first involved and the one showing signs of sympathetic inflammation. It has been suggested that this be accomplished by cutting the ciliary nerves. Several different methods have been suggested, one of which is to cut completely through the optic nerve, expose the posterior pole of the eyeball, and cut the ciliary nerves entering at this location. Evisceration has also been proposed. The only certain method of prevention and cure is **enucleation of the eye first affected**. This is so important a subject that the concise rules laid down by Fick are given here as a guide:

(1) If the first eye is blind, painful, and sensitive to pressure, enucleation is to be advised; it is to be urged if the patient lives away from a surgeon, and thus may be in danger of overlooking the beginning of sympathetic inflammation. If the patient will not consent, he should be told to seek aid at the first sign of visual disturbance or of inflammation in the other eye.

(2) If the first eye has a foreign body in it, is painful and sensitive to pressure, enucleation should be urged even if the eye sees; it is to be supposed, of course, that the foreign body can not be removed independently.

(3) If sympathetic inflammation or even irritation appear in the second eye, the first must be enucleated at once. If the first eye is not blind, but still retains a certain visual acuity, and is to some extent quiet, both patient and surgeon will hesitate at such radical proceedings. There is, however, no general rule for such a case; we must carefully compare the visual acuity of the first eye with the degree of irritation in the second; the more there remains to rescue in the second eye, the greater price can be paid by the first.

If the sympathetic inflammation is fully developed, enucleation proves of little value, and we must lessen the pain by cocaine, atropin, warm compresses, and bandages, and confine the patient to bed. Mercurial inunctions and subconjunctival sublimate injections have been advised; salicylates, iodids, and mercurials may be given orally, but despite all treatment the eye is generally lost.

OPERATIONS INVOLVING THE ENTIRE EYEBALL.

EVIscERATION OF THE EYEBALL is performed as follows: The cornea is removed by making incision with a Graefe knife, so as to include one-half of the corneoscleral margin, and complete the circumcision with scissors. The contents of the globe are then evacuated by means of a special scoop, care being taken to remove the choroid unbroken, by carefully peeling it from the sclerotic, backward, until it is only fastened at the lamina cribrosa. The interior of the eyeball is washed out, and after all hemorrhage has ceased, the edges of the sclerotic are stitched together and the conjunctiva united over it.

In **Mule's operation** the opening is enlarged vertically to admit of the introduction of a hollow glass or silver or aluminum sphere. The margins of the sclerotic are now united vertically by interrupted

silk sutures; the conjunctiva is then sutured at right angles to the scleral closure. Two points of importance are strict antisepsis and the checking of all bleeding in the cavity before the glass ball is inserted. The advantages claimed for this operation are that it leaves muscular attachments to the stump and offers a movable ball on which to insert an artificial shell; that it keeps the orbit filled out; and that it lessens the danger of meningeal infection, sometimes following enucleation. The cosmetic improvement is by far the greatest point in its favor. The operation is of particular value in staphyloma of the cornea and in disfiguring leukoma. The disadvantages are the uncertainty of result, possible infection, and sympathetic involvement, though the occurrence of the latter is rare.

Some operators practise insertion of the glass sphere in the capsule of Tenon instead of the scleral cavity. The operation is similar to an enucleation except that the recti muscles are secured with sutures before dividing them. The glass sphere is placed in the cavity previously occupied by the eyeball, and the sutures holding the four recti are tied tightly together over it; care must be exercised to secure adaptation of the sutures, so that the tendons assume the same position they occupied in the living eye. This operation eliminates all the dangers and disadvantages of evisceration or Mule's operation, and leaves as useful a stump.

TOTAL COMBINED KERATECTOMY is the name given to an operation which Panas has most successfully used for several years in all cases in which enucleation is ordinarily indicated. A half-curved Reverdin needle is introduced through the sclerocorneal junction, passed back of the iris and lens, coming out at a point opposite. The needle is then armed with a thread and allowed to remain in place. The cornea is detached as in evisceration. The iris is removed by forcibly tearing with a pair of forceps. The speculum is gently raised away from the globe by an assistant. The lens is next removed with a scoop, care being taken not to lose any vitreous. The Reverdin needle, armed with its thread, is now withdrawn and the suture made is tied. Two sutures, one on each side of the middle one, are made and tied. The projecting angles of the wound are trimmed with scissors, and the wound is dressed antiseptically.

ENUCLEATION.—The patient is placed on an operating table and,

preferably, anesthetized with ether or chloroform, although sometimes local anesthesia with cocain alone is used. After thorough disinfection of the eyeball and neighboring parts, a speculum is introduced, the arms of which are widely separated. A fold of conjunctiva is seized by a fixation forceps in the left hand, opened with a pair of enucleation scissors curved on the flat, and cut close entirely around the circumference of the cornea. The separated conjunctiva and capsule of Tenon are pushed back with the closed scissors. The tendon of the internal or external rectus muscle is seized by the fixation forceps close to the insertion and divided back of the forceps. One blade of the scissors is passed under the tendon of the superior rectus, which, with the tissues surrounding it, is divided close to the globe. The inferior rectus is then severed at one clip; the globe is then rotated forward and toward the nose, the scissors passed backward, and the optic nerve and the adjoining tissue divided. The globe is then seized with the fingers and forced from the socket, and the remaining tendons and attached tissues separated from it. Instead of crowding wet antiseptic sponges into the orbit to check the hemorrhage, it is better to simply irrigate the cavity with sterile cold water, and thus avoid crushing and lacerating the remaining muscles. These muscular remnants are then puckered to a point with a "purse-string" suture, and afford a more or less movable stump. When the bleeding has subsided, the cavity is washed out with a sublimate solution and an absorbent sponge or wad of cotton is placed over the orbit, leaving free drainage, and a bandage applied without exerting undue pressure. The old custom of immediately applying a pressure-bandage after enucleation to check hemorrhage is not advisable. It is better to delay permanent bandaging until the hemorrhage has subsided. The dressing may be changed in twenty-four hours, and the parts cleansed with a sublimate solution and a new dressing applied. After the fourth day the bandage may be discarded, and the patient given a mild antiseptic wash to use in the eye two or three times daily until the wound is completely healed.

An artificial eye may be worn after a lapse of two or three weeks, if all inflammation has subsided. Early application of the artificial eye is advisable to prevent absorption of the orbital fat. It must be remembered that the orbit is very tolerant of foreign bodies; however, to thoroughly accustom the orbit, the artificial eye should not be worn over a few hours at a time for the first few days. To in-

sert an artificial eye, it is lubricated and the broad outer end slipped under the upper lid, which is slightly raised. The lower lid is then drawn downward, the patient directed to look down, and the eye is gently manipulated into place. Irritation of the stump by an artificial eye has led to sympathetic inflammation of the other eye, and must be guarded against. An artificial eye should be taken out at night and placed in water.

EXENTERATION OF THE ORBITAL CONTENTS, usually for malignant growth, is performed by splitting the external canthus, separating the entire periosteum with all its contents from the bony wall, except at the apex of the orbit. Enucleation scissors are introduced, and the stump cut off close to the bone. Profuse hemorrhage is best checked by actual cautery. If the neighboring skin or the lids are involved, the incision must be made into healthy tissue, and the diseased parts removed with the orbital contents.

LOCAL OCULAR THERAPEUTICS.

Airol is a substitute for iodoform; it is practically dermatol with the addition of iodine. It is said to be efficacious in corneal ulcers and hypopyon. A ten per cent. vaselin ointment is used.

Alum is a useful astringent in chronic conjunctivitis, and may be used in solutions of from two to eight grains to one ounce of boric solution, dropped freely into the eye three or four times a day. Crystals of alum cut into smooth pencils and fitted into handles are useful in chronic palpebral conjunctivitis. They are applied to the lid in the manner described on page 165. The point of the pencil should never be allowed to become sharp.

Anesin is the newest local anesthetic. It is said to be an aqueous solution of acetone-chloroform. A one per cent. solution is used to produce local anesthesia, and it is described as twice as powerful. It produces no local irritation, and is nontoxic and does not produce mydriasis.

Antinosin is a sodium salt of nosophen. It has been used in weak strengths ($\frac{1}{4}$ per cent.) in inflammations of the anterior portion of the eye.

Arecolin hydrobromate has been used as a miotic in glaucoma in 1 : 100 solution.

Argonin is one of the numerous silver-casein compounds appearing lately. It is used in conjunctivitis, particularly that due to the gonococcus, in one to two per cent. solution.

Atropin is generally used in the form of the soluble sulphate. It is a powerful local anodyne, and is the most commonly used mydriatic and cycloplegic. As a mydriatic, it should be prescribed in solutions of four grains to the ounce, one drop of which is applied three or four times a day. From ten days to two weeks are required for the eye to recover from the effects of such a solution. Weaker solutions (one

grain to the ounce) may be combined with boric acid in cases in which routine administration is desirable. The contraindication to atropin and all other mydriatics is increased intraocular tension. All solutions should be labeled "*poison drops*." In cases of idiosyncrasy, the dryness of the throat, flushed face, general excitability, etc., are indications for the suspension of the drug and the administration of opium, its physiologic antidote. A full dose of paregoric is a ready remedy in such cases. Often in cases of sluggish iris the atropin solution should be heated before instillation into the eye.

Atropin sulphate, gr. j
Distilled water, ℥ ij.

DIRECTIONS.—One drop in each eye three times a day.

For ordinary mydriasis and cycloplegia.

Atropin, gr. ij
Cocain, ℥r. x
Vaselin, ℥j.

Dissolve by warmth.

For use when an ointment is preferable to drops or when there is intense ocular pain.

Bleeding, in ocular congestion, particularly for the relief of pain in corneal and iritic inflammations, is a very valuable procedure. It is most satisfactorily effected by the application of three or four leeches to the temple of the side affected. The Heurteloup artificial leech is really a cupping instrument, which exhausts the air in a long glass cylinder applied to fine incisions over the temple. It draws the blood more rapidly than the natural leech, but has not given us as good results.

Boric acid is extensively used as a mild antiseptic lotion in solutions of ten grains to the ounce. It is hardly to be classed as an antiseptic; but on account of its soothing qualities, is to be recommended in cases in which only a simple lotion is necessary.

The following are common formulas :

Boric acid, gr. xl
Distilled water, ℥ iv.

Bathe the eyes freely several times a day.

Boric acid, gr. xl
Camphor water, } of each, ℥ ij.
Distilled water, }

Bathe the eyes freely several times a day.

Boroglycerid is made by heating together sixty-two parts of boric acid and ninety-two parts of glycerin at a uniform temperature of 300° F., until the mixture is reduced to 100 parts. A glycerite is then made by adding 100 parts of glycerin, warming and filtering. This fifty per cent. solution in glycerin is the strength ordinarily used, and is conveniently dispensed in two-dram collapsible tubes. Boroglycerid is a most valuable application in all forms of conjunctivitis, but finds its greatest use in trachoma, for which it is by far the most valuable application. It is an excellent antiseptic, and may be prescribed in aqueous solution of less than ten per cent. strength.

Calomel is a valuable local application in phlyctenular ophthalmia, chronic keratitis, pannus, and in small indolent corneal ulcers. It is used as a fine, dry powder, and is dusted directly upon the cornea with a camel's-hair brush. It should not be used if there is much ciliary irritation. A second application must not be made until the first is absorbed, and the drug should not be used if the patient is taking full doses of the iodine preparations.

Camphor water has been greatly used in combination with boric acid solutions in the treatment of conjunctivitis. *See Boric acid.*

Cassaripe is a concentrated semisolid juice of the cassava-plant of the tropics. A ten per cent. ointment has been used in cases of ulcer of the cornea and purulent disease of the conjunctiva.

Cautery by heat is of great use in serpiginous and chronic indolent ulcers of the cornea, in corneal abscess and fistula, and in obstinate cases of pustular keratitis. A probe or strabismus hook, or any properly shaped metallic instrument, may be used; but the galvanocautery is to be preferred.

Cocain.—The chief use of cocain in ophthalmic surgery is to produce conjunctival and corneal anesthesia, either for the relief of pain in iritis, cyclitis, hyperesthesia of the retina, etc., or to produce local anesthesia for operations on the eye. It is also used as a temporary mydriatic for ophthalmoscopic purposes, in which case any tendency to produce glaucoma after the examination is finished is easily averted by a drop of a solution of eserine, $\frac{1}{2}$ of a grain to the ounce. For anodyne purposes, such as the use in iritis and cyclitis, etc., it is better to use atropin, on account of the transient action of cocain and the possible dangers from its long-continued use. In proportion of one or two grains to the ounce it may be added to ordinary antiseptic and astringent washes. It is frequently combined with atropin in the

treatment of iritis, and with homatropin to facilitate mydriasis and cycloplegia. The greatest use of cocain is in operative ophthalmic surgery; it has even been used in some cases of enucleation. It should be prescribed:

Cocain hydrochlorate,	gr. x-xx
Distilled water,	ʒj.

Collodion is used in dressings for wounds of the eyelid or eyebrow, and is freely painted over the skin in cases of senile entropion to produce contraction of the relaxed skin.

Copper sulphate ("blue stone") is occasionally employed as a collyrium, in the treatment of chronic conjunctivitis, in the proportion of $\frac{1}{2}$ of a grain to the ounce. In the form of crystal or pencil applied to the everted lid, it is used in trachoma. The old lapis divinus was composed of equal parts of copper sulphate, potassium nitrate, and alum, molded into a pencil.

Duboisin is sometimes used as a mydriatic and cycloplegic. Recovery takes place in from five to seven days.

Duboisin sulphate,	gr. ss
Distilled water,	ʒij.

Electrolysis has been used both as a means of cure in chronic inflammations and as a means of diffusing drugs into the eye, and facilitating absorption. It has done some good in corneal opacities, trachoma, and pterygium; it has been recommended as the best method of applying eserin in glaucoma and atropin in iritis.

Electrotherapy has been urged in scleritis, iritis, iridocyclitis, vitreous opacities, and purulent keratitis. The anode is placed against the closed lid, and the kathode against any part of the head or neck. Commencing with 0.5 ma., the current is slowly increased to 2 ma. or more. Reuss believes that faradism is preferable to galvanism in most cases.

Ephedrin hydrochlorate has been used in five per cent. solution to effect mydriasis without causing ciliary paralysis—as, for instance, in iritis or ophthalmoscopic examination.

Eserin is the most common miotic. Its effect on the accommodation lasts only a few hours, but the pupil may be contracted for several days. It is used in glaucoma, in peripheral wounds of the cornea, and in some forms of corneal ulcer. It is prescribed:

Eserin sulphate or salicylate,	gr. $\frac{1}{2}$
Distilled water,	ʒij.

Eucain has recently been offered as a substitute for cocain in producing ocular anesthesia. Although several enthusiastic reports of its advantages over the older drug have been published, its position in ocular therapeutics has not been definitely established. An especial preparation, *Eucain B* hydrochlorate, has been manufactured for ophthalmic practice. It does not dilate the pupil nor affect accommodation, and is less toxic. On the other hand, it possibly favors hemorrhage, its anesthetic effect is less complete, and it is more disagreeable to the patient than cocain. Both have the same effect on the cornea and upon intraocular tension. It is used in two per cent. solution.

Euphthalmin is a recent mydriatic. It acts within two or three minutes, and is supposed to have no effect on the accommodation, corneal epithelium, or intraocular tension. Mydriasis lasts about seven hours. It is used in five per cent. to ten per cent. solutions.

Fluorescin is used to mark out the precise area of denudation in corneal abrasion or ulcer. It is prescribed :

Fluorescin,	gr. iv
Liquor potassa,	ʒ i
Distilled water,	ʒ iv.

A drop applied over the cornea, and washed off.

A spot denuded of epithelium becomes yellowish-green.

Formalin is a forty per cent. aqueous solution of formic aldehyd. It is a powerful germicide, and is valuable in the disinfection of instruments. Solutions of $\frac{1}{2}$ per cent. are usually strong enough in ordinary surgical antiseptics. For septic corneal abrasions and corneal ulcers, the local application of formalin in 1 : 2000 or 1 : 3000 aqueous solution is of great value. It is also used in full strength to limit and remove malignant growths.

The sterilization of instruments by means of the vapor of burning paraform pastils is the best means we have. A number of convenient formalin sterilizers have been marketed.

Glycerin is used as an excipient, particularly in the form of glycerol of tannin and in boroglycerid. These preparations are valuable in all forms of palpebral conjunctivitis.

Hamamelis (Witch Hazel).—The ordinary distillate of hamamelis is a pleasing anodyne and sedative application in acute conjunctivitis. It should be diluted with one or two parts of water, and may be combined with the ordinary boric acid solution. To be used freely.

Heat and cold are valuable antiphlogistic and analgesic local measures. In general terms, ice-cold applications are more soothing in conjunctival and lid inflammations, and heat in diseases of the cornea, iris, and deeper tissues.

Holocain is an efficient anesthetic and germicide. Many observers report that it is superior to cocain in nearly every operation. It has apparently little or no effect on the conjunctival vessels, iris, or ciliary muscle. It is used in one per cent. solutions. Hotz says that it is more painful and irritating to the conjunctiva than cocain. Its anti-septic properties are greatly in its favor. It has been used with success in the treatment of suppurative keratitis.

Homatropin is a useful mydriatic and cycloplegic. It is especially serviceable in office practice, in which it is often desirable that the paralysis of accommodation shall not extend over one or two days. In such cases it should be prescribed :

Homatropin hydrobromate,	gr. j
Cocain hydrochlorate,	gr. ss
Distilled water,	ʒj.

Before refraction, one drop of this solution should be used in each of the eyes, five or six times, at intervals of ten minutes. The accommodation usually returns by the end of the second day.

Hydrogen dioxid is an excellent detergent in purulent ophthalmia, sloughing ulcers of the cornea, and suppuration of the lacrimal passages. It is used in fifty per cent. strength of the ordinary fifteen-volume solution.

Hyoscyamin is physiologically the same as duboisin in its action. It is prescribed as follows :

Hyoscyamin hydrobromate,	gr. ss
Distilled water,	ʒij.

Ichthalbin is a compound of ichthyol and albumin, said to represent all the desirable properties of ichthyol without its disagreeable odor. It has an analgesic action. Wolffberg has given it *internally* in about forty cases of glaucoma and iritis, in doses of eight grains thrice daily. It has been used locally in pannus and keratitis.

Ichthyol has been used in fifty per cent. solution, to which a little glycerin may be added, in all forms of palpebral conjunctivitis. It may be applied in the form of a ten per cent. ointment in cases of blepharitis.

Iodin has been used locally in trachoma, starting with $\frac{1}{2}$ per cent solution and increasing slowly up to two or three per cent.

Iodoform is a valuable remedy in almost all forms of corneal disease, and is used after operations on the lids or after enucleation. It is also useful in diminishing vascularity of the cornea, and in clearing up corneal opacities. It may be dusted upon the eye in fine powder or applied as an ointment, with or without massage, in strength of $\frac{1}{4}$ to one dram to the ounce. After dusting iodoform on the cornea, the upper lid should be pulled outward and downward over the cornea and held in place for a few minutes; otherwise movement of the lid or eyeball will brush the powder off the cornea. The only objection to iodoform is its odor.

Itrol (silver citrate) and actol (silver lactate) have been used in purulent conjunctivitis and keratitis, but little is known of them.

Jequirity has been extensively used to induce acute purulent conjunctivitis in desperate cases of trachoma, and it should be resorted to only with the greatest caution and in extreme cases. It should be used only when there is pannus. The infusion is prepared by macerating three parts of the pulverized seeds in 500 parts of cold water for twenty-four hours, and adding 500 parts of boiling water, cooling and filtering. A mild solution is applied to the eyes three times daily for two days, or until sufficient inflammation is produced. Each application should be followed by irrigation with a boric acid solution.

Mercuric chlorid (corrosive sublimate) is probably the most satisfactory agent for the disinfection of the diseased surfaces of the eye. As a usual eye lotion in ordinary cases, it may be prescribed in solutions of 1 : 8000. In such strength it can be safely used several times a day without exciting or causing irritation. A solution of 1 : 3000 is possibly better for cleansing the eye and adjacent tissues before an operation, and for irrigation afterward; or as a lotion when there is a profuse purulent discharge. The stronger solutions, 1 : 500 and 1 : 1000, may be used for disinfecting instruments, and for irrigation in dacryocystitis or in purulent ophthalmia. The 1 : 5000 sublimate solution is of especial value as an eye-wash in eczematous affections of the lids. The ordinary formula for a 1 : 5000 sublimate solution is:

Mercuric chlorid,	gr. $\frac{1}{10}$
Distilled water,	$\frac{3}{j}$.

What is known as **Panas' solution** consists of mercuric iodid one, potassium iodid five, and distilled water 20,000 parts. It is used for irrigation of the anterior chamber, and possesses no advantages over simple sterilized water.

Mercuric oxid (yellow oxid) was introduced into ophthalmic therapeutics by Pagenstecher, and the ointment is sometimes known by his name. In blepharitis and phlyctenular ophthalmia it is of particular value applied to the lids at night, using a piece the size of a large pin-head. Massage with **Pagenstecher ointment** is of service in chronic keratitis and pannus, and in clearing up corneal opacities. It should be prescribed :

Yellow mercuric oxid (amorphous), gr. $\frac{1}{4}$ -j
Vaselin, ʒj.

Nosophen has been recommended in corneal disease.

Opium.—The wine of opium was much used by old surgeons as a collyrium in the treatment of conjunctivitis, but has passed out of use. The acetate of morphin is a convenient anodyne in acute conjunctivitis. Five grains of acetate of morphin, $\frac{1}{2}$ of a grain of acetate of zinc, and ten drops of dilute acetic acid, to the ounce of water, have been recommended as an eye-wash.

Picric acid, 5 or 10 : 1000, has been used in blepharitis and as an antiseptic collyrium.

Pilocarpin is a decided miotic, but much milder than eserin. It can hardly be recommended in preference to eserin, although some authorities claim that it is entirely free from the tendency to produce iritis. It is prescribed :

Pilocarpin hydrochlorate, gr. $\frac{1}{4}$ - $\frac{1}{2}$
Distilled water, ʒij.

Pilocarpin is also often used systemically in cases of severe ocular disease, to produce diaphoresis.

Potassium permanganate is used as an antiseptic lotion, in strength varying from one to five grains to the ounce.

Protargol is a proteid compound of silver containing eight per cent. of the metal. It has many strong advocates as a substitute for silver nitrate. It is not so painful, is more germicidal, has greater penetrating powers, and does not form a precipitate with albumin. It has been used in all forms of conjunctivitis in strengths of from two gr

cent. to fifty per cent. A two per cent. solution is generally used as a collyrium. Recently there has been considerable dissent from the numerous favorable reports, and there has been an inclination to restrict its use to the milder inflammations of the conjunctiva.

Pyoktanin is an antiseptic and weak analgesic, and is used in solutions of 1 : 1000 or 1 : 2000. It has been recommended in inflammations of the conjunctiva, cornea, and even in serous iritis and choroiditis.

Sanoform has been recommended as a substitute for iodoform.

Sassafras, in the form of the officinal mucilage, is a popular domestic remedy in the treatment of acute conjunctivitis. A very satisfactory combination is:

Boric acid,	gr. xij
Mucilage of sassafras pith,	ʒ ij
Mercuric chlorid,	gr. $\frac{1}{5}$
Sodium chlorid,	gr. x
Camphor water, } of each,	ʒ iss.
Distilled water, }	

Scopolamin is recommended as a substitute for atropin, both for cycloplegia in refraction and in the treatment of iritis. It is prescribed:

Scopolamin hydrobromate,	gr. $\frac{1}{8}$
Distilled water,	ʒ ij.

DIRECTIONS.—One drop in the eye every fifteen minutes for an hour.

It is claimed that the ciliary muscle is paralyzed one hour after the first instillation. The paralysis lasts about seventy-two hours, and can be shortened by the application of a weak solution of eserine used several times.

Silver nitrate is a valuable astringent and antiseptic, and may be applied to the lids in a one per cent. solution in ordinary mucopurulent conjunctivitis. A two per cent. solution may be used in cases in which there is profuse purulent discharge; or a less strong solution may be dropped into the eyes of a new-born infant, when there is reason to anticipate ophthalmia neonatorum. Stronger solutions may be used in cases of severe ophthalmia, but it is advisable to neutralize it soon after application with a normal salt solution. After application of nitrate of silver to the lids, they should be washed with absorbent cotton and warm water before being allowed to close. The

lunar caustic, or the "mitigated stick," is often of value in reducing proliferated granular tissue in the conjunctiva of the lids.

Silver nitrate, gr. v
Distilled water, ℥j.

One instillation daily, in ordinary mucopurulent conjunctivitis.

Silver nitrate, gr. x
Distilled water, ℥j.

One application daily, in profuse purulent conjunctivitis and ophthalmia neonatorum.

Silver nitrate, gr. xx
Distilled water, ℥j.

For alternate use in trachoma.

Suprarenal capsule is said to be an ideal hemostatic and astringent in all congestions and in operations. Ten grains of the extract are macerated for thirty minutes in two drams of water and then filtered, the filtrate representing a one per cent. solution of the extract. Suprarenal capsule is put up in five-grain tablets, which may be dissolved in a cold boric acid solution.

Tannic acid is used in chronic conjunctivitis, either in solutions of two to five grains to the ounce, dropped in the eye, or in strength of ten to thirty grains to the ounce, painted on the everted lids. In cases of old granular lids, the full strength of glycerite of tannin (*Glycerinum Acidi Tannici*, B. P., one part to four) may be applied to the everted lids. The old domestic remedy for "sore eyes"—tea-leaves—owed its efficacy in some cases to the tannin in the leaves.

Thiosinamin, gr. j to gr. iij, has been administered internally or by hypodermic injection to hasten absorption of corneal opacities. It is of doubtful value.

Toluidin blue, a member of the anilin group closely allied to methylene blue, has been employed as a collyrium in strength of 1 : 1000, and as a stain for corneal abrasions and ulcers. It is a very effective antiseptic, and is not irritating.

Xeroform represents fifty per cent. tribromphenol. It has been used for its antiseptic action as a substitute for iodoform in corneal disease.

Zinc acetate and **zinc sulphate** are used either separately or in combination in the milder forms of conjunctivitis as a lotion of the strength of one to two grains to the ounce.

Zinc chlorid is a useful remedy in many forms of acute conjunctivitis, or it may be applied to the everted lid in trachoma. Rather weak solutions of $\frac{1}{4}$ to two grains to the ounce of water may be given to the patient to drop in the eye. This substance should be avoided if there is any severe corneal affection. The following mixture may be used freely in all mucopurulent inflammations about the eye:

Boric acid,	gr. xl
Sodium chlorid,	gr. x
Zinc chlorid,	gr. ij
Distilled water,	$\frac{3}{4}$ iv.

Stain with pyoktanin, and doubly filter after standing.

The patient should be told that this lotion will smart at first, and that he should instil it in the eye when lying on his back, and not close the eyes violently and squeeze it out, but draw the lids together gently and roll the eye slowly about for several minutes.

VALUABLE FORMULAS FOR INTERNAL MEDICATION.

Mercuric chlorid,	gr. ij
Potassium iodid,	$\frac{3}{4}$ iv
Distilled water,	} of each, $\frac{3}{4}$ iij.
Syrup of sarsaparilla,	

A teaspoonful three times a day.

Or—

Mercuric biniodid,	gr. ij
Potassium iodid,	$\frac{3}{4}$ ij
Distilled water,	$\frac{3}{4}$ iij
Syrup of sarsaparilla,	q. s. ad $\frac{3}{4}$ iij.

A teaspoonful three times a day.

Useful as a tonic, alterative, and antisyphilitic; and indicated in all acute and subacute attacks of inflammation of the eyeball in which internal medication is suggested. It is also valuable as a preliminary to operation on the eye.

Mercuric chlorid,	gr. ij
Extract of belladonna,	gr. iv.

Make into 40 pills.

One pill three times a day. Useful in all forms of chorioretinitis.

DISINFECTION OF INSTRUMENTS.

Instruments are best disinfected by immersion in alcohol, formalin, boiling water, or exposure to superheated steam in a sterilizer. For—

malin sterilizers are now manufactured. They consist of air-tight compartments in which paraform pastils are burned. Immersion of instruments in such solutions as pyoktanin, mercuric chlorid, and carbolic acid are other less valuable methods. Corrosive action is to be avoided, as the edges of ophthalmic knives are very easily dulled.

ABBREVIATIONS USED IN OPHTHALMOLOGY.

<p>Acc. . . . Accommodation.</p> <p>Am. . . . Ametropia.</p> <p>As. . . . Astigmatism.</p> <p>As. H. . . . Hyperopic Astigmatism.</p> <p>As. M. . . . Myopic Astigmatism.</p> <p>Ax. . . . Axis.</p> <p>B. D. . . . Base (of prism) down.</p> <p>B. I. . . . " " " in.</p> <p>B. O. . . . " " " out.</p> <p>B. U. . . . " " " up.</p> <p>cm. . . . Centimeter.</p> <p>Cyl. . . . Cylinder, Cylindric Lens.</p> <p>D. . . . Diopter.</p> <p>E. . . . Emmetropia, Emmetropic.</p> <p>F. . . . Formula.</p> <p>H. . . . Hyperopia, Hyperopic, Horizontal.</p> <p>L. . . . Left Eye.</p> <p>L. D. . . . Light-difference.</p> <p>L. E. . . . Left Eye.</p> <p>L. M. . . . Light-minimum.</p> <p>M. . . . Myopia, Myopic.</p>	<p>m. . . . Meter.</p> <p>mm. . . . Millimeter.</p> <p>O. D. . . . Oculus dexter—Right Eye.</p> <p>O. S. . . . Oculus sinister—Left Eye.</p> <p>O. U. . . . Oculi utrique—Both Eyes.</p> <p>O². . . . Both Eyes.</p> <p>P. p. . . . Punctum proximum, Near Point.</p> <p>Pr. . . . Prism.</p> <p>P. r. . . . Punctum remotum, Far Point.</p> <p>R. . . . Right Eye.</p> <p>R. E. . . . Right Eye.</p> <p>Sph. . . . Spheric, Spheric Lens.</p> <p>Sym. . . . Symmetric.</p> <p>V. . . . Vision, Visual Acuity, Vertical.</p> <p>+ , - , = Plus, Minus, Equal to.</p> <p>∞ . . . Infinity, 20 ft. distance.</p> <p>○ . . . Combined with.</p> <p>° . . . Degree.</p>
---	--

GLOSSARY OF OPHTHALMOLOGIC TERMS.

INCLUDING DERIVATIONS AND DEFINITIONS.

(Condensed from Gould's Illustrated Dictionary of Medicine.)

A.

- Abduction** (*ab-duk'-shun*) [*ab*, from; *ducere*, to lead]. The power of the external recti of drawing the eyes outward, measured by the maximum ability to preserve singleness of the image with prisms placed bases toward the nose; it is commonly from 4° to 8°.
- Achromatopsia** (*ah-kro-mat-opt'-se-ah*) [*á* priv.; *χρῶμα*, color; *ὄψις*, eyesight]. Color-blindness.
- Adduction** (*ad-duk'-shun*) [*adducere*, to bring forward]. The power of the internal recti to move the eyeballs outward, measured by the maximum ability to preserve singleness of the image with prisms placed bases toward the temples; it varies from 15° to 40°.
- Amaurosis** (*am-aw-ro'-sis*) [*ἀμαυρόειν*, to darken]. Partial (or total) loss of vision.
- Amblyopia** (*am-ble-ō'-pe-ah*) [*ἀμβλῦς*, dulled; *ὄψις*, the eye]. Subnormal acuteness of vision.
- Ametropia** (*ah-met-ro'-pe-ah*) [*á* priv.; *μέτρον*, a measure; *ὄψις*, sight]. The condition in which there is the formation of an imperfect image on the retina, due to defective refractive power of the media (or to some abnormality of the eye).
- Aniridia** (*an-i-rid'-e-ah*) [*án* priv.; *ίρις*, the rainbow]. Absence or defect of the iris.
- Anisocoria** (*an-is-o-kō'-re-ah*) [*ἀνισος*, unequal; *κοπή*, pupil]. Inequality in the diameter of the pupils.
- Anisometropia** (*an-is-o-met-ro'-pe-ah*) [*ἀνισος*, unequal; *μέτρον*, a measure; *ὄψις*, the eye]. A difference of refraction in the two eyes.
- Ankyloblepharon** (*ang-kil-o-blef'-ar-on*) [*ἀγκύλη*, a loop; *βλέφαρον*, the eyelid]. Adhesion of the ciliary edges of the eyelids.
- Anophthalmos** (*an-off-thal'-mos*) [*án* priv.; *ὀφθαλμός*, eye]. Congenital absence of the eyes.
- Aphakia** (*ah-fa'-ke-ah*) [*á* priv.; *φακός*, the crystalline lens]. The condition of the eye without the lens.
- Aplanatic** (*ah-plan-at'-ik*) [*á* priv.; *πλανᾶειν*, to wander]. Pertaining to rectilinear lens; corrected for aberration of light and color.
- Arcus senilis** (*ar'-kus sen-ilis*) [*arcus*, a bow; *senilis*, of the old]. A ring of fatty degeneration seen about the periphery of the cornea in old persons.
- Asthenopia** (*as-then-ō'-pe-ah*) [*á* priv.; *σθένος*, strength; *ὄψις*, eye]. Weakness or speedy fatigue of visual power.
- Astigmatism** (*as-tig'-mat-izm*) [*á* priv.; *στίγμα*, a point]. The condition in which rays are not brought to a point or focus upon the retina.

B.

- Blehnorrhœa** (*blen-or-e' ah*) [*βλένω*, mucus; *ρέειν*, to flow]. Excessive mucous discharge.
- Blepharadenitis** (*blef-ar-ad-en-i'tis*) [*βλέφαρον*, the eyelid; *ἀδην*, a gland; *ιτις*, inflammation]. Inflammation of the Meibomian glands.
- Blepharitis** (*blef-ar-i'tis*) [*βλέφαρον*, the eyelid; *ιτις*, inflammation]. Inflammation of the eyelid.
- Blepharophimosi**s (*blef-ar-o-fi-mo'-sis*) [*βλέφαρον*, the eyelid; *φίμωσις*, shutting up]. Abnormal smallness of the palpebral fissure.
- Bullosa** (*bul-o'-sah*) [*bullâ*, a blister]. With blisters or blebs.
- Buphthalmos** (*boof-thal'-mos*) [*βοῦς*, an ox; *ὄφθαλμός*, eye]. Ox-eyed. See *Keratoglobus*.

C.

- Canthoplasty** (*kan'-tho-plas-te*) [*κανθός*, the canthus; *πλασσειν*, to form]. A surgical operation for lessening the pressure and friction of the upper lid by cutting the outer canthus.
- Canthus** (*kan'-thus*) [*κανθός*, canthus]. The inner or outer angle formed by the juncture of the eyelids.
- Caruncle** (*kar'-ung-kl*) [diminutive of *caro*, flesh]. A fleshy protuberance upon the conjunctiva near the inner canthus, containing the lacrimal punctum.
- Cataract** (*kat'-ar-akt*) [*καταράκτης*, a waterfall]. Opacity of the lens or its capsule.
- Chalazion** (*kal-a' ze-on*) [*χαλάζιον*, a small hailstone]. A Meibomian cyst.
- Chemosis** (*ke-mo'-sis*) [*χήμεσις*, a gaping]. A swelling (subconjunctival).
- Choroid** (*ko'-roid*) [*χόριον*, skin; *εἶδος*, like]. The vascular tunic of the eye.
- Chromatic** (*kre-mat'-ik*) [*χρῶμα*, color]. Relating to color.
- Chromatopsia** (*kre-mat-op'-se-ah*) [*χρῶμα*, color; *ὄψις*, vision]. Abnormal sensation of color, due to disorders of the optic centers, or to drugs, especially santonin.
- Cilia** (*sil'-e-ah*) [*cilium*, the eyelid or lash]. The eyelashes.
- Collyrium** (*kol-e'-re-umi*) [*κολλήριον*, an eye-salve]. An astringent, antiseptic, or medicinal lotion for the eyes.
- Coloboma** (*kol-o-bō'-mah*) [*κολοβῶεν*, to mutilate]. A fissure of parts of the eye, congenital or traumatic.
- Conus** (*ko'-nus*) [*κῶνος*, a cone]. A crescentic patch of atrophic choroid tissue near the optic papillas in myopia.
- Corectopia** (*kor-ek-to'-pe-ah*) [*κόρη*, the pupil; *ἐκτοπος*, misplaced]. See *Korectopia*.
- Cornea** (*kor'-ne-ah*) [*corneus*, horny]. The anterior transparent segment of the eyeball.
- Couching** (*kouch'-ing*) [Fr., *coucher*, to depress]. The operation, now fallen into disuse, of depressing a cataractous lens into the vitreous chamber, where it was left to be absorbed.
- Cyclitis** (*si-klit'-tis*) [*κύκλος*, a circle (around the eye); *ιτις*, inflammation]. Inflammation of the ciliary body.
- Cycloplegia** (*si-klo-ple'-je-ah*) [*κύκλος*, circle; *πληγή*, a stroke]. Paralysis of the ciliary muscle of the eye.

D.

- Dacryoadenitis** (*dak-re-o-ad-en-i'tis*) [*δάκρυον*, a tear; *ἀδην*, a gland]. Inflammation of a lacrimal gland.

- Dacryocystitis** (*dak-re-o-sis-ti'-tis*) [*δάκρνον*, a tear; *κύστις*, a sac]. Inflammation of the lacrimal sac.
- Dacryocystoblennorrhœa** (*dak-re-o-sis-to-blēn-or-e'-ah*) [*δάκρνον*, a tear; *κύστις*, a sac; *βλέννα*, mucus; *ροία*, a flow]. Flow of tears from the lacrimal sac.
- Dacryolith** (*dak'-re-o-lith*) [*δάκρνον*, a tear; *λίθος*, a stone]. A lacrimal calculus.
- Dacryops** (*dak'-re-ops*) [*δάκρνον*, a tear; *ὤψ*, the eye]. Watery eye.
- Daltonism** (*dal'-ton-ism*) [*Dalton*, an English physicist]. Color-blindness.
- Dendritica** (*den-drit'-ik-ah*) [*δένδρον*, a tree]. Tree-like.
- Descemetitis** (*des-em-et-i'-tis*) [*Descemet*; *ιτις*, inflammation]. Inflammation of Descemet's membrane.
- Diopter** (*di-op'-ter*) [*διά*, through; *ὄψεσθαι*, to see]. The metric unit of measurement for lenses.
- Dioptrics** (*di-op'-triks*) [*διά*, through; *ὄψεσθαι*, to see]. A branch of optics treating of the refraction of light by transparent media, especially by the media of the eye.
- Diplopia** (*dip-lo'-pe-ah*) [*διπλῶς*, double; *ὄψις*, sight]. Double vision, one object being seen by the eye or eyes as two.
- Discission** (*dis-ish'-un*) [*discissio*; *discindere*, to tear or cut apart]. An operation for soft cataract.
- Distichiasis** (*dis-tik-i'-as-is*) [*δίς*, double; *στιχός*, row]. Double row of eyelashes.
- τρέπειν*, to turn]. Eversion (of an eyelid).
- Eczema** (*ek'-ze-mi-ah*) [*ἐκζεῖν*, to boil over]. A catarrhal inflammation of the skin.
- Edema** (*e-de'-mah*) [*οἴδημα*, a swelling]. Swelling due to effusion of serous fluid into areolar tissues.
- Emmetropia** (*em-et-ro'-pe-ah*) [*ἐν*, in; *μέτρον*, measure; *ὤψ*, eye]. Normal vision.
- Enophthalmos** (*en-off-thal'-mos*) [*ἐν*, in; *ὀφθαλμός*, eye]. An unusually deep or posterior location of the eyeballs in the orbits.
- Entropion** (*en-tro'-pe-on*) [*ἐν*, in; *τρέπειν*, to turn]. Inversion (of the eyelid).
- Epicanthus** (*ep-e-kan'-thus*) [*ἐπί*, on; *καθός*, angle of the eye]. A fold of skin passing from the nose to eyebrow.
- Epilation** (*ep-il-a'-shun*) [*ε*, out of; *πίλος*, a hair]. The extraction of a cilium.
- Epiphora** (*ep-iff'-or-ah*) [*ἐπί*, on; *φερεῖν*, to bear]. A persistent overflow of tears.
- Erythrospia** (*er-ith-rof'-se-ah*) [*ἐρυθρός*, red; *ὄψις*, vision]. Red vision.
- Esophoria** (*es-o-fo'-re-ah*) [*εἶσω* (or *εἰσω*), within; *φορεῖν*, to bear]. Tending of the visual lines inward.
- Exophoria** (*eks-o-fo'-re-ah*) [*ἐξω*, without; *φορεῖν*, to bear]. Tending of the visual lines outward.
- Exophthalmos** (*eks-off-thal'-mos*) [*ἐξ*, out; *ὀφθαλμός*, eye]. Abnormal prominence of the eyeball.

F.

- E.**
- Ectasia** (*ek-ta'-se-ah*) [*ἐκτασις*, extension]. Abnormal distention or dilatation of a part.
- Ectropion** (*ek-tro'-pe-on*) [*ἐκ*, out;
- Fovea** (*fo-ve'-ah*) [*fovea*, a small pit]. A depressed spot in the macula, at which there is the most distinct vision.
- Furuncle** (*fu-rung'-kl*) [*furuncu-*

lus, Lat. (from Sanskrit), to burn].
A boil.

G.

Glaucoma (*glow-ko'-mah*) [*γλαυκός*, sea-green]. A disease of the eye; so called on account of the green color of the pupil.

Glioma (*gli-o'-mah*) [*γλία*, glue; *όμα*, tumor]. A variety of round-celled sarcoma.

H.

Hemeralopia (*hem-er-al-o'-pe-ah*) [*ήμέρα*, day; *ώψ*, eye]. Day-vision or night-blindness. (See note under *Nyctalopia*.)

Hemianopsia (*hem-e-an-op'-se-ah*) [*ήμι*, half; *άν*, priv.; *όψις*, sight]. Blindness in one-half of the visual field.

Herpes zoster (*her'-pez zos'-ter*) [*έρπης*, creeping; *ζωστήρ*, a girdle]. An inflammatory skin-disease, characterized by vesicles.

Heterochromia (*het-er-o-kro'-me-ah*) [*έτερος*, different; *χρώμα*, color]. A difference in color (in the irides).

Heteronymous (*het-er-on'-im-us*) [*έτερος*, different; *όνομα*, name]. Of a different name or character. Crossed. The opposite of homonymous.

Heterophoria (*het-er-o-fo'-re-ah*) [*έτερος*, different; *φορός*, tending]. A tending of the visual lines other than in parallelism.

Hippus (*hip'-us*) [*ίππος*, the horse]. Spasmodic pupillary movements, independent of the action of light.

Homonymous (*ho-mon'-im-us*) [*όμός*, same; *όνομα*, name]. Having the same relative position.

Hordeolum (*hor-de'-o-lum*) [*hordeum*, barley]. A sty.

Horopter (*hor-op'-ter*) [*όρος*, boundary; *όπτήρ*, an observer]. A line

representing the curve along which both eyes can join in sight.

Hyaline (*hi'-al-in*) [*ύαλος*, glass]. Resembling glass; referring to vitreous humor or a glass-like membrane.

Hyalitis (*hi-al-i'-tis*) [*ύαλος*, glass; *ιτις*, inflammation]. Inflammation of the hyaloid membrane and the vitreous humor.

Hydrophthalmos (*hi-droff-thi-mos*) [*ύδωρ*, water; *όφθαλμός*, eye]. Increase in the fluid contents of eye.

Hydrops (*hi'-drops*) [*ύδρωψ*, drops]. An abnormal collection of fluid any part of the body.

Hypermetropia (*hi-per-met-ro'-ah*) [*ύπερ*, over; *μέτρον*, measure; *ώψ*, eye]. See *Hyperopia*.

Hyperopia (*hi-per-o'-pe-ah*) [*ύπ*, over; *ώψ*, eye]. That condition of the refractive media of the eye in which, with suspended accommodation, the focus of parallel rays of light is behind the retina; is due to an abnormally short anterior diameter of the eye, or a subnormal refractive power of media.

Hyperphoria (*hi-per-fo'-re-ah*) [*ύπερ*, over; *φορός*, tending]. A tendency of a visual line upward.

Hyphemia (*hi-fe'-me-ah*) [*ύπ*, under; *αίμα*, blood]. A deposit of blood at the bottom of the anterior chamber.

Hypophoria (*hi-po-fo'-re-ah*) [*ύπ*, under; *φορός*, tending]. A tendency of a visual line downward.

Hypopyon (*hi-po'-pe-on*) [*ύπ*, under; *πύον*, pus]. A collection of pus in the anterior chamber.

I.

Iridectomy (*ir-id ek'-to-me*) [*ίρις*, iris; *έκτομή*, excision]. The cutting out of part of the iris.

Irideremia (*ir-id-er-el-me-ah*) [*ιρις*; *έρημία*, lack]. Absence of one or both irides.

Iridocyclitis (*ir-id-o-sik-li'-tis*) [*ιρις*, iris; *κύκλος*, a circle; *ιτις*, inflammation]. Inflammation of the iris and ciliary body.

Iridodialysis (*ir-id-o-di-al'-is-is*) [*ιρις*; *διαλύειν*, to liberate]. Separation of the iris from its ciliary border.

Iridodonesis (*ir-id-o-don-el-sis*) [*ιρις*; *δόνησις*, trembling]. Tremulousness of the iris.

Iridoplegia (*ir-id-o-ple'-je-ah*) [*ιρις*; *πληγή*, stroke]. Paralysis of sphincter of the iris.

Iridotomy (*ir-id-ot'-o-me*) [*ιρις*; *τομή*, a cutting]. Incision into the iris.

Iris (*i'-ris*) [*ιρις*, a colored halo or circle]. A colored circular membrane, placed between the cornea and lens, having the function of the diaphragm of a camera.

Iritis (*i-ri'-tis*) [*ιρις*; *ιτις*, inflammation]. Inflammation of the iris.

Ischemia (*is-ke'-me-ah*) [*ισχεειν*, to check; *αίμα*, blood]. Bloodlessness.

K.

Keratitis (*ker-at-i'-tis*) [*κέρας*, horn (= cornea); *ιτις*, inflammation]. Inflammation of the cornea.

Keratocoele (*ker'-at-o-sel*) [*κέρας*, cornea; *κήλη*, tumor]. A hernia of Descemet's membrane through the cornea.

Keratoglobus (*ker-at-o-glo'-bus*) [*κέρας*, cornea; *globus*, a ball]. Distention and protrusion of the cornea; when cone-shaped, and in the center of the cornea, it is called *conic cornea* or *keratoconus*.

Keratomalacia (*ker-at-o-mal-a'-se-ah*) [*κέρας*, cornea; *μαλακία*,

softness]. Softening of corneal tissue.

Keratotomy (*ker-at-as'-ko-pe*) [*κέρας*, cornea; *σκοπεειν*, to observe]. Examination of the cornea.

Kerectopia (*ker-ek-to'-pe-ah*) [*κόρη*, the pupil of the eye (so called, like the Latin *pupilla*, because an image appears in the eye); *εκτοπος*, misplaced]. Displacement of the pupil.

L.

Lacrimal (*lak'-rim-al*) [*lacrima*, a tear]. Having reference to the organs of secretion, transfer, or excretion of tears.

Lagophthalmos (*lag-off-thal'-mos*) [*λαγώς*, hare; *ὀφθαλμός*, eye]. Inability to close the eyes (from the popular belief that the hare sleeps with his eyes open).

Lens (*lens*) [Lat., a lentil]. A regularly shaped transparent object refracting luminous rays.

Leukemia (*lu-ke'-me-ah*) [*λευκός*, white; *αίμα*, blood]. A condition of the blood characterized by a relative increase in white corpuscles.

Leukoma (*lu-ko'-mah*) [*λευκωμα*, anything white]. A white spot on the cornea.

Luxatio (*luks-a'-she-oh*) [*λόξος*, slanting (Lat., *obliquus*)]. Dislocation.

M.

Macropsia (*mah-krop'-se-ah*) [*μακρός*, large; *ὄψις*, sight]. Apparent increase in the size of objects. *Megalopsia*.

Macula lutea (*mak'-u-lah lu-te'-ah*) [Lat.]. The yellow spot in the retina
usual axis.

Malacia (*m*)

- softening]. Morbid softening of tissue.
- Megalopsia** (*meg-al-op'-se-ah*) [*μέγας*, large; *ὄψις*, sight]. An apparent increase in the size of objects, ascribed to changes in the retinal end-organs and to spasm of accommodation. *Macropsia*.
- Metamorphopsia** (*met-am-or-fop'-se-ah*) [*μεταμορφόειν*, to change shape; *ὄψις*, sight]. Apparent change in the form of objects.
- Microphthalmos** (*mi-krof-thal'-mos*) [*μικρός*, small; *ὀφθαλμός*, eye]. An abnormally small eyeball.
- Micropsia** (*mi-krof'-se-ah*) [*μικρός*, small; *ὄψις*, sight]. Apparent decrease in the size of objects.
- Miosis** (*mi-o'-sis*) [*μειώσις*, a lessening]. An abnormal contraction of the pupil.
- Mydriasis** (*mid-ri'-as-is*) [*μυδρίασις*]. An abnormal dilatation of the pupil.
- Myodesopsia** (*mi-o-des-ops'-e-ah*) [*μυιοειδής*, like a fly; *ὄψις*, vision]. Subjective visual sensations as of *muscæ volitantes*.
- Myopia** (*mi-o'-pe-ah*) [*μύειν*, to close; *ὄψις*, eye]. Near-sightedness, because near-sighted people partially close the lids.
- Myotomy** (*mi-ot'-o-me*) [*μύς*, muscle; *τομή*, cutting]. Incision of a muscle.

N.

Nyctalopia (*nik-tal-o'-pe-ah*) [*νύξ*, night; *ὄψις*, the eye]. Night-vision or day-blindness. The condition in which the sight is better by night or in semidarkness than by daylight. It is a symptom of central scotoma, the more dilated pupil at night allowing a better illumination of the peripheral portions of the retina. Dr. Greenhill and Mr.

Tweedy have shown that, according to the quite universal usage of modern times, the definitions of the words *nyctalopia* and *hemeralopia* have been the reverse of that of the early Greek and Latin writers. The proper derivation, therefore, of *nyctalopia* would be from *νύξ*, night; *ἀλαός*, blind; *ὄψις*, eye, the word meaning night-blindness. *Hemeralopia* was likewise derived from *ἡμέρα*, day; *ἀλαός*, blind; *ὄψις*, eye, and meant day-blindness. The attempt to reinstate the ancient usage can only result in utter confusion, and it would be better to avoid the use of the words altogether. See *Hemeralopia*.

Nystagmus (*nis-tag'-mus*) [*νυσταγμός*, nodding of the head]. Oscillatory movement of the eyeballs.

O.

- Ophthalmometry** (*off-thal-mom'-et-re*) [*ὀφθαλμός*, eye; *μέτρον*, measure]. Mensuration of the eyeball or of the corneal curves.
- Ophthalmoplegia** (*off-thal-mo-pl'e-je-ah*) [*ὀφθαλμός*; *πληγή*, stroke]. Paralysis of the ocular muscles.
- Ophthalmoscope** (*off-thal'-mo-skōp*) [*ὀφθαλμός*; *σκοπεῖν*, to observe]. Instrument for examining the interior of the eye.
- Ophthalmotonometer** (*off-thal-mo-ton-om'-et-er*) [*ὀφθαλμός*; *τόνος*, tone; *μέτρον*, measure]. Instrument for measuring intraocular tension.
- Optogram** (*op'-to-gram*) [*ὄπτος*, visible; *γράφειν*, to write]. A faint image stamped on the retina for a brief period.
- Orthophoria** (*or-tho-fo'-re-ah*) [*ὀρθός*, straight; *φορός*, tending]. Tending of the visual lines to parallelism.

P.

Pannus (*pan'-us*) [Lat., cloth]. Vascularization of the cornea.

Panophthalmitis (*pan-off-thal-mit-tis*) [*πᾶς*, all; *ὀφθαλμός*, eye; *ιτις*, inflammation]. Inflammation of all the tissues of the eyeball.

Parallax (*par'-al-aks*) [*παρά*, beside; *ἄλλος*, other]. Apparent displacement of an object.

Paralysis (*par-al'-is-is*) [*παρά*, beside; *λύειν*, to loosen]. Loss of power of motion in a muscle.

Paresis (*par'-es-is*) [*παρά*, from; *ἵεναι*, to let go]. Partial loss of motion in a muscle.

Perimeter (*per-in'-et-er*) [*περί*, around; *μέτρον*, measure]. An instrument for measuring the extent of the field of vision.

Periscopic (*per-e-skop'-ik*) [*περί*, around; *σκοπεῖν*, to see]. Applied to lenses having a concave surface on one side and one convex on the other.

Peritomy (*per-it'-o-me*) [*περί*, around; *τομή*, a cutting]. The removal of a riband of conjunctival and subconjunctival tissue from about the cornea, for the relief of pannus.

Phakomalacia (*fa-ko-mal-a'-se-ah*) [*φακός*, lens; *μαλακία*, softness]. Soft cataract.

Phimosi (*fi-mo'-sis*) [*φίμοσιν*, to constrict]. Constriction; abnormal smallness (as of the palpebral fissure).

Phlyctenula (*flik-ten'-u-lah*) [dim. of *φλίκταινα*, blister]. A small vesicle or blister.

Photometer (*fo-tom'-et-er*) [*φῶς*, light; *μέτρον*, measure]. Instrument for measuring the intensity of light.

Photophobia (*fo-to-fo'-be-ah*) [*φῶς*, light; *φόβος*, fear]. Intolerance of light.

Pinguecula (*pin-guek'-u-lah*) [Lat.,

pinguis, fat]. A small tumor of the conjunctiva.

Presbyopia (*prez-be-o'-pe-ah*) [*πρεσβυς*, old; *ὤψ*, eye]. "Old-sight," due to failure in accommodation.

Pterygium (*ter-ij'-e-um*) [*πτέρυξ*, wing]. A triangular patch of thickened conjunctiva with its apex directed toward the cornea.

Ptosis (*to'-sis*) [*πτῶσις*, πίπτειν, to fall]. Drooping of the upper eyelid.

R.

Retina (*ret'-in-ah*) [*rete*, a net]. The inner nervous coat of the eyeball.

Retinitis (*ret-in-it-tis*) [*retina*, retina; *ιτις*, inflammation]. Inflammation of the retina.

Retinoscopy (*ret-in-ost'-ko-pe*) [*retina*, retina; *σκοπεῖν*, to observe]. The method of estimating the refraction of the eye by observation of the movements of the fundus-reflex; skiascopy; the shadow-test.

S.

Sarcoma (*sar-ko'-mah*) [*σάρξ*, flesh; *μα*, tumor]. A connective-tissue tumor.

Scintillans (*sin-till'-ans*) [*scintillare*, to sparkle]. Emitting sparks.

Sclera (*skle'-rah*) [*σκληρός*, hard]. The tough outer coat of the eyeball.

Sclerotomy (*skle-rot'-o-me*) [*σκληρός*, hard; *εκτομή*, to cut]. The operation of opening the eyeball by incising the sclera.

Scotoma (*sko-to'-mah*) [*σκοτέειν*, to darken]. A fixed spot in the field of vision, due to some abnormality in the retina or optic centers in the brain.

Seborrhea (*seb-or-e'-ah*) [*sebum*, suet; *ροία*, a flow]. An increase of sebaceous secretion.

Skiascopy (*ski-as'-ko-pe*) [*σκία*, shadow; *σκοπεῖν*, to observe]. The shadow-test. Retinoscopy.

Staphyloma (*staf-il-o'-mah*) [*σταφύλη*, grape; *δυμα*, tumor]. A grape-like protuberance of cornea or sclera.

Stenopeic (*sten-o-pe'-ik*) [*στενός*, narrow; *όπαιος*, pierced]. A disc with a narrow opening.

Strabismus (*strab-is'-mus*) [*στραβισμός*, squint] Squint.

Sursumduction (*sur'-sum-duk-shun*) [*sursum*, upon; *ducere*, to lead]. The power of the two eyes of fusing two images when one eye has a prism vertically before it.

Symblepharon (*sim-blef'-ar-on*) [*σύν*, together; *βλέφαρον*, the eyelid]. The abnormal adhesion of the eyelids to the eyeball in consequence of burns, wounds, etc.

Synchisis (*sin'-kis-is*) [*σύγχυσις*, a mixing together]. A confusing effect.

Synechia (*sin-e-ki'-ah* or *si-ne'-ke-ah*) [*σύν*, together; *ἔχειν*, to hold]. A morbid union of parts.

T.

Tarsorrhaphy (*tar-sor'-a-fe*) [*ταρσός*; *ράφή*, suture]. An operation upon the eyelids.

Tarsus (*tar'-sus*) [*ταρσός*, the tarsus (a flat surface)]. The cartilage of the eyelid.

Teichopsia (*ti-kop'-se-ah*) [*τείχος*, wall; *ὄψις*, vision]. Temporary amblyopia, with subjective visual images like fortification angles.

Telangiectasis (*tel-an-je-ek'-ta-sis*) [*τέλος*, end; *ἄγγειον*, vessel; *ἔκτασις*, stretching]. Dilatation of capillaries.

Tenotomy (*ten-ot'-o-me*) [*τένων*, tendon; *τέμνειν*, to cut]. Tendon-cutting.

Trachoma (*tra-ko'-mah*) [*τραχίς*, rough]. Granular conjunctivitis.

Trichiasis (*trik-i'-as-is*) [*θρίξ*, a hair]. Abnormal position of the eyelashes.

U.

Uremia (*u-re'-me-ah*) [*ούρον*, urine; *αἷμα*, blood]. Blood-poisoning from retained urinary excretions.

Uvea (*u'-ve-ah*) [Lat., a grape (from its color)]. The middle tunic of the eye.

V.

Vitreous (*vil'-re-us*) [*vitreus*; *vitrum*, glass]. Pertaining to the transparent, jelly-like humor filling the large posterior cavity of the eyeball. The vitreous humor.

X.

Xanthelasma (*xan-thel-az'-mah*) [*ξανθός*, yellow; *έλασμα*, a plate (lamina)]. Spots of yellowish discoloration.

Xanthoma (*xan-tho'-mah*) [*ξανθός*, yellow; *δυμα*, tumor]. A yellowish new growth on the skin.

Xerosis (*xe-ro'-sis*) [*ξηρός*, dry]. A dry condition.

INDEX.

A.

Abduction, measurement of, 116
Accommodation, 31; association of, with convergence, 33; mechanism of, 31; range of, 32
Actol, 274
Adduction, measurement of, 117
Advancement, 138
Airol, 268
Alum, 269
Alum-pencil, use of, 165
Amaurosis, 100
Amblyopia, 100; ex anopsia, 100; toxic, 101, 233; traumatic, 101
Ametropia, 30, 74
Anesin, 268
Angiomas, 153
Angle, apical, 22; refracting, 22
Aniridia, 206
Anisometropia, 95
Ankyloblepharon, 144
Antinosin, 268
Aphakia, 249
Arcus senilis, 191
Arecolin, 268
Argonin, 268
Argyll Robertson pupil, 37, 208
Arlt-Jaesche operation, 148
Artificial eye, 266
Asthenopia, 98
Astigmatism, 31, 84; cards for testing, 89; disadvantages of, 87; explanation of, 85; retinoscopy in, 56; symptoms of, 88; treatment of, 91; varieties of, 84
Atrophy of the optic nerve, 234
Atropin, 72, 268
Axonometer, 56

B.

Ballottement, ocular, 103
Bifocal lenses, 71
"Black eye," 141
Bleeding by leeches, 269
Blepharitis, 142
Blepharophimosis, 144
Blepharospasm, 152
"Blind spot," 108
Blood-vessels of the eyeball, 16
"Blue stone," 270
Boric acid, 269
Boroglycerid, 270

C.

Calomel, 270
Camphor-water, 270
Canaliculus, operations on the, 157
Canthoplasty, 145
Cardinal points of the eyeball, 27
Cassaripe, 270
Cataract, 236; causes of, 236; extraction of, 244; juvenile, 239; lamellar, 240; Morgagnian, 239; posterior polar, 240; pyramidal, 240; secondary, 247; senile, 239; stationary, 240; test for mature, 239; traumatic, 241; treatment of, 241; varieties and nomenclature, 237; zonular, 240
"Cat's eye," 227
Cautery, 270
Centering of lenses, 67
Centrad, 22
Chalazion, 143
Choked disc, 230

- Choroid, anatomy of, 212; coloboma of, 218; detachment of, 217; diseases of, 212; rupture of, 217; sarcoma of, 216; tuberculosis of, 216
- Choroiditis, 213; areolaris, 214; central, 215; disseminated, 214; exudative, 213; myopic, 215; syphilitic, 215
- Chromatopsia, 105
- Cilia, examination of, 35
- Ciliary body, anatomy of, 199; diseases of, 211; injection, diagnosis of, 36; muscle, 200; in hyperopia, 74; paralysis of, 212; spasm of, 212; processes, 201
- Cocain, 72, 270
- Collodion, 271
- Coloboma of the choroid, 218; of the eyelid, 152; of the iris, 206
- Color-blindness, 103
- Color-perception, 103
- Conic cornea, 192; retinoscopy in, 58
- Conjugate foci, 20
- Conjunctiva, anatomy of, 160; diseases of, 160; examination of, 33; foreign bodies in, 179; injuries of, 179; new growths of, 181
- Conjunctival injection, diagnosis of, 35
- Conjunctivitis, catarrhal, 166; croupous, 173; diphtheric, 173; follicular, 173; gonorrhoeal, 171; phlyctenular, 177; purulent, 167; simple, 164; tubercular, 176; vernal, 177
- Consensual reflex, 37
- Convergence, association with accommodation, 33
- Copper sulphate, 271
- Cornea, abscess of, 189; anatomy of, 181; diseases of, 181; examination of, 36; foreign bodies in, 193; herpes of, 186; injuries to, 193; opacities of, 191; operations upon, 195; serpiginous ulcer of, 190; staphyloma of, 192; tumors of, 194; ulcer of, 187
- Corrosive sublimate, 274
- Cover chimney, 51
- "Cover-test," 119
- Credé's method, 172
- Critchett's operation, 195
- Crossed diplopia, 115
- Croupous conjunctivitis, 173
- Cupping of the disc, 47
- Cyclitis, 211
- Cycloplegics, 72
- Cylinders, 25; neutralization of, 61

D.

- Dacryocystitis, 158
- Dacryolith, 157
- Dacryops, 155
- Daturin, 74
- Decentering lenses, 69
- Descemetitis, 185
- Diabetic amblyopia, 101
- Dianoux's operation, 148
- Dioptic system, 25
- Diphtheric conjunctivitis, 173
- Diplopia, 113, 114; crossed, 114; homonymous, 115
- Direct method, 39, 45
- Discission, 243
- Dissection of the eyeball, 17
- Distichiasis, 146
- Duboisin, 74, 271
- Duction-tests, 116

E.

- Ectropion, 150
- Eczema of the eyelids, 141
- Electric-light-blindness, 101
- Electrolysis, 147
- Electrotherapy, 271
- Embolism of the retinal vessels, 221
- Enophthalmos, 259
- Entoptic phenomena, 102
- Entropion, 146
- Enucleation, 265
- Ephedrin, 271
- Epicanthus, 152
- Epiphora, 155
- Episcleritis, 198
- Eserin, 271
- Esophoria, tests for, 119, 120
- Eucaïn, 272

- Euphthalmia, 272
 Evisceration, 264
 Exenteration of the orbital contents, 266
 Exophoria, tests for, 119
 Exophthalmic goiter, 259
 Exophthalmos, 145, 259
 Eye, anatomy of, 13; examination of, 33; general description of, 13; inspection of, 35
 Eyeball, anatomy of, 13; dissection of, 17; foreign bodies in, 261; humors of, 15; lymph-system of, 17; nerve-supply of, 15; operations on, 264; tunics of, 15; vascular supply of, 15; wounds of, 260
 Eye-drops, 166
 Eye-glasses, fitting of, 70
 Eyelids, anatomy of, 139; diseases of, 139; examination of, 35; new growths of, 153
 Eye-strain, 74
- F.**
- Far point, 32
 Field of vision, 106
 "Finger-exercise," 123
 Fitting of spectacles and eye glasses, 70
 Flarer's operation, 147
 Fluorescin, 37, 187, 272
 Focal illumination, 36; length, 19
 Formalin, 272
 Fundus, examination of, 46
 Fundus-reflex, 46
- G.**
- Glasses, prescription of, 65, 68; tint of, 71
 Glaucoma, 251; causes of, 251; diagnosis of, 253; pathologic changes, 251; prognosis of, 255; symptoms of, 252; treatment of, 255; varieties of, 254
 Glycerin, 272
 Gonorrheal ophthalmia, 167
- Græfe's operation, 149
 Granular lids, 174
- H.**
- Hamamelis, 272
 Heat and cold, 273
 Hemeralopia, 100
 Hemianopsia, 109
 Hering's theory, 104
 Herpes zoster ophthalmicus, 139
 Heterophoria, 114; tests for, 119
 Heterotropia, 126
 Hippus, 208
 Holmgren test, 105
 Holocain, 273
 Homatropin, 72, 273
 Homonymous diplopia, 115
 Hordeolum, 143
 Hotz's operation, 149
 Humors of the eyeball, 15
 Hyalitis, 249
 Hyaloid artery, persistent, 250
 Hydrogen dioxide, 273
 Hyoscyamin, 73, 273
 Hyperopia, 30, 74; axial shortening in, 74; causes of, 74; ciliary muscle in, 74; connection between convergent strabismus and, 76; diagnosis of, 76; disadvantages of, 75; prescription of glasses in, 77; retinoscopy in, 55; symptoms of, 75; treatment of, 77
 Hyperphoria, 120
 Hypopyon, 190
 Hysteric amblyopia, 102
- I.**
- Ichthalbin, 273
 Ichthyol, 273
 Illaqueation, 147
 Inch-system, 25
 Index of refraction, 21
 Indirect method, 41, 49
 Instruments, disinfection of, 278
 Insufficiency of adduction, 116; treatment of, 122
 Iodin, 274
 Iodoform, 274

Iridectomy, 208
 Iridodesis, 211
 Iridodialysis, 206
 Iridodonesis, 208
 Iridotomy, 210

Iris, anatomy of, 199; diseases of, 199; gumma of, 205; inflammations of, 201; injuries to, 206; operations on, 208; tubercles of, 205; tumors of, 205

Iris-shadow-test, 239
 Iritis, nodosa, 205; plastic, 201; serous, 204; suppurative, 204

Itrol, 274

J.

Jaeger's letters, 60
 Jequirity, 274

K.

Kalt suture, 245
 Keratectomy, 265
 Keratitis, bullous, 187; from lagophthalmos, 187; interstitial, 184; neuromparalytic, 186; phlyctenular, 185; punctate, 185; recurrent traumatic, 187
 Keratoconus, 192
 Keratoscope, 90
 Knapp's roller forceps, 176

L.

Lacrimal apparatus, anatomy of, 153; diseases of, 153; gland, diseases of, 155; sac, diseases of, 157; sounds, 159
 Lagophthalmos, 145
 Lapis divinus, 271
 Leeching, 269
 Lens, anatomy of, 235; coloboma of, 249; congenital dislocation of, 249; diseases of, 235; injuries to, 248; removal of, in high myopia, 78
 Lenses, 23; bifocal, 71; classification and numbering of, 25; decentrating of, 64; different forms of,

24; neutralization of, 67; prescribing, 65, 70; refraction by, 23; testing of, 67; tinted, 71; varieties used to correct ametropia, 25

Leukoma, 191

Ligamentum pectinatum, incision of, 256

Light-sense, estimation of, 61

Lunar caustic, 277

Lymph-system of the eyeball, 16

M.

Macula, examination of, 48

Maddox rod, 119

Malarial amblyopia, 101

Malingering, 102

Massage of the eyeball in glaucoma, 276

Media, examination of, 46

Megalopsia, 103

Meibomian glands, 139

Mercuric chlorid, 274; oxid, 275

Metamorphopsia, 103

Micropsia, 103

Miosis, 207

Mirrors, action of, on light, 18

"Moon-blindness," 101

Morphia, 275

Mules' operation, 264

Muscæ volitantes, 101, 250

Muscles, ocular, 111; anatomy and physiology of, 111; functional anomalies of, 112; nervous supply of, 112; normal balance of, 112; operations on, 136; paralysis of, 128; strength of, 117

Mydriasis, 207

Mydriatics, 72

Myiodesopsia, 250

Myopia, 29, 78; axial lengthening in, 78; causes of, 79; diagnosis of, 87; disadvantage and danger of, 79; divergent squint in, 80; prescription of glasses in, 83; progressive or malignant, 80; removal of the lens in, 84; retinoscopy in, 55; symptoms of, 81; treatment of, 82
 Myopic crescent, 80, 215

N.

Near point, 32
 Nebula, 191
 Nerves of the eyeball, 15
 Neuritis, optic, 230; retrobulbar, 233
 Neuroretinitis, 230
 Nictitation, 152
 Night-blindness, 100
 Nodal points, 28
 Nosophen, 275
 Nyctalopia, 101
 Nystagmus, 131

O.

Oblique illumination, 36; muscles, 112
 Ocular ballottement, 102
 Onyx, 189
 Opacities, corneal, 191
 Opaque nerve-fibers, 228
 Operations, practising, 17
 Ophthalmia, gonorrhœal, 167; neotatorum, 171; sympathetic, 262
 Ophthalmometer, 91
 Ophthalmoplegia, 129
 Ophthalmoscope, 39; description of, 42; direct method with, 39, 45; indirect method with, 41, 49; refraction by, 48; theory of, 39; use of, 45
 Ophthalmotonometer, 38
 Opium, 275
 Optic disc, 46; nerve, anatomy of, 228; atrophy of, 234; diseases of, 228; inflammation of, 230
 Optical consideration of the eye, 27
 Optics, 18
 Orbit, anatomy of, 256; diseases of, 256; injuries to, 258; tumors of, 259
 Orbital cellulitis, 258; periostitis, 257

P.

Pagenstecher ointment, 275
 Panas' solution, 275
 Pannus, 183

Papillitis, 230
 Papilloretinitis, 230
 Paracentesis corneæ, 195
 Parallax displacement, 46
 Parallax test, 47
 Paralysis of the ocular muscles, 128
 Parasites in the eyeball, 262
 Perimeter, 106
 Periostitis, orbital, 257
 Persistent hyaloid artery, 250; pupillary membrane, 207
 Petit's canal, 17
 Phacometer, 68
 Phorometer, 118
 Photometer, 61
 Picric acid, 275
 Pilocarpin, 275
 Pinguecula, 178
 Placido's disc, 91
 Points, cardinal, 27; far, 32; near, 32; nodal, 28; principal, 28
 Polycoria, 206
 Porus opticus, 13
 Potassium permanganate, 275
 Presbyopia, 93
 Prescription of lenses, 65, 70; in hyperopia, 77; in myopia, 83
 Principal axis, 24; focus, 18, 28; points, 28
 "Prism-battery," 117
 Prism-diopter, 23
 Prism-exercise, 123
 Prisms, 21; prescription of, 68; neutralization of, 69; refraction by, 21; rotary variable, 117; strength of, 22
 Protargol, 275
 Pterygium, 178
 Ptosis, 150
 Puncta lacrimalis, affections of, 156
 Punctum proximum, 32; remotum, 32
 Pupil, Argyll-Robertson, 37, 208; changes in the motility of, 207; examination of, 37; reflexes of, 37
 Pyoktanin, 276

Q.

Quinin amblyopia, 101

R.

- Recti muscles, 112
 Reflection, 18; by a concave surface, 19; by a convex surface, 20; by a plane surface, 18
 Refraction, 20; by cylinders, 24; by lenses, 23; by ophthalmoscopy, 48; by a plane surface, 20; by prisms, 22; by retinoscopy, 54; by a spheric surface, 22; index of, 21
 Retina, anatomy of, 218; detachment of, 225; diseases of, 218; glioma of, 227; hemorrhage of, 220; hyperemia of, 219; injuries to, 228
 Retinitis, 221; albuminuric, 221; diabetic, 223; leukemic, 223; pigmentosa, 223; syphilitic, 223
 Retinoscope, 50
 Retinoscopy, 49; diagnosis by, 54; principle of, 50, 53; technic of, 50
 Retrobulbar neuritis, 233

S.

- Saemisch's operation, 195
 Sanoform, 276
 Sassafras, 276
 Schlemm's canal, 17
 Scissors movement, 58
 Sclera, anatomy of, 196; diseases of, 196; staphyloma of, 197; wounds of, 198
 Scleritis, 196
 Sclerochoroiditis, 215
 Sclerotomy, 255
 Scopolamin, 72, 276
 Scotomata, 109
 "Second sight," 79
 Shadow-test, 49
 Silver nitrate, 276
 Skiascopy, 49
 Snellen's letters, 59; sutures, 150
 Snow-blindness, 101
 Spectacles, fitting of, 70; preferable to eye-glasses, 70
Spheric surface, refraction by, 23
Spring catarrh, 177
Squint, 126

- Staphyloma of the cornea, 192; posterior, 80; of the sclera, 197
 Strabismus, 126; in hyperopia, 76; in myopia, 80
 Streatfield's operation, 149
 Styte, 143
 Sun-blindness, 101
 Suprarenal extract, 277
 Symblepharon, 180
 Sympathetic ophthalmia, 262
 Synchysis, 250; scintillans, 250
 Synechias, 38, 202

T.

- Table of differential diagnosis of ocular inflammations, 162; of paralyses of the ocular muscles, 132
 Tannic acid, 277
 Tarsorrhaphy, 145
 Tattooing the cornea, 191
 Tenon, capsule of, 13
 Tenotomy, 136
 Tension, measurement of, 38
 Test-cards, 59
 Testing of lenses, 67
 Test-lenses, 62
 Thiosinamin, 277
 Thomson stick, 105
 Thrombosis of the retinal vessels, 225
 Tinted glasses, 71
 Tobacco amblyopia, 101, 233
 Toluidin blue, 277
 Toxic amblyopia, 101, 233
 Trachoma, 174
 Traumatic amblyopia, 101
 Trial-frames, 62
 Trichiasis, 146
 Tunics of the eyeball, 15

U.

- Ulcus rodens, 190; serpens, 190

V.

- Van Millingen's operation, 149
 Virtual focus, 19
 Vitreous, diseases of, 249

W.

Wernicke's sign, 208
Witch hazel, 272

X.

Xanthomas, 153
Xeroform, 277

Y.

Yellow oxid, 275
Young-Helmholtz theory, 104

Z.

Zinc acetate, 277; chlorid, 278;
sulphate, 277



A Companion Volume to Gould's Pocket Dictionary

A POCKET CYCLOPEDIA OF MEDICINE *and* SURGERY

EDITED BY

GEORGE M. GOULD, A.M., M.D.

Author of "Gould's Medical Dictionaries," Editor of "American Medicine"

AND

WALTER L. PYLE, A.M., M.D.

Assistant Surgeon Wills Eye Hospital, Philadelphia; formerly Editor
"International Medical Magazine," etc.

BEING BASED UPON GOULD AND PYLE'S LARGE "CYCLOPEDIA OF
PRACTICAL MEDICINE AND SURGERY"

Uniform with Gould's Pocket Dictionary. 64mo. Flexible Leather,
Gilt Edges, Round Corners, net \$1.00; with Thumb Index, \$1.25



HIS book bears to Gould and Pyle's large "Cyclopedia of Medicine and Surgery" a relation similar to that which the Pocket Dictionary bears to Gould's complete "Illustrated Dictionary." As the Dictionary gives the derivation, pronunciation, and definition of medical **words**, the Cyclopedia is designed to furnish general information concerning medical **subjects**. Every subject, concerning which the student may desire a brief and thorough description, supplementing the mention which may be given in lectures or a general text-book, is taken up and treated thoroughly and concisely. To those desiring concise authoritative information on medical or surgical themes or who wish to look up any new term or matter of recent discovery and use, the book will prove invaluable. It includes articles on Emergencies, Hygiene, Poisons, Nursing, etc.; describes Drugs and their Uses; gives Treatment of Diseases; explains Surgical Operations; contains many Prescriptions and Formulæ, Tables of Differential Diagnosis, Dose Table in both English and Metric Systems, etc.

P. BLAKISTON'S SON & CO., Publishers and Booksellers
1012 WALNUT STREET, PHILADELPHIA

FOR MEDICAL STUDENTS.

LANE MEDICAL LIBRARY

To avoid fine, this book should be returned on or before the date last stamped below.

TI

OI

EI

CC

MI

HI

HC

May 7, 18

ctioners
 berdeen);
 American
 Chirurgie,
 7 Engraver-
 ers, \$3.00
PATH-
ians. By
 iversity of
 Edition.
 ers, \$2.50
 Diagnosis,
 By T. E.
 ogy, and
 L. 12mo.
 th, \$2.00
Edition.
 ical Mid-
 ork City;
 tc. With
 urces and
 er, \$7.00
 . Includ-
 of Patho-
 Pathology
 Edition,
 original,
 net, \$4.00
VECOL-
 t.D., Pro-
 a; Gynec-
 strations,
 et, \$5.00.
ICINE.
 horoughly
 WN, M.D.,
 natologist,
 ers, \$2.50
Edition.
 strator of
 city. 153
 net, \$1.50
 160 Illustrations.
 Oil Cloth, net, \$1.50

VOL. II. Abdomen, Perineum, Lower Extremity, Brain, Eye, Ear,
 Mammary Gland, Scrotum, Testes. 160 Illustrations.
 400 pages. Oil Cloth, net, \$1.50

P. BLAKISTON'S SON & CO., Publishers and Booksellers.
 1012 WALNUT STREET. PHILADELPHIA.

BRUBAKER. A TEXT-BOOK OF HUMAN PHYSIOLOGY.
 By ALBERT P. BRUBAKER, A.M., M.D., Professor of Physiology and
 Hygiene, Jefferson Medical College; Professor of Physiology, Penna.
 College of Dental Surgery, Philadelphia, etc. With Colored Plates and
 354 Illustrations. Price, \$4.00

HANSELL A
 Treatise on
 Surgery. I
 Ophthalmol
 Eye, Phila
 Ophthalmic
 SWEET, M.
 Assistant A
 College H
 Ophthalm

Q49 Gould, G.M. 38383
 G69 A compend of the dis-
 1904 cases of the eye. 3d ed

NAME DATE DUE

P. W. Somack *May 7, 18*

KNIGHT.
 Students.
 Cornell U
 Manhatt

WILLIAM
 WILLIA
 partner
 With a

TYSON.
 Editio
 and N
 vised.

TYSON.
 Editi
 tions.

BLAKIS
 Thro
 Foot

SWAN
 and
 bo
 F. R
 mic
 and

BYFO
 M.
 of
 E

BART

Book of
BARTLEY, M.D., Professor of
 the Long Island College Hospit
 of Brooklyn, N. Y., etc. B
 Glossary, and Complete In

P. BLAKISTON'S S
 1012 W

